

Available online at www.sciencedirect.com

ScienceDirect

journal homepage: <http://www.elsevier.com/locate/medici>

Case report

Early prediction of response to cetuximab and radiotherapy by FDG-PET/CT for the treatment of a locoregionally advanced squamous cell carcinoma of the hypopharynx

Mindaugas Grybauskas^{a,*}, Jean-François Daisne^b, Eduardas Aleknavičius^{c,d}, Arvydas Burneckis^a

^aDepartment of Radiation Oncology, National Cancer Institute, Vilnius, Lithuania

^bDepartment of Radiation Oncology, Clinique et Maternité Sainte-Elisabeth, Namur, Belgium

^cRadiotherapy and Drug Therapy Centre, National Cancer Institute, Vilnius, Lithuania

^dFaculty of Medicine, Vilnius University, Vilnius, Lithuania

ARTICLE INFO

Article history:

Received 16 May 2014

Accepted 15 September 2014

Available online 29 September 2014

Keywords:

Cetuximab

Head and neck cancer

Predictive marker

FDG-PET/CT

Radiotherapy

ABSTRACT

Cetuximab (CTX) is used for the concurrent treatment with radiotherapy (RT) in squamous cell carcinoma of head and neck (HNSCC). There are no reliable clinical predictive markers of effectiveness of CTX at yet. We describe the clinical case of patient who received a CTX/RT to cure locoregionally advanced hypopharyngeal SCC. 2-Deoxy-2-[¹⁸F]fluoro-D-glucose positron emission tomography and computed tomography (¹⁸FDG-PET/CT) was performed before the treatment and repeated 10 days after CTX induction dose. A repeated ¹⁸FDG-PET/CT scan showed dramatic decrease of metabolic parameters. Patient had a complete response after treatment and is still alive and cured after 5 years.

© 2014 Lithuanian University of Health Sciences. Production and hosting by Elsevier Urban & Partner Sp. z o.o. All rights reserved.

1. Introduction

Head-and-neck cancer refers to a group of the malignant tumors arising at a variety of sites in the upper aerodigestive tract, the most commonly in the oral cavity, the oropharynx, the

hypopharynx and the larynx. The squamous cell carcinoma (SCC) is the predominant histological type (about 90%) and the sixth leading neoplasm by incidence worldwide with more than 650,000 new cases diagnosed per year [1]. At the time of diagnosis most patients have the locally advanced disease and lymph node metastases [2]. Despite advances in therapy during past decade,

* Corresponding author at: Department of Radiation Oncology, National Cancer Institute, Santariškių 1, 08660 Vilnius, Lithuania.

E-mail address: mindaugas7415@gmail.com (M. Grybauskas).

Peer review under the responsibility of the Lithuanian University of Health Sciences.



Production and hosting by Elsevier

<http://dx.doi.org/10.1016/j.medici.2014.09.003>

1010-660X/© 2014 Lithuanian University of Health Sciences. Production and hosting by Elsevier Urban & Partner Sp. z o.o. All rights reserved.

prognosis and long-term survival of patients with locoregionally advanced head and neck squamous cell carcinoma (LAHNSCC) are poor.

Combined chemoradiotherapy, including monoclonal antibodies, represents state-of-the-art treatment for LAHNSCC. Cetuximab (CTX) is a monoclonal antibody targeted to epidermal growth factor receptor (EGFR). It has been approved for use in combination with radiation during treatment of primary locoregionally advanced (stage III to IVB) HNSCC or as monotherapy for the treatment of recurrent or metastatic HNSCC after the failure of platinum-based chemotherapy, and also in combination with platinum/5-fluorouracil for the treatment of the recurrent or metastatic disease. Treatment with this anti-EGFR antibody is expensive and absolute difference in median overall survival at 3 years in LAHNSCC patients is 19.7 months (29.3 months in RT only group vs. 49 months in RT/CTX group). This corresponds to 10% absolute benefit in median overall survival in the RT/CTX group [3]. The majority of patients with LAHNSCC do not take advantage either because they have been cured by RT alone or are unresponsive on the long term. Hence, it is desirable to early predict the efficacy of the treatment with CTX/RT to better select good responders.

2. Case report

A 66-year-old man with dysphagia, pain in the left jaw and ear, and hoarseness lasting since January 2009 was admitted to the out-patient clinic in March 2009. Ulcero-proliferative lesion in the left pyriform sinus, aryepiglottic folds, left arytenoid and cricoid region with immobility of the left vocal cord was diagnosed by fiberoptic endoscopic examination. Histological examination of the lesion biopsy showed the poorly differentiated SCC. One enlarged lymph node was detected in the level

II on the left side of the neck during clinical examination. No distant metastasis was detected.

A hypopharyngeal SCC of the left side was diagnosed, clinically cT3N1M0, stage IVa according to the Union for International Cancer Control (UICC) 6th edition. Concomitant chemoradiotherapy was foreseen for the treatment, but hepatitis C with the advanced cirrhosis was diagnosed before the commencement of RT. Therefore, treatment with CTX was proposed instead of platinum-based chemotherapy.

The first ^{18}F FDG-PET/CT was carried out on April 23, 2009. Standard induction dose of CTX (400 mg/m²) was administered on April 27, 2009, and was followed by radiosensitizing doses on a weekly basis.

RT treatment planning was performed using standard contrast-enhanced CT and ^{18}F FDG-PET/CT data. Then RT was administered between May 4, 2009, and June 15, 2009, inclusive. Accelerated fractionation (2 Gy/fx, 6 fx/week) was used. A therapeutic dose of 70 Gy was prescribed to the hypopharyngeal tumor and the lymph node in the level II on the left side of the neck. A prophylactic dose of 50 Gy was prescribed to the lymph nodes in the level III and IV on the left side of the neck and the level II to IV on the right side of the neck.

The second infusion of CTX was administered on May 4, 2009, and intensity modulated radiotherapy (IMRT) was used for delivery of highly conformal RT. ^{18}F FDG-PET/CT was repeated on May 7, 2009, following RT of a cumulative dose of 6 Gy.

The first ^{18}F FDG-PET/CT revealed pathological ^{18}F FDG uptake in the left side of hypopharynx and in one lymph node in level II on the left side of the neck. The second ^{18}F FDG-PET/CT on May 7, 2009, showed significant decrease in ^{18}F FDG uptake in the tumor and the metastatic lymph node (Fig. 1). The main parameters of both ^{18}F FDG-PET/CT scans are summarized in Table 1.

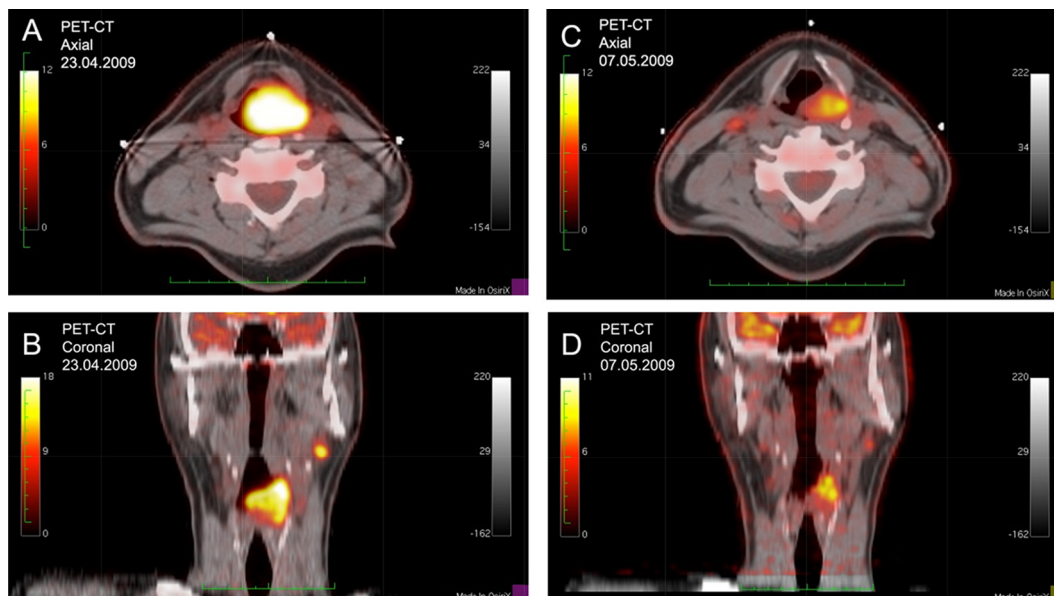


Fig. 1 – ^{18}F FDG uptake before (A and B) and after (C and D) administration of 2 doses of CTX. The first ^{18}F FDG-PET/CT (axial (A) and coronal (B)) revealed pathological ^{18}F FDG uptake in the left side of hypopharynx and one lymph node in level II on the left side of the neck. The second ^{18}F FDG-PET/CT (axial (C) and coronal (D)) on 07.05.2009 showed significant decrease in ^{18}F FDG uptake in the tumor and the metastatic lymph node. SUV threshold value of 2.5 was used for image acquisition.

Table 1 – Parameters of ¹⁸FDG-PET scans before and after administration of 2 doses of CTX (SUV threshold value of 2.5).

Parameter	Before CTX (23.04.2009)	After 2 doses of CTX (07.05.2009)	Reduction (%)
SUVmax ^a	23.97	6.77	71.7
SUVmean ^a (SUVbw)	7.429	3.705	50.2
MTV ^a	26.54	5.67	78.6
TLG ^a	197.2	21.01	89.3

^a SUVmax, maximum standardized uptake value; SUVmean, mean standardized uptake value; MTV, metabolic tumor volume; TLG, total lesion glycolysis.

Specific toxicity of CTX was observed as the grade III maculopapular skin rash and required the topical application of metronidazole cream and oral intake of doxycycline 100 mg 2 times a day.

A complete response to the treatment was determined by ¹⁸FDG-PET/CT scan 3 months later past RT on September 17, 2009. Further monitoring confirmed the complete remission. After nearly five years, the patient remains free of disease progression.

3. Discussion

¹⁸FDG-PET is a molecular imaging technique that exploits preferential utilization of aerobic glycolysis by tumor cells. ¹⁸FDG-PET has been used in cancer patients since the 1980s and is now a widely used clinical imaging tool in oncology. Significant reduction in ¹⁸FDG uptake identified by PET can indicate modulation of EGFR function or other mechanisms involved in the regulation of glucose metabolism in cancer cells. Preclinical studies using breast cancer cell lines showed marked inhibition of glucose uptake and retention over a period of hours following treatment with the anti-EGFR antibody cetuximab [4].

Aerobic glycolysis is a defining feature of cancer and is characterized by increased metabolism of glucose to lactate in the presence of sufficient oxygen [5]. The rate of adenosine triphosphate (ATP) generation becomes greater if respiration occurs through glycolysis. This enables cancer cells to gain competitive advantage for shared energy resources such as glucose etc. Tumors that take up more glucose than surrounding tissues can be noninvasively visualized in cancer patients by ¹⁸FDG-PET.

Hypoxia is another key feature of many types of tumors [6]. Hypoxic cells often use enhanced glycolysis to maintain production of energy. ¹⁸FDG uptake might indicate a state of hypoxia [7], because it is related to a higher expression of glucose transporter GLUT-4 in hypoxic cells [8], which is responsible for the internalization and entrapment of ¹⁸FDG into the cell. However, ¹⁸FDG uptake should not be considered as a surrogate marker for hypoxia [9].

Su et al. demonstrated that reduction of hypoxia by CTX was observed only in tumor cells highly sensitive to this treatment [10].

Most of adaptations to tumor hypoxia – including the shifting of metabolism toward glycolysis – are commonly orchestrated by the hypoxia inducible factors (HIFs) [11]. Li et al. observed that CTX decreases the HIF-1 α level and concluded that downregulation of HIF-1 α is required to maximize therapeutic response of cancer cells to CTX [12].

Lu et al. demonstrated that, following EGFR-targeted therapy, HIF-1 selectively decreased in responsive cell lines only [13].

Sequential imaging during treatment by means of ¹⁸FDG-PET reveals glucose uptake patterns that might aid predicting treatment effectiveness [14]. But there is still no clinical data that shows possible predictive value for early evaluation of tumor response to CTX by means of PET-CT. Regarding the predictive value of ¹⁸FDG-PET in early prediction of clinical response to anti-EGFR therapy there is one study with panitumumab. A chemotherapy-refractory patient necessitated a quick identification of an effective agent. The authors used the ¹⁸FDG-PET scan 48 h after the initial dose of panitumumab to determine pharmacodynamic response to the antibody. In this case report, the initial 46% reduction of SUVmax for target lesions correlated well with partial response past 8 weeks [15]. By analogy, we observed in the present case a 71.7% reduction of SUVmax on ¹⁸FDG-PET scan 10 days after CTX loading dose.

4. Conclusions

Prediction of tumor response to the treatment is burning topic in oncology. Despite the initial optimism, it should be noted that results of clinical trials show the limited effectiveness of targeted therapy. Treatment with CTX is very expensive. In order to reduce health costs, it would be appropriate to administer treatment to the patients with HNSCC, which may benefit from this treatment and early predict the likely effectiveness of the therapy. Experimental studies show that there are specific metabolic changes in tumors, in particular the phenomenon of glycolysis, which is associated with hypoxia in tumors and could be controlled through the stimulation of EGFR-dependent and independent mechanisms. Perhaps the most important changes in the metabolism of tumor cells are regulated by HIF-1 α . Studies have shown that down-regulation of HIF-1 α is necessary to ensure the effectiveness of CTX and is associated with decreased glycolysis and tumor hypoxia. Studies have shown that hypoxia decreases in tumor cell lines that are very sensitive to CTX. Since glycolysis mechanism is closely related to HIF-1 α and could be evaluated by changes in TLG measured by ¹⁸FDG-PET, we assume that ¹⁸FDG-PET examination could be used as a measure to early predict the efficiency of CTX.

In this article we present our experience in evaluating response of LAHNSCC to the treatment with CTX. Response to the treatment was assessed by repeated examination with ¹⁸FDG-PET/CT. The reported clinical case indicates that SCC of hypopharynx was very sensitive to CTX and this was reflected by sharp decrease of ¹⁸FDG-PET parameters during the first

days of treatment. This case of SCC treated with CTX and the similar clinical case with panitumumab described by Krystal GW et al. could indicate that early repeated ^{18}F -FDG-PET examination could predict the efficacy of CTX and, hence, lead to early selection of good responders.

Conflict of interest

The authors state no conflict of interest.

Acknowledgments

This article was encouraged by Dr. Jean-François Daisne during the internship “Application of biological therapy for the treatment of head and neck cancer” in the Clinique et Maternité Sainte-Elisabeth (Namur, Belgium). The Internship was conducted and financed by the European Social Fund through the implementation of the project “Improvement of qualifications of health care specialists contributing to reduced morbidity and mortality from oncological diseases in the Institute of Oncology, Vilnius University,” under the instrument “Improvement of qualifications of health care specialists contributing to reduced morbidity and mortality from main non-infectious diseases on the basis of first priority – quality employment and social inclusion – in the Action Programme for Development of Human Resources.”

REFERENCES

- [1] The Globocan Project [website on the Internet]. Geneva: World Health Organization; 2010, Available from: <http://globocan.iarc.fr/> [accessed 15.03.14].
- [2] Jemal A, Siegel R, Ward E, Murray T, Xu J, Thun MJ. Cancer statistics. *CA Cancer J Clin* 2007;57:43–66.
- [3] Bonner JA, Harari PM, Giralt J, Cohen RB, Jones CU, Sur RK, et al. Radiotherapy plus cetuximab for locoregionally advanced head and neck cancer: 5-year survival data from a phase 3 randomised trial, and relation between cetuximab-induced rash and survival. *Lancet Oncol* 2010;11:21–8.
- [4] Smith TA, Cheyne RW. Predicting tumour response to anti-HER1 therapy using medical imaging: a literature review and in vitro study of ^{18}F -FDG incorporation by breast cancer cells responding to cetuximab. *Br J Biomed Sci* 2011;68:158–66.
- [5] Warburg O, Posener K, Negelein E. Über den stoffwechsel der carcinomzelle. *Biochem Z* 1924;152:309–44.
- [6] Rajendran JG, Mankoff DA, O’Sullivan F, Peterson LM, Schwartz DL, Conrad EU, et al. Hypoxia and glucose metabolism in malignant tumors: evaluation by ^{18}F fluoromisonidazole and ^{18}F fluorodeoxyglucose positron emission tomography imaging. *Clin Cancer Res* 2004;10:2245–52.
- [7] Pauwels EK, Ribeiro MJ, Stoot JH, McCready VR, Bourguignon M, Mazzière B. FDG accumulation and tumor biology. *Nucl Med Biol* 1998;25:317–22.
- [8] Wang GL, Jiang BH, Rue EA, Semenza GL. Hypoxia-inducible factor 1 is a basic-helix-loop-helix-PAS heterodimer regulated by cellular O_2 tension. *Proc Natl Acad Sci U S A* 1995;92:5510–4.
- [9] Dehdashti F, Grigsby PW, Mintun MA, Lewis JS, Siegel BA, Welch MJ. Assessing tumor hypoxia in cervical cancer by positron emission tomography with $(60)\text{Cu}$ -ATSM: relationship to therapeutic response – a preliminary report. *Int J Radiat Oncol Biol Phys* 2003;55:1233–8.
- [10] Stegeman H, Kaanders JH, van der Kogel AJ, Iida M, Wheeler DL, Span PN, et al. Predictive value of hypoxia, proliferation and tyrosine kinase receptors for EGFR-inhibition and radiotherapy sensitivity in head and neck cancer models. *Radiother Oncol* 2013;106(3):383–9.
- [11] Harris AL. Hypoxia – a key regulatory factor in tumour growth. *Nat Rev Cancer* 2002;2:38–47.
- [12] Li X, Lu Y, Liang K, Pan T, Mendelsohn J, Fan Z. Requirement of hypoxia-inducible factor-1A downregulation in mediating the antitumor activity of the anti-epidermal growth factor receptor monoclonal antibody cetuximab. *Mol Cancer Ther* 2008;7(5):1207–17.
- [13] Lu Y, Liang K, Li X, Fan Z. Responses of cancer cells with wild-type or tyrosine kinase domain-mutated epidermal growth factor receptor (EGFR) to EGFR-targeted therapy are linked to downregulation of hypoxia-inducible factor-1 α . *Mol Cancer* 2007;6:63.
- [14] Hentschel M, Appold S, Schreiber A, Abolmaali N, Abramyuk A, Dörr W, et al. Early FDG PET at 10 or 20 Gy under chemoradiotherapy is prognostic for locoregional control and overall survival in patients with head and neck cancer. *Eur J Nucl Med Mol Imaging* 2011;38(7):1203–11.
- [15] Krystal GW, Alesi E, Tatum JL. Early FDG/PET scanning as a pharmacodynamic marker of anti-EGFR antibody activity in colorectal cancer. *Mol Cancer Ther* 2012;11(7):1385–8.