

An Unusual Case of a Sore Throat and Otagia in a 4-Year-Old Boy

Nora Šiupšinskienė^{1,2}, Evaldas Padervinskis¹, Lina Poškienė³,
Nganjo Endeley⁴, Saulius Vaitkus¹

¹Department of Otorhinolaryngology, Medical Academy, Lithuanian University of Health Sciences, ²Faculty of Health Sciences, University of Klaipėda, ³Department of Pathologic Anatomy, Medical Academy, Lithuanian University of Health Sciences, ⁴Faculty of Medicine, Medical Academy, Lithuanian University of Health Sciences, Lithuania

Key words: sore throat; otagia; Burkitt's lymphoma; tonsil.

Summary. A sore throat, otagia, and snoring are the common symptoms seen in children presenting to an otorhinolaryngological clinic. Sometimes, however, these symptoms may be suggestive of an aggressive malignancy. We present a rare case of Burkitt's lymphoma of the tonsil in a young child, which initially manifested as a sore throat and otagia.

Introduction

Burkitt's lymphoma is a rare form of high-grade non-Hodgkin's lymphoma of B-cell origin (1). According to the epidemiological project of the prevalence of lymphomas in Lithuania, the incidence of Burkitt's lymphoma was found to be 0.54% of all non-Hodgkin's lymphomas diagnosed during 2004–2006 (2). It is a highly aggressive disease requiring a prompt diagnosis and the initiation of treatment that could be crucial for patient survival. There are 3 recognized forms of Burkitt's lymphoma: endemic (African), sporadic (non-African), and immunodeficiency-associated (3). Sporadic Burkitt's lymphoma that is found in the United States and Europe usually affects children at the age of 12 years and adults (2–4). This form of the disease presents mainly in the abdomen, medulla, or lymphatic nodules and rarely involves the head and neck region (1–5). Extranodal manifestation of the disease in the head and neck region includes the Waldeyer's ring (nasopharynx, tonsil, and base of tongue), paranasal sinuses, jaw, thyroid, and parapharyngeal space (4–6). Only 5% of cases of sporadic Burkitt's lymphoma involve the first Waldeyer's ring (7). Dysphagia and cervical lymphadenopathy are the most common symptoms of tonsillar lymphoma that present in more than 60% of patients (6). We present a case of a 4-year-old boy with initial innocuous symptoms later leading to the diagnosis of sporadic Burkitt's lymphoma of the tonsil.

Case Report

A 4-year-old boy was admitted to the Clinic of Otorhinolaryngology with a 2-week history of a sore throat and otagia progressing to snoring and breath-

ing difficulties. A right tonsillar mass was also noticed for a week by his parents. The patient was treated by his family doctor for a common cold, but was referred to an otolaryngologist due to a rapid progress of the symptoms and the suspicion of a paratonsillar abscess despite the absence of fever. On physical examination, the right tonsil was deviated to the midline, while there were no abnormal findings in the left tonsil, and oropharyngeal and hypopharyngeal regions. No signs of cervical lymphadenopathy were seen. An urgent computed tomography (CT) scan revealed a large 4.1×3.6-cm mass arising from the right tonsil, deforming the nasopharynx and extending to the epiglottis (Fig. 1). The patient underwent biopsies of the right tonsil and the paratonsillar space under general anesthesia, which revealed an infiltration of medium-sized lymphoid cells that had moderate amounts of pyroninophilic cytoplasm, round nuclei, high mitotic rate, and numerous reactive macrophages forming a "starry sky" pattern typical of Burkitt's lymphoma (Fig. 2). Immunohistochemistry showed a disease-specific cell expression of surface immunoglobulins CD20 and CD10. The extent of the disease and tumor staging according to the Murphy/St. Jude's staging system were assessed based on the findings of lumbar puncture, bone marrow biopsy, abdominal ultrasound, liver function tests, and chest x-ray. All staging workups did not reveal any disease spread, and the final diagnosis of stage II tonsil lymphoma was confirmed. The patient was given 4 cycles of polychemotherapy with cyclophosphamide, vincristine, doxorubicin, and dexamethasone with the addition of both intravenous and intrathecal methotrexate and cytarabine. Repeated clinical examination and a CT scan after 2 months following the treatment showed no evidence of tumor recurrence. After 3 years, the child was disease-free.

Correspondence to N. Šiupšinskienė, Department of Otorhinolaryngology, Medical Academy, Lithuanian University of Health Sciences, Eivenių 2, 50028, Lithuania
E-mail: norai_s@yahoo.com

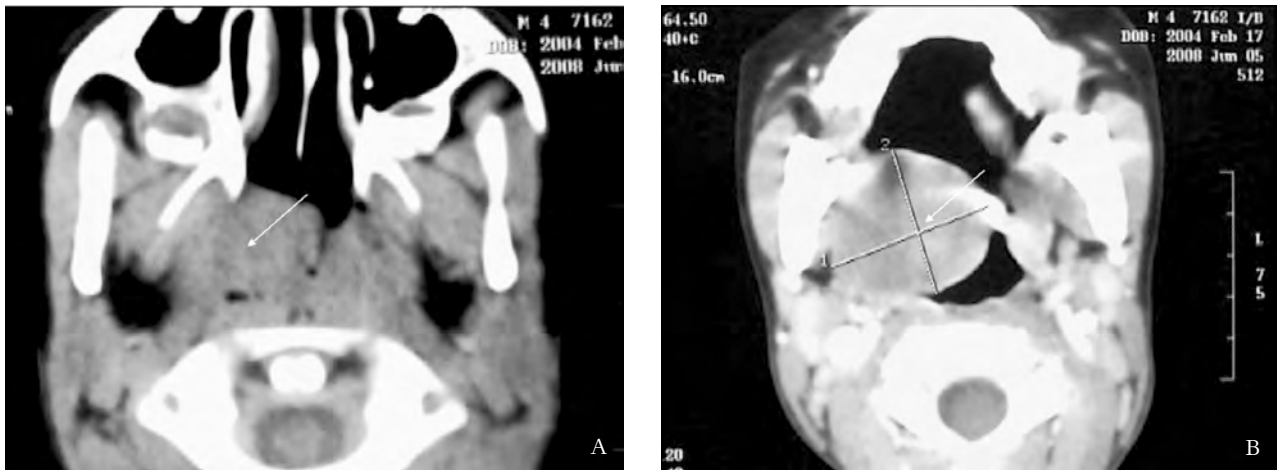


Fig. 1. Nonenhanced axial CT scan showing a large mass arising from the right pharyngeal (A) and palatal (B) tonsils (arrows) in a 4-year-old boy

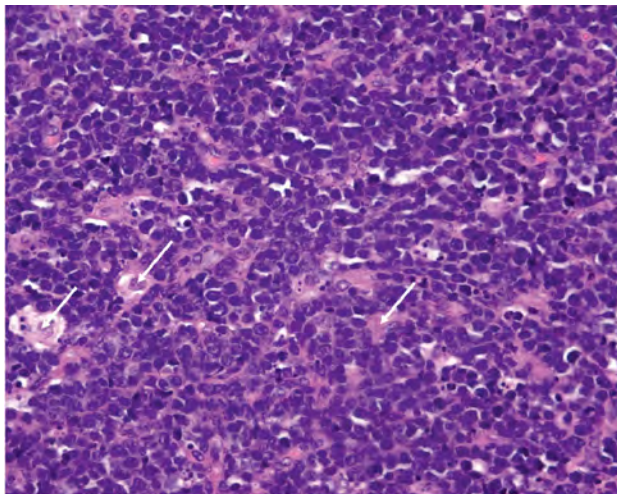


Fig. 2. Characteristic histologic view of Burkitt's lymphoma "Starry sky" appearance, with numerous nonneoplastic bright macrophages (arrows) containing cellular debris among malignant lymphoid cells. Hematoxylin-eosin, $\times 40$.

Discussion

Lymphomas are the second most common malignancy of the head and neck after squamous cell carcinoma (6). Sporadic non-African Burkitt's lymphoma accounts for less than 1% of head and neck malignancies with an incidence of 2–3 cases per million per year in the United States and Europe (2–4, 6). This form of the disease is most common among older children and young adults (2–4, 7). Most tumors arise from the abdomen (more than 50% of cases) involving the distal ileum, stomach, cecum and/or mesentery, kidney, testis, ovary, bone marrow, or central nervous system (1–8). Extranodal sites in the head and neck are involved in less than 25% of cases (3, 4, 7). The American Burkitt's Lymphoma Registry reported that only 2.9% of cases showed tonsillar involvement (7).

As Burkitt's lymphoma is one of the most rapidly growing tumors in humans with a cell-doubling time of 24 hours, timely diagnosis and up-to-date treatment are essential for better disease outcomes (1, 8, 9). Making the diagnosis is complicated, especially for young children because of a variety of clinical symptoms. Burkitt's lymphoma of the tonsils usually presents with a unilateral painless tonsillar enlargement and the symptoms of throat discomfort and dysphagia (3, 4, 6). Cervical lymphadenopathy can be found in 60% of patients. Rarely, with the involvement of the nasopharynx, the signs of otitis media and snoring may occur (1, 4, 8). Presenting symptoms, such as a sore throat, otalgia, snoring, and breathing difficulties, can mimic acute upper airway infections including a peritonsillar abscess with the postponement of true diagnosis, especially in young children. In our presented case, the disease initially manifested with the symptoms not typical of Burkitt's lymphoma: a sore throat and otalgia with a rapid progression of snoring and breathing difficulties that were attributed to the upper airway infection by a family doctor. This is not surprising because otalgia and snoring are commonly associated with otitis media and adenoids in young children (1). In adults, otalgia may be an important symptom to suspect a pharyngeal tumor, but unfortunately, it presents only in 7% of patients with a tonsillar lymphoma (6). On admission to the otolaryngological department, an asymmetrical enlargement of the tonsils without an exudate and the rapid progression of the symptoms were the most specific signs for Burkitt's lymphoma in our case. The differential diagnosis for an asymmetrical enlargement of the tonsils should include peritonsillitis, peritonsillar abscess, and finally pharyngeal tumors including all types of high-grade B-cell lymphoma (1, 6–9). The diagnosis of Burkitt's lymphoma includes history

and physical examination, panendoscopy of aerodigestive tract, CT or magnetic resonance investigation, and biopsy of the primary site of presentation (4). The diagnosis in our case was made based on histologic examination and confirmed by immunohistochemistry. All forms of Burkitt's lymphoma have the same specific histologic characteristics that were clearly seen in our presented case: sheets of small-to-medium-sized monomorphic lymphoid cells and interspersed pale macrophages that have ingested apoptotic tumor cells giving a characteristic "starry sky" appearance (1–9). Immunophenotypically, Burkitt's lymphoma cells express B-cell lineage markers including CD19, CD20, CD22, CD74, CD79a, and CD10 (3, 4, 8–10).

Clinical staging using the 4-stage Murphy/St. Jude staging system for children is commonly made after the investigation of liver function tests, bone marrow aspiration/trephine biopsy, cerebrospinal liquid assessment, and chest x-ray (3, 4). In our case, stage II Burkitt's lymphoma was diagnosed that indicates one or two single extranodal tumors, with or without regional node involvement on the same side of the diaphragm (4).

The treatment of Burkitt's lymphoma is mainly based on aggressive combined cyclic chemotherapy (2, 3, 6, 9). The options of treatment used currently include polychemotherapy with cyclophosphamide, doxorubicin, vincristine, and prednisone with intra-

venous and intrathecal methotrexate and/or cytarabine or immunopolychemotherapy with the addition of monoclonal anti-CD20 antibody rituximab that may improve outcome (2, 3, 9). A standard combination of aggressive polychemotherapy was used in our case. Treatment success depends on the extent of the disease. Taking into account an extremely rapid growth of this type of tumor, early diagnosis and aggressive chemotherapy cocktails lead to excellent outcomes with current survival rates reaching 90% for 2 years in children with localized disease (1–5). Tonsillar lymphoma tends to be well-localized and thus is associated with a good outcome (1, 4). This tendency also was confirmed in our patient, who was found to be in remission 3 years after aggressive chemotherapy.

Conclusions

In pediatric and otorhinolaryngological practice, the symptoms, such as a sore throat, otalgia, snoring, and breathing difficulties, are frequently encountered as a result of a common pathology. Sometimes, however, this may be suggestive of a rare and aggressive malignancy. Clinicians should be aware in any case of tonsillar asymmetry and the rapid progression of throat symptoms.

Statement of Conflict of Interest

The authors state no conflict of interest.

References

1. Wu K, Majumdar S, Bull PD. Blocked nose and snoring in a 6-year-old boy. *Int J Pediatr Otorhinolaryngol* 2004;68:597-600.
2. Griniūtė R. Limfoma. (Lymphoma.) In: Juozaitytė E, editor. *Onkologija šeimos gydytojui. (Oncology for family doctor.) Part 2.* Kaunas: Vitae Litera; 2008. p. 223-30.
3. Feinberg SM, Ou SH, Gu M, Shibuya TY. Burkitt's lymphoma of the base of the tongue: a case report and review of the literature. *Ear Nose Throat J* 2007;86:356-60.
4. Banthia V, Jen A, Kacker A. Sporadic Burkitt's lymphoma of the head and neck in the pediatric population. *Int J Pediatr Otorhinolaryngol* 2003;67:59-65.
5. Valenzuela-Salas B, Dean-Ferrer A, Alamillos-Granados FJ. Burkitt's Lymphoma: a child case presenting in the maxilla, clinical and radiological aspects. *Med Oral Patol Oral Cir Bucal* 2010;15:479-82.
6. Mohammadianpanah M, Daseshbod Y, Ramzi M, Hamidizadeh N, Dehghani SJ, Bidouei F, et al. Primary tonsillar lymphomas according to the new World Health classification: to report 87 cases and literature review and analysis. *Ann Hematol* 2010;89:993-1001.
7. Tewfik LT, Bond M, Al-Ghamdi K, Bernard C. Burkitt's lymphoma of the tonsil in children. *J Otolaryngol* 1995;25:205-8.
8. Freedman AS, Aster JC. Clinical manifestations, pathological features, and diagnosis of Burkitt's lymphoma. *UpToDate* 2011 Jan-May. Available from: URL: <http://www.uptodate.com>
9. Ferry JA. Burkitt's lymphoma: clinicopathologic features and differential diagnosis. *Oncologist* 2006;11:375-83.
10. Blum KA, Lozanski G, Byrd JC. Adult Burkitt leukemia and lymphoma. *Blood* 2004;104:3009-20.

Received 6 March 2012, accepted 29 May 2012