

Effect of Gold Nanoparticles in the Treatment of Established Collagen Arthritis in Rats

Laima Leonavičienė¹, Gailutė Kirdaitė¹, Rūta Bradūnaitė¹, Dalia Vaitkienė^{1, 2},
Audrius Vasiliauskas¹, Danguolė Zabulytė¹, Almira Ramanavičienė¹, Arūnas Ramanavičius^{1, 3},
Teisutis Ašmenavičius¹, Zygmunt Mackiewicz¹

¹State Research Institute Centre for Innovative Medicine, Vilnius, Lithuania, ²Faculty of Medicine, Vilnius University, ³Faculty of Chemistry, Vilnius University, Lithuania

Key words: gold nanoparticles; collagen-induced arthritis; rats.

Summary. Background and objective. The role of gold nanoparticles (AuNPs) in the treatment of autoimmune diseases remains vague. Therefore, the aim of this study was to determine the effect of AuNPs in the treatment of rats with established collagen-induced arthritis (CIA).

Material and Methods. A total of 24 Wistar male rats with established CIA were used. AuNPs measuring 13-nm and 50-nm were prepared according to standard procedures, and their size was determined using transmission electron microscopy. These gold particles were injected intra-articularly 5 times a week, 12 injections in total. Body and organ weight, arthritic profiles based on paw swelling, histological changes in the joints and internal organs, blood indices, and serum oxidative products were investigated.

Results. An examination of the course of the experimental disease and a subsequent histological analysis as well as hematological studies revealed a nontoxic effect of AuNPs on the vital organs. The treatment of the rats with established CIA by 13-nm and 50-nm gold nanoparticles decreased joint swelling by 49.7% ($P < 0.002$) and 45.03% ($P < 0.01$), respectively. That corresponded to the decrease in statistically significant histological changes in articular tissues. AuNPs showed their antioxidant effect by increasing the level of antioxidant enzyme catalase.

Conclusions. The continuous intra-articular administration of AuNPs not only reduced the inflammation, joint swelling, and development of polyarthritis, but also reduced histological changes in articular tissues without toxic effects on the internal organs. The results obtained disclose the role of AuNPs as antioxidant agents.

Introduction

An area of research where it is thought that nanotechnology will have a profound impact is within medical science. The discovery of therapeutic inorganic nanoparticles (NPs) is a very important field of nanomedicine. In recent years, the role of NPs in medicine and biology has rapidly increased. However, very little is known about their effect in the treatment of rheumatic diseases.

Rheumatoid arthritis (RA) is a chronic systemic autoimmune disease of unknown etiology, which develops as synovitis with neovascularization and pannus formation. The animal models of arthritis are not an exact reflection of the situation in RA, but they are widely used to investigate some aspects of RA pathogenesis and its treatment. Collagen-induced arthritis (CIA) is a model of chronic joint inflammation induced by type II collagen (CII) and characterized by many similar pathophysiological and pathobiochemical changes as RA in humans. Although the pathogenesis of CIA has not been fully elucidated yet, the progression of synovitis in both

CIA and RA is characterized by pronounced tumor-like expansion of the synovium (1) where neovascularization plays a pivotal role. There is much evidence that RA is closely linked to angiogenesis, and some important angiogenic mediators have been found to be important in the proliferation of synovium and tenosynovium of rheumatoid joints. Angiogenesis has been recognized as a key event in the formation and maintenance of pannus in RA, particularly in the early stages of the disease (2).

Recent studies have shown that an intra-articular administration of 180- $\mu\text{g}/\text{mL}$ 13-nm gold nanoparticles (AuNPs) ameliorates the course of CIA in rats (3). A colloidal solution of AuNPs 27 \pm 3 nm in size administered subcutaneously at a dose of 3.3 $\mu\text{g}/\text{kg}$ also suppressed the development of mycobacterium-, collagen-, and pristane-induced arthritis in rat models in contrast to sodium aurothiomalate that was only effective against mycobacterium-induced arthritis, which is the most inflammatory of these three forms of arthritis and is characterized by active leukocytes generating reactive oxygen-derived species (ROS), e.g., hydrogen peroxide (H_2O_2) and hypochlorite (OCl^-) (4).

Oxygen-free radicals are implicated as mediators of joint tissue damage in RA (5) and in experimen-

Correspondence to L. Leonavičienė, State Research Institute Centre for Innovative Medicine, Žygimantų 9, 01102 Vilnius, Lithuania. E-mail: laima.leonaviciene@ekmi.vu.lt

tally induced arthritis (6). Although many reports have been released on the relationship between oxidative stress and inflammation, its role in inflammatory diseases is still unclear. It remains the main research area in particle toxicology. As one of the toxic mechanisms of nanoparticles, reactive oxygen species (ROS) generation has been widely studied. Nevertheless, the link between AuNPs and oxidative stress has not been well established. There are contradictory data about the oxidative stress caused by AuNPs. Some studies have revealed that AuNPs may induce oxidative stress (7, 8), but in others, no significant induction of oxidative stress or inflammatory response due to AuNPs has been observed (9). Furthermore, recent studies have demonstrated that AuNPs are potential antioxidants (10, 11) effective in quenching reactive oxygen species, including H_2O_2 and the superoxide anion radical (O_2^-), in a dose-dependent manner (12).

The aim of the study was to determine the effects of AuNPs of different sizes (13 nm and 50 nm) injected intra-articularly to the rats with established CIA, and the development of clinical signs of arthritis, changes in blood indices, antioxidant potential, body and organ weight, and histological changes in the joint tissues and internal organs were investigated.

Materials and Methods

Animals. A total of 24 male Wistar rats (approximately 10 weeks old) weighting 180–210 g were obtained from the vivarium of the Department of Immunology, State Research Institute Centre for Innovative Medicine, Vilnius, Lithuania, and acclimated for 7 days. All the rats were kept in plastic cages (8 rats per cage) with rat chow and tap water ad libitum. During the experiment, the animals were housed at 20°C–22°C and relative humidity of 50%–70% with a 12-hour light/dark cycle. Throughout the study, the animals were cared for in accordance with the European Convention and Guide for the Care and Use of Laboratory Animals and with the laws of the Republic of Lithuania. All the rats were used with the approval of the Lithuanian Laboratory Animal Use Ethics Committee under the State Food and Veterinary Service (No. 0207–2010).

Substances (Solvents and Reagents). Incomplete Freund's adjuvant (IFA), CII from bovine septum, acetic acid, 10% formalin, spirit-formol, hematoxylin, eosin, picofuchsin, toluidine blue, methylgreen-pyronin Y, acetic acid, trichloroacetic acid, orthophosphoric acid, thiobarbituric acid, nitric acid, ferrous sulfate, ascorbic acid, ammonium molybdate, and hydrogen peroxide were obtained from Sigma-Aldrich Chemie and Fluka Chemie GmbH (Germany), and ketamine and xylazine from Bio-wet (Poland). Tetrachloroauric acid ($HAuCl_4 \cdot 3H_2O$)

and tannic acid were obtained from Carl Roth GmbH&Co (Germany), and sodium citrate from Penta (Czech Republic).

Synthesis and Analysis of Gold Nanoparticles. In the professional scientific literature, there are intricate data concerning toxic and potentially beneficial effects of AuNPs on mammalian cells and organs depending on the diameter of nanoparticles ranging from 3 to 100 nm. In this experiment, 13-nm and 50-nm particles were used. In the literature, the nanoparticles of such a size have generally been described as nontoxic, stable, and easily synthesized.

AuNPs measuring 13 nm and 20 nm were synthesized by reduction of $HAuCl_4$ by sodium citrate in the presence and absence of tannic acid as described previously (13, 14). Citrate-reduced AuNPs were chosen because they were synthesized by well-established methods. Synthesized AuNPs were characterized spectrophotometrically using a UV-VIS spectrophotometer Lambda 25, Perkin Elmer (Waltham, USA) (Fig. 1). The absorbance peak at $\lambda=520$ nm (approximately 0.88 A_{520} units/mL) is characteristic of 13-nm gold nanoparticles. The absorbance peaks for 20-nm and 50-nm gold nanoparticles were at $\lambda=531$ nm (approximately 1.59 A_{531} units/mL for a twice-diluted solution) and $\lambda=533$ nm (approximately 1.49 A_{533} units/mL for a twice-diluted solution), respectively.

It was assumed that the reduction from gold (III) to gold atoms was 100% complete. For the preparation of 13-nm AuNPs, the initial concentration of gold (according to mass) was 50 $\mu g/mL$. For the preparation of 20-nm AuNPs, the initial concentration of gold (according to mass) was 188 $\mu g/mL$. The size of synthesized AuNP was confirmed using

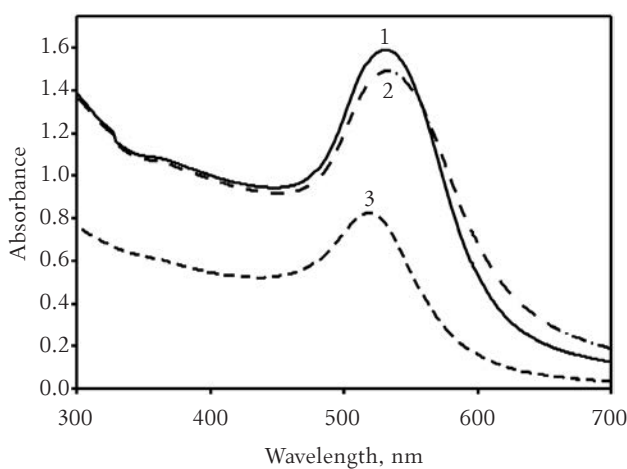


Fig. 1. UV-visible spectra of gold nanoparticle colloids of different size

- 1, 20-nm gold nanoparticles (twice diluted);
- 2, 50-nm gold nanoparticles (after dialysis, twice diluted);
- 3, 13-nm gold nanoparticles.

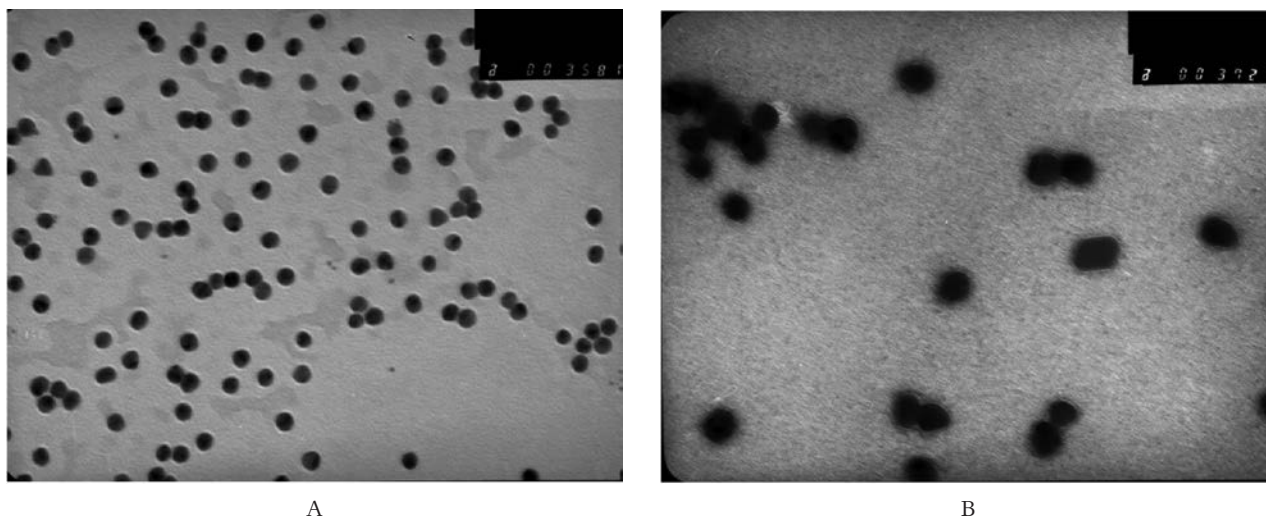


Fig. 2. The size of gold nanoparticles analyzed by transmission electron microscopy (TEM)

A, 13-nm gold nanoparticles; B, 50-nm gold nanoparticles (after dialysis in the water, 20-nm AuNPs became 50 nm) (original magnification $\times 200\,000$).

transmission electron microscopy (TEM) (JEOL, Japan). After dialysis of a 20-nm AuNP colloidal solution in the water, it was clearly shown that the average size of the particles was 50 nm. For further experiments, 13-nm and 50-nm AuNPs were used without any additional modifications (Fig. 2). The particle suspensions were sterilized by UV light treatment for 1 day.

Induction, Assessment, and Treatment of Collagen Arthritis. Bovine type II collagen prepared under a defined protocol was used since collagen degradation would affect arthritogenicity (15). Collagen was dissolved at a concentration of 2 mg/mL in 0.05-M acetic acid by gently stirring overnight at 4°C. Since the quality of the collagen emulsion for immunization is critical for inducing severe arthritis, an electric homogenizer with a small blade for stirring the IFA and CII emulsion in a syringe was placed in an ice-water bath to prevent denaturation of collagen.

CIA was initiated in 24 Wistar rats using the footpad method (16, 17) under light anesthesia with an injection of 0.1-mL ketamine-xylazine. To induce CIA, each rat was immunized subcutaneously into the left hind paw on day 0 with 0.1 mL of cold CII (0.2 mg of CII per rat) emulsified in IFA. Thirteen days after the administration of the adjuvant, when joint inflammation reached a maximum in all the rats, the animals were divided into 3 experimental groups (8 rats per group): control rats with CIA (group 1), rats with CIA treated with 13-nm AuNPs (group 2), and rats with CIA treated with 50-nm AuNPs (group 3). The ankle joints were intra-articularly injected 5 times a week with 13-nm (the initial concentration of gold was 50 $\mu\text{g}/\text{mL}$) and 50-nm (the initial concentration of gold was 188 $\mu\text{g}/\text{mL}$) AuNPs,

which were suspended in 20 μL of phosphate-buffered saline (PBS). The total number of injections was 12. The control group was intra-articularly injected with 0.9% saline solution (20 μL). There were no significant differences in joint swelling of the left hind leg of the animals between the groups. The course of CIA was assessed according to paw swelling, development of polyarthritis, and histological changes in the soft periarticular tissues, synovium, and cartilage. The development of arthritis in the left hind paw was monitored plethysmographically by recording changes in a paw volume by water displacement with a plethysmometer (PVP1001, Kent Scientific Corporation). The frequency of polyarthritis was determined according to the number of rats with clinical evidence of joint inflammation in noninjected paws during the study period. All the measurements were made at the same time of a day. Body weight and hind paw swelling were recorded in the control and experimental groups 3 times a week until day 28, when the experiment ended.

Blood and Tissue Collection. The animals were monitored until day 28 after immunization with CII, when they were humanely killed by decapitation under ketamine-xylazine anesthesia. Their internal organs were examined macroscopically, weighed, and taken for morphological analysis. Erythrocyte and leukocyte counts (made using a Picoscale, Hungary) and erythrocyte sedimentation rate (ESR) were determined in their blood. The obtained indices of the experimental groups were compared with the indices of the control animals. Blood, liver, kidneys, spleen, lungs, and joints were used for further analysis. Blood samples were centrifuged at 800g for 10 min to obtain serum samples, which were stored frozen at -20°C until testing.

Determination of the Levels of Malondialdehyde and the Activity of Catalase in Blood Serum. The levels of malondialdehyde (MDA), a marker of lipid peroxidation, and the activity of antioxidant enzyme catalase (CAT) were determined in the blood serum of all the experimental groups. Reaction products were detected by corresponding spectrophotometrical parameters.

The MDA level in blood serum, expressed in nmol/mL, was determined by the thiobarbituric acid reaction at 535 nm and 580 nm by the method of Gavrilov et al. (18). CAT activity, expressed in mmol/(L·min), was measured at 410 nm as described by Koroliuk et al. (19).

Histological Analysis. Liver, kidneys, spleen, and lungs were collected and fixed in 10% formalin neutral buffer solution, embedded in paraffin, and cut into 5- μ m sections. Joints of the injected paws were fixed in 10% neutral formalin following decalcification in 10% nitric acid (HNO₃) and paraffin embedding. Histological sections of joints and internal organs were stained with hematoxylin-eosin, picrofuchsin, toluidine blue, methyl-green-pyronin Y, and safranin O. Lung sections were stained with hematoxylin and eosin and evaluated for inflammation and epithelial damage.

The severity of histopathological changes was evaluated using a score from 0 to 3. Histological assessment of inflammatory infiltration with lymphocytes, plasma cells, macrophages, and granulocytes and various other inflammatory symptoms in internal organs, synovium, and soft periarticular tis-

ues as well as evaluation of cartilage damage were performed in a blinded manner by two independent microscopists using a 0–3-point scale, where 0 indicated the absence of changes and 3 indicated the most severe expression of a particular sign. Such estimation during the course of arthritic processes is widely initiated in the scientific literature.

Statistical Analysis. All the data are expressed as mean \pm SEM. Statistical analysis was done using SPSS/PC software version 8.0 with the *t* test for continuous variables. *P* values less than 0.05 were considered significant. The nonparametric Mann-Whitney test was used for statistical analysis of histological changes in the organs.

Results

Effect of AuNPs on Clinical Signs of Collagen-Induced Arthritis

Organs and Blood Indices. The body weight of the tested animals was not significantly different between the groups before commencement of the study. After the treatment with AuNPs, the total body weight of the animals was higher than that of the control rats with CIA, but the difference was not significant. To estimate the impact of the treatment with AuNPs on systemic inflammation, the weight of the internal organs and blood indices of all the animals were measured at the end of the study.

The average absolute and relative weight of the organs at the end of the experiment is shown in Table 1. A postmortem examination of the internal organs revealed a significantly lower relative weight

Table 1. Absolute and Relative Weight of Organs of Wistar Rats With Collagen-Induced Arthritis After Treatment With Gold Nanoparticles

	Group 1 (CIA + saline solution)	Group 2 (CIA + 13-nm AuNPs)	Group 3 (CIA + 50-nm AuNPs)
Body weight, g	241.79 \pm 9.97	247.11 \pm 13.84	254.60 \pm 21.18
Liver			
Absolute, g	10.80 \pm 0.36	9.60 \pm 0.50	9.85 \pm 0.75
Relative, g/100 g body weight	4.49 \pm 0.14	3.89 \pm 0.08*	3.91 \pm 0.21*
Kidneys			
Absolute, g	2.35 \pm 0.07	2.15 \pm 0.10	2.41 \pm 0.11
Relative, g/100 g body weight	0.98 \pm 0.03	0.87 \pm 0.016*	0.97 \pm 0.046
Spleen			
Absolute, g	1.08 \pm 0.08	0.81 \pm 0.03*	0.91 \pm 0.04
Relative, g/100 g body weight	0.44 \pm 0.025	0.33 \pm 0.016*	0.37 \pm 0.036
Thymus			
Absolute, g	0.36 \pm 0.02	0.55 \pm 0.05*	0.61 \pm 0.07*
Relative, g/100 g body weight	0.15 \pm 0.008	0.22 \pm 0.02*	0.24 \pm 0.02*
Lungs			
Absolute, g	1.65 \pm 0.086	1.68 \pm 0.07	1.67 \pm 0.11
Relative, g/100 g body weight	0.68 \pm 0.03	0.68 \pm 0.028	0.67 \pm 0.03

Values are expressed as mean \pm SEM (n=8). Collagen-induced arthritis (CIA) was induced by a single injection of 0.1-mL bovine type II collagen (0.2 mg per rat) emulsified in incomplete Freund's adjuvant (IFA) into the left hind paw on day 0. Two groups of animals from day 13 received intraarticular treatment with 13-nm (group 2, the initial concentration of gold was 50 μ g/mL) and 50-nm (group 3, the initial concentration of gold was 188 μ g/mL) AuNPs suspended in 20 μ L of PBS. The total number of injections performed 5 times a week was 12. The control group was injected intra-articularly with 20- μ L 0.9% saline (group 1).

**P*<0.05 vs. control group.

of the liver ($P<0.01$; $P<0.05$) and higher weight of the thymus ($P<0.01$; $P<0.002$) in the groups treated with 13-nm and 50-nm AuNPs, respectively. The relative weight of the kidneys and absolute and relative weight of the spleen were significantly lower only in the group of animals treated with 13-nm AuNPs ($P<0.01$) in comparison with the control group.

Changes in the blood indices are shown in Fig. 3A. Hematological analysis revealed a nontoxic effect of AuNPs in rats. The ESR and leukocyte count in both treated groups of rats with CIA was markedly lower than in the control group. Besides, 13-nm and 50-nm AuNPs decreased ESR by 55.83% ($P<0.001$) and 61.25% ($P<0.001$), respectively. The leukocyte count was lower by 12.98% and 13.78% ($P<0.05$), respectively, as compared with the control group. The erythrocyte count increased significantly only in the rats with CIA treated with 13-nm AuNPs ($P<0.05$).

MDA Levels and CAT Activity in Blood Serum

Free radical formation resulting in lipid peroxidation, measured as the MDA level in rat serum, is shown in Fig. 3B. The MDA levels were found to be reduced in the rats with CIA treated with both 13-nm and 50-nm AuNPs compared with the control group (Fig. 3B). The treatment of the rats with established CIA with 13-nm AuNPs resulted in a 37.7% decrease in the MDA generation in comparison with the control rats, and the differences between these

groups were near to significant ($t=1.94$). In the rats treated with 50-nm AuNPs, a 9.4% decrease in the MDA level was also observed. This demonstrates an inhibitory effect of AuNPs, especially 13 nm in size, on the generation of MDA.

The activities of serum antioxidant enzyme CAT were by 31.3% and 20% higher in the CIA rats treated with 13-nm ($P<0.02$) and 50-nm ($P<0.05$) AuNPs, respectively, in comparison with the control rats (Fig. 3B).

Histological Changes in Internal Organs

Histopathological findings revealed a nontoxic effect of AuNPs on the liver, kidneys, spleen, and lungs (Table 2). The liver of the animals treated with AuNPs showed a significantly reduced hepatic alteration. The dystrophic processes were reduced by 53% and 62% ($P<0.001$), and necrosis by 69% and 70% ($P<0.001$) in the animals treated with 13-nm and 50-nm AuNPs in comparison with the control rats, respectively. A significant decrease in lymphocyte infiltration, a general inflammatory reaction ($P<0.01-0.002$), and a markedly lower penetration of inflammatory cells into hepatic lobules were observed in hepatic stroma ($P<0.02-0.01$). Moreover, a significant decrease in the macrophage count was documented in the 13-nm AuNP-treated rats.

In comparison with the control group, less severe peribronchiolitis and interstitial, alveolar, and vascular lesions in the lungs of the treated animals were

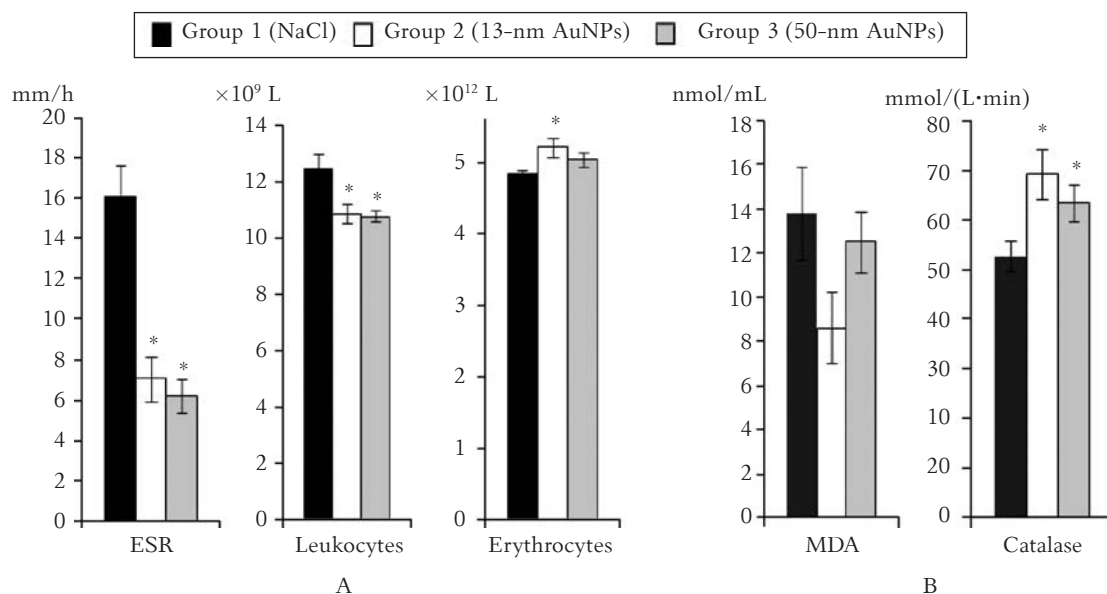


Fig. 3. Blood (A) and pro- and antioxidant system indices (B) in rats with established collagen-induced arthritis treated by gold nanoparticles (AuNPs) of various sizes

Values are expressed as mean \pm SEM ($n=8$). Collagen-induced arthritis (CIA) was induced by a single injection of 0.1-mL bovine type II collagen (0.2 mg per rat) emulsified in incomplete Freund's adjuvant (IFA) into the left hind paw on day 0. Two groups of animals from day 13 received intraarticular treatment with 13-nm (group 2, the initial concentration of gold was 50 $\mu\text{g}/\text{mL}$) and 50-nm (group 3, the initial concentration of gold was 188 $\mu\text{g}/\text{mL}$) AuNPs suspended in 20 μL of PBS. The total number of injections performed 5 times a week was 12. The control group was injected intra-articularly with 20- μL 0.9% saline (group 1).

* $P<0.05$ vs. control group.

Table 2. Pathomorphological Changes in Internal Organs of Arthritic Rats Treated with Various Sizes of Gold Nanoparticles

Organ	Index	Group 1 (CIA + saline solution)	Group 2 (CIA + 13-nm AuNPs)	Group 3 (CIA + 50-nm AuNPs)	
Parenchyma alteration	Dystrophy	2.13±0.16	1.00±0.09*	0.81±0.16*	
	Necrosis	1.69±0.13	0.56±0.15*	0.50±0.16*	
Liver	<i>V. centralis</i> hypervolemia	0.44±0.11	0.50±0.13	0.25±0.09	
	Inflammatory infiltration	Lymphocytes	1.00±0.16	0.37±0.08*	0.25±0.09*
		Granulocytes	0.25±0.13	0.06±0.06	0
	Macrophages	0.56±0.11	0.19±0.13*	0.37±0.18	
	General	1.00±0.16	0.38±0.08*	0.25±0.09*	
	Penetration into the lobules	1.06±0.15	0.37±0.18*	0.31±0.16*	
Fibrosis		0.12±0.08	0	0.50±0.16	
Lungs	Peribronchiolitis	1.00±0.25	0.75±0.16	0.38±0.18	
	Interstitial lesions	Lymphocytes	1.88±0.18	1.37±0.20	1.00±0.23*
		Rheumatoid granuloma	1.19±0.28	0.87±0.18	0.50±0.25
	Fibrosis	0.88±0.23	1.37±0.18	1.31±0.19	
	Alveolar lesions	Hemorrhages	0.75±0.16	0.62±0.18	0.25±0.13*
		Inflammatory infiltration	0.38±0.20	0.56±0.22	0.31±0.16
	Vascular lesions	Fibrinoid necrosis	0.56±0.17	0.37±0.16	0.13±0.12
Fibrosis		1.31±0.36	1.31±0.26	1.25±0.27	
Spleen	Hyperplasia of lymphoid follicles	1.88±0.18	1.00±0.13*	0.50±0.13*	
	Arterial changes	Fibrosis	2.13±0.20	1.69±0.13	1.44±0.15*
		Hypervolemia	1.25±0.38	1.12±0.31	1.19±0.23
	Erythrocyte hemolysis	1.38±0.32	0.75±0.25	0.44±0.15*	
	Red/white pulp ratio	Normal	0	0.13±0.12	0.44±0.17*
		Abnormal	1.38±0.28	0.44±0.17*	0.31±0.13*
Inflammatory cells	Polymorphonuclear	0.75±0.31	0.69±0.23	0.44±0.15	
	Macrophages	0	0	0.62±0.18	
Kidneys	Glomerulus	Thickening of capillary walls	0.06±0.06	0	0
		Mesangium proliferation	0.31±0.09	0.25±0.09	0.25±0.09
		Focal glomerular sclerosis	0.06±0.06	0.19±0.09	0.19±0.09
	Inflammation	0.38±0.08	0.19±0.09	0.12±0.08*	
	Tubular epithelium edema	0.31±0.09	0.19±0.09	0.19±0.09	
	Renal stroma inflammation	0.25±0.09	0.13±0.08	0.06±0.06	
Arterial fibrosis		0.75±0.09	0.44±0.15	0.25±0.09*	

Values are expressed as mean±SEM (n=8). Collagen-induced arthritis (CIA) was induced by a single injection of 0.1-mL bovine type II collagen (0.2 mg per rat) emulsified in incomplete Freund's adjuvant (IFA) into the left hind paw on day 0. Two groups of animals from day 13 received intraarticular treatment with 13-nm (group 2, the initial concentration of gold was 50 µg/mL) and 50-nm (group 3, the initial concentration of gold was 188 µg/mL) AuNPs suspended in 20 µL of PBS. The total number of injections performed 5 times a week was 12. The control group was injected intra-articularly with 20-µL 0.9% saline (group 1). The histological assessment of changes in internal organs was performed in a blinded manner by a pathologist on a 0–3 scale, where 0 indicated the absence of changes and 3 indicated the most severe expression of a particular symptom.

* $P < 0.05$ vs. control group.

found. Treatment with 50-nm AuNPs resulted in a significantly decreased infiltration with lymphocytes ($P < 0.01$) and hemorrhages ($P = 0.036$).

The study of the spleen histology also revealed the most pronounced changes in the control rats with CIA, where hyperplasia of lymphoid follicles, arterial changes, fibrosis, hypervolemia, hemolysis of erythrocytes, and an abnormal ratio of red to white pulp were found (Table 2). In the spleen of some animals, the germinal centers, single megakaryocytes, and sparse infiltration with polymorphonuclear (PMN) cells under the capsule and in stroma were observed. There were no disruptions due to the treatment with AuNPs. Conversely, 13-nm and

50-nm AuNPs significantly decreased hyperplasia of lymphoid follicles ($P < 0.002$ – 0.001) and an abnormal ratio of red to white pulp ($P < 0.02$ – 0.01). Moreover, the lowest arterial fibrosis ($P < 0.02$), erythrocyte hemolysis ($P < 0.02$), a significant increase in the ratio of red to white pulp ($P < 0.05$), and an increased score of macrophages ($P < 0.02$) after the treatment with 50-nm AuNPs were revealed.

The histological studies of the kidneys showed slight pathomorphological changes in renal stroma and glomeruli in the control rats. Only 1 (12.5%) of the 8 animals had very slight thinning of capillary walls and focal sclerosis, 5 (62.5%) had mesangium proliferation, and 6 (75%) had glomerular inflam-

mation. The latter index significantly decreased by 68.4% in the rats treated with 50-nm AuNPs compared with the control group ($P<0.05$), and the traces of inflammation were observed only in 2 (25%) of the 8 rats. In all the tested groups, only very slight edema in the tubular epithelium was found, and this index was lower by 38.7% in both treated groups. Inflammation in renal stroma insignificantly decreased by 50% and 74.8% in the rats treated with 13-nm and 50-nm AuNPs, respectively. Traces of arterial fibrosis (50% of rats) and minimal arterial fibrosis (50% of animals) were observed in the control group of rats with CIA. This index was decreased by 44.3% in case of 13-nm AuNPs and by 56.7% in case of 50-nm AuNPs ($P<0.002$).

Effect of AuNPs on Joint Swelling and Development of Polyarthrititis

CIA was induced in male Wistar rats by a footpad injection of CII emulsion in IFA. The typical time course for the development and progression of the disease, as assessed by the mean arthritis joint swelling, is shown in Fig. 4, which illustrates the evolution of arthritis in the treated and untreated rats with CIA. The course of the experimentally induced disease was followed up for 28 days af-

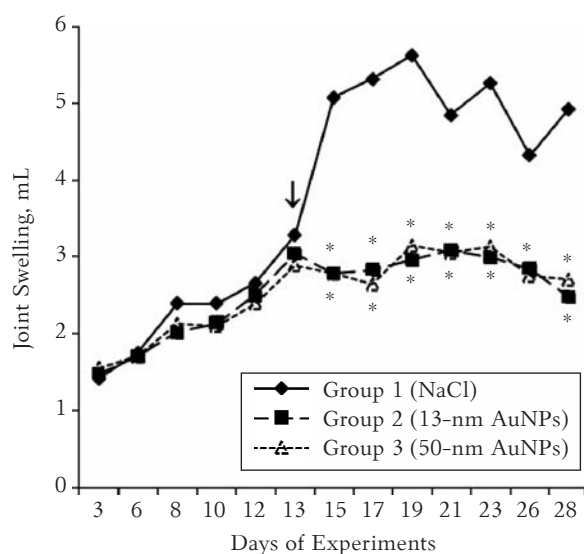


Fig. 4. Joint swelling in rats with established collagen-induced arthritis treated by gold nanoparticles (AuNPs) of various sizes. Values are expressed as mean \pm SEM (n=8). Collagen-induced arthritis (CIA) was induced by a single injection of 0.1-mL bovine type II collagen (0.2 mg per rat) emulsified in incomplete Freund's adjuvant (IFA) into the left hind paw on day 0. Two groups of animals from day 13 (arrow) received intraarticular treatment with 13-nm (group 2, the initial concentration of gold was 50 μ g/mL) and 50-nm (group 3, the initial concentration of gold was 188 μ g/mL) AuNPs suspended in 20 μ L of PBS. The total number of injections performed 5 times a week was 12. The control group was injected intra-articularly with 20- μ L 0.9% saline (group 1). * $P<0.05$ vs. control group.

ter initial footpad method immunization, and the treatment was started from day 13, when joint inflammation reached a maximum in all the rats. A marked decrease in joint swelling was revealed in both treated groups ($P<0.05$ – 0.001), and at the end of the experiment, it was lower than in the control group by 49.7% ($P<0.002$) and 45.03% ($P<0.01$) in the groups treated with 13-nm and 50-nm AuNPs, respectively.

The earliest onset of polyarthrititis, characterizing the generalization of the disease and exacerbation of the autoimmune process, was observed on day 13 in 25% of the animals in the control group and in 12.5% of the rats in the experimental groups. It should be noted that at the end of the experiment, 100% of the control rats developed polyarthrititis, but in the groups treated with 13-nm and 50-nm AuNPs, the corresponding numbers were 50% and 62.5%, respectively.

Histological Features of Arthritis

The histological examination of the joints of the injected paw on day 28 after arthritis induction showed the most expressed soft tissue pathology in the control group of rats (Table 3). A general inflammatory reaction and soft tissue infiltration with lymphocytes and leukocytes were significantly lower in the rats treated with 50-nm AuNPs ($P<0.02$ – 0.001). A significantly reduced edema ($P<0.01$ – 0.001), angiomasia ($P<0.001$), and disorganization of connective tissue (γ -metachromasia) ($P<0.01$ – 0.001) in comparison with the control group were identified in both treated groups. AuNPs also markedly enhanced fibrotic processes in soft periarticular tissues ($P<0.002$ – 0.001).

The most expressed pathological changes in the synovium were found in the control group with CIA. Synovial villi proliferation ($P<0.01$ – 0.001), edema ($P<0.002$ – 0.0001), and γ -metachromasia ($P<0.01$ – 0.001) significantly reduced after the treatment of CIA with AuNPs. Moreover, 13-nm and 50-nm AuNPs suppressed inflammatory infiltration with lymphocytes ($P<0.001$) and a general inflammatory reaction ($P<0.01$), whereas 50-nm AuNPs, beside the aforementioned significant changes ($P<0.001$), markedly decreased infiltration with macrophages ($P<0.001$). AuNPs of both sizes significantly suppressed synovial angiomasia and intensified fibrotic processes ($P<0.001$ – 0.0001).

In the cartilage of the treated animals, considerably fewer erosions, *usurae*, and fissures ($P<0.05$ – 0.001) were observed. No fissures were found in the rats, which received 50-nm AuNPs. Treatment with 13-nm AuNPs resulted in a significantly decreased glycosaminoglycan content ($P<0.01$), but no decrease was observed by using the treatment with 50-nm AuNPs. After the treatment with AuNPs of both

Table 3. Pathomorphological Changes in Joints of Arthritic Rats Treated With Gold Nanoparticles of Various Sizes

Tissue	Index	Group 1 (CIA + saline solution)	Group 2 (CIA + 13-nm AuNPs)	Group 3 (CIA + 50-nm AuNPs)	
Soft periarticular tissues	Inflammatory infiltration	Lymphocytes	1.50±0.19	1.19±0.09	0.81±0.16*
		Leukocytes	2.37±0.31	1.69±0.38	0.44±0.20*
		Macrophages	1.19±0.21	1.19±0.16	0.63±0.18
		General	2.50±0.19	1.91±0.26	0.94±0.17*
	Edema	2.19±0.13	1.44±0.20*	0.62±0.20*	
	Angiomatosis	1.94±0.06	1.12±0.08*	0.69±0.19*	
	Fibrosis	0	1.12±0.29*	1.19±0.23*	
	γ -metachromasia	1.44±0.24	0.44±0.15*	0.31±0.13*	
	Villi proliferation	2.00±0.13	1.31±0.19*	0.63±0.12*	
	Edema	1.88±0.12	0.94±0.20*	0.13±0.08*	
γ -metachromasia	1.25±0.16	0.44±0.20*	0.25±0.09*		
Necrosis	0.50±0.25	0.13±0.08	0		
Synovium	Inflammatory infiltration	Lymphocytes	1.94±0.15	0.44±0.15*	0.25±0.09*
		Granulocytes	1.00±0.23	0.50±0.16	0.50±0.09
		Macrophages	1.31±0.09	1.06±0.20	0.31±0.09*
		General	2.00±0.13	1.19±0.21*	0.50±0.09*
	Fibrosis	0	1.31±0.25*	1.69±0.16*	
	Angiomatosis	2.00±0.13	1.19±0.13*	0.50±0.09*	
Cartilage	Alteration	Erosion	2.19±0.13	1.69±0.16*	1.13±0.18*
		<i>Usura</i>	1.25±0.23	0.50±0.25*	0.13±0.08*
		Fissure	1.50±0.25	0.13±0.08*	0*
	Acid glycosaminoglycans (GAG)	2.00±0.13	1.50±0.09*	2.31±0.13	
	Pannus	1.75±0.13	1.19±0.25*	0.50±0.13*	
	Thinning of cartilage	1.75±0.13	0.87±0.22*	0.19±0.09*	

Values are expressed as mean±SEM (n=8). Collagen-induced arthritis (CIA) was induced by a single injection of 0.1-mL bovine type II collagen (0.2 mg per rat) emulsified in incomplete Freund's adjuvant (IFA) into the left hind paw on day 0. Two groups of animals from day 13 received intra-articular treatment with 13-nm (group 2, the initial concentration of gold was 50 µg/mL) and 50-nm (group 3, the initial concentration of gold was 188 µg/mL) AuNPs suspended in 20 µL of PBS. The total number of injections performed 5 times a week was 12. The control group was injected intra-articularly with 20-µL 0.9% saline (group 1). The histological assessment of changes in internal organs was performed in a blinded manner by a pathologist on a 0–3 scale, where 0 indicated the absence of changes and 3 indicated the most severe expression of a particular symptom.

* $P < 0.05$ vs. control group.

sizes, a significantly suppressed pannus formation ($P < 0.05$ – 0.001) and a markedly less pronounced thinning of cartilage ($P < 0.01$ – 0.001) were revealed.

Therefore, by day 28, the histological analysis revealed multiple symptoms of established arthritis including changes in soft periarticular tissues, synovium, and cartilage, which were most pronounced in the control untreated animals. Most pathological indices were lower in the treated rats, and many indices significantly differed between the control and treated groups.

Discussion

The treatment of RA has gone through many major changes. The promising potential of AuNPs in treating inflammatory and autoimmune diseases (3, 4) has augmented a greater interest to investigate anti-inflammatory and antioxidative activity of AuNPs in arthritic rats. Although animal models may not reproduce all the features of human RA, they can help understand normal inflammatory and immune responses during RA pathogenesis or serve

as vehicles to test novel therapeutic agents (20). CIA-induced CIA constitutes a model of autoimmunity that shares a number of pathophysiological, pathobiochemical, immunological, and genetic features with RA (21).

In our study, AuNPs were used as a therapeutic agent for the treatment of Wistar male rats with established CIA, and the data presented here demonstrated that they could be successfully used for this purpose. The final disease status was assessed on day 28 by examining blood indices, weight of internal organs and pathomorphological changes in them, clinical and histological changes in the joints, and pro- and antioxidant status of blood serum.

Thirteen days after the administration of the adjuvant, when joint inflammation in all the rats reached a maximum in the experiment, 12 intra-articular injections of 13-nm and 50-nm AuNPs showed a similar effect and decreased joint swelling. These observations also correlated well with histological changes in articular tissues (Table 3). We have found only two studies where AuNPs were

used for the treatment of CIA (3, 4). In the first, one prophylactic intra-articular injection of 13-nm nanogold on days 7 and 10 after induction of arthritis ameliorated the clinical course of CIA in the rats, exerted antiangiogenic activities, and reduced macrophage infiltration, which resulted in attenuation of arthritis (3). It should be noted that macrophages, which are responsible for the elimination of NPs from the blood, could be used as target cells in NP-based RA therapy in the future. Nanosized AuNPs (27 ± 3 nm) administered subcutaneously every second day from the beginning of the experiment till day 15 at a dose of $3.3 \mu\text{g}/\text{kg}$ have been proven to be effective in ameliorating the symptoms of CIA in Wistar rats (4). In our study, rats with established CIA were treated with 12 intra-articular injections of 13-nm and 50-nm AuNPs.

The examination of the natural clinical course of the disease and the subsequent histological analysis disclosed the greatest joint swelling, early development of polyarthritis, and the most distinct changes in periarticular tissues, synovium, and cartilage in the control animals. The histological analysis revealed multiple symptoms of established arthritis, including synovial inflammation, extensive cellular infiltration, edema, and pannus formation in the rats with severe arthritis. A significantly less aggressive disease in CIA rats treated with 13-nm and 50-nm AuNPs was found. Regardless of their size, AuNPs showed a similar positive therapeutic effect. Joint swelling was lower by 49.7% and 45.03% than in the control group, and polyarthritis developed in 50% and 62.5% of the rats treated with 13-nm and 50-nm AuNPs, respectively, while all the animals in the control group developed it.

Significantly reduced edema, angiomatosis, and γ -metachromasia in soft periarticular tissues and synovium, considerably fewer erosions, *usurae*, and fissures in the cartilage, suppressed pannus formation, and a markedly less pronounced thinning of the cartilage were identified in both treated CIA groups. Although both sizes of AuNPs significantly suppressed synovial villi proliferation, inflammatory infiltration with lymphocytes, and a general inflammatory reaction, only 50-nm AuNPs markedly decreased infiltration with lymphocytes and leukocytes in soft periarticular tissues and with macrophages in synovium. No fissures were found in the cartilage of the rats treated with 50-nm AuNPs, but 13-nm AuNPs significantly decreased glycosaminoglycan content, which showed the intensification of disorganization processes in cartilage.

The nontoxic effect of AuNPs in the present study was confirmed through hematological analysis and histological studies of the vital organs (liver, kidneys, spleen, and lungs) after administration of AuNPs for 12 times. It should be noted that there

are different reports of the extent of the toxic nature of AuNPs owing to their different modifications, surface functional attachments, and the shape and diameter of nanospheres (22, 23).

It is known that many factors have an impact on the course of CIA in rats. Changes in the weight of internal organs and inflammatory blood indices were observed. The treatment with 13-nm and 50-nm AuNPs significantly decreased ESR by 55.83% and 61.25% and leukocyte count by 13% and 13.8%. Erythrocyte count increased after 12 injections of 13-nm AuNPs.

The nontoxic effect of AuNPs on the liver, lungs, spleen, and kidneys was observed in the animals, which received AuNPs. In both treated groups, a markedly smaller weight of the liver and a greater weight of the thymus were found. Smaller AuNPs showed a better effect on the internal organs because among the mentioned effects on the liver and thymus, a decrease in the weight of the kidneys and spleen was found. These changes are characteristic of a positive effect of AuNPs on the features of experimental arthritis because, as documented elsewhere (24), one of the diagnostic characteristics for systemic inflammation in animal arthritis is a gradual increase in the weight of the spleen. On the other hand, a decrease in the weight of the thymus, as an index of undesirable systemic side effects, is observed in CIA rats. It increased after the treatment with AuNPs. The induction of CIA as a systemic inflammatory disease was accompanied by changes in the internal organs, and it is possible that our observed changes were associated with the severity of the pathological process, which was found in this study, because polyarthritis developed in 100% of the animals. The histological examination of the internal organs of the treated animals showed a significantly reduced hepatic alteration, less severe peribronchiolitis and interstitial, alveolar, and vascular lesions in the lungs. AuNPs of both sizes significantly reduced hyperplasia of lymphoid follicles and an abnormal ratio of red to white pulp in the spleen, dystrophic processes and necrosis, lymphocyte infiltration, a general inflammatory reaction in hepatic stroma, and penetration of inflammatory cells into hepatic lobules. Only 13-nm AuNPs significantly suppressed infiltration with macrophages; 50-nm AuNPs markedly decreased alveolar hemorrhages and lung tissue infiltration with lymphocytes and revealed the lowest splenic arterial fibrosis and the least hemolysis of erythrocytes. Slight changes were seen in the kidneys of the treated and untreated rats. In the kidneys, the treatment with AuNPs reduced histological changes, but only the use of 50-nm AuNPs significantly decreased glomerular inflammation and arterial fibrosis. These facts are important due to adverse reactions caused by gold

compounds, such as skin rash (in approximately 30% of the patients), proteinuria (0%–40%), thrombocytopenia and bone marrow suppression, pulmonary injury, and hepatic toxicity (25). In our study, no significant accumulation of AuNPs was observed in the internal organs (TEM data not shown).

The present study was also undertaken to compare the oxidant status in the blood serum of the treated and untreated Wistar rats with CIA because the nature of particle-induced oxidative stress was an important mechanistic paradigm for the evaluation of toxicity of nanomaterials (26). No significant induction of oxidative stress by AuNPs was observed in our study. Although it was reported that small AuNPs, such as 1.4 nm in diameter, could induce oxidative stress and produce ROS (7), our investigations revealed that 13-nm and 50-nm AuNPs attenuated the production of MDA and significantly upregulated the activity of CAT, which was considered as a primary antioxidant responsible for the direct elimination of ROS generated. Our data showing that AuNPs act as antioxidants and are nontoxic are consistent with the findings of other studies (10, 27). It should be noted that there are two main areas of consideration for a NP-based drug processing and clearance: first, rapid clearance of NPs will require large dosages in order to be effective and, second, excessive particle uptake can potentially interfere with the cells and/or organs of the immune system, resulting in immunological side effects (e.g., immunosuppression or immunostimulation) and potentially leading to organ damage (28).

In conclusion, our data demonstrated that AuNPs ameliorated the course of CIA, decreased the level of MDA, a marker of lipid peroxidation, and in addition significantly increased the activity of antioxidant enzyme CAT. No particle-related deaths, toxicity, or significant differences in body weight were observed in any treated group of rats in this study. The results described in this paper confirmed and extended earlier findings about 13-nm and 27-

nm AuNPs by other authors (3, 4). Here evaluated data showed that 13-nm and 50-nm AuNPs could be highly effective in the treatment of inflammatory arthritis. AuNPs could be considered as a novel therapeutic approach to local RA therapy. However, further investigation to exclude unexpected side effects would be required before clinical trials based on local therapy by AuNPs because it is thought that the intensity of oxidative stress is dependent on the size of AuNPs. Further studies might lead to the intra-articular application of AuNPs (alone or combined with other medications) in the therapy of RA.

Conclusion

Continuous intra-articular treatment of the rats with established CIA by 13-nm and 50-nm gold nanoparticles significantly decreased joint swelling by 49.7% and 45.03%, respectively. That corresponded to a decrease in the significant histological changes in articular tissues without toxic effects on the internal organs.

Acknowledgments

This research was funded by a grant (No. MIP-74/2010) from the Research Council of Lithuania.

All authors contributed to this study. G.K. planned the study and participated in its coordination. L.L. designed the study, drafted the manuscript, and performed the experiment and the analysis of the data. D.Z. and R.B. participated in carrying out the experiments and formatted the manuscript. D.V. and Z.M. performed the histological analysis and evaluation of pathomorphological changes. T.A. analyzed AuNPs by TEM. A.R. and A.R. synthesized AuNPs, and A.V. performed the biochemical analysis.

All authors read and approved of the final manuscript.

Statement of Conflicts of Interest

The authors state no conflicts of interest.

References

- Lu J, Kasama T, Kobayashi K, Yoda Y, Shiozawa F, Hanyuda M, et al. Vascular endothelial growth factor expression and regulation of murine collagen-induced arthritis. *J Immunol* 2000;164(11): 5922-7.
- Koch AE. Angiogenesis as a target in rheumatoid arthritis. *Ann Rheum Dis* 2003;62 Suppl 2: ii60-7.
- Tsai CY, Shiau AL, Chen SY, Chen YH, Cheng PC, Chang MY, et al. Amelioration of collagen-induced arthritis in rats by nanogold. *Arthritis Rheum* 2007;56(2):544-54.
- Brown CL, Bushell G, Whitehouse MW, Agrawal DS, Tupe SG, Paknikar KM, et al. Nanogold-pharmaceuticals. *Gold Bulletin* 2007;40/3:245-50.
- Hitchon CA, El-Gabalawy HS. Oxidation in rheumatoid arthritis. *Arthritis Res Ther* 2004;6(6):265-78.
- Leonavičienė L, Bradūnaitė R, Vaitkienė D, Vasiliauskas A, Keturkienė A. Collagen-induced arthritis and pro-/antioxidant status in Wistar and Lewis rats. *Biologija* 2008;54(4): 290-300.
- Pan Y, Leifert A, Ruau D, Neuss S, Bornemann J, Schmid G, et al. Gold nanoparticles of diameter 1.4 nm trigger necrosis by oxidative stress and mitochondrial damage. *Small* 2009;5(18):2067-76.
- Jia HY, Liu Y, Zhang XJ, Han L, Du LB, Tian Q, et al. Potential oxidative stress of gold nanoparticles by induced-NO releasing in serum. *J Am Chem Soc* 2009;131(1):40-1.
- Brandenberger C, Rothen-Rutishauser B, Mühlfeld C, Schmid O, Ferron GA, Maier KL, et al. Effects and uptake of gold nanoparticles deposited at the air-liquid interface of a human epithelial airway model. *Toxicol Appl Pharmacol* 2010;242(1):56-65.
- Sul OJ, Kim JC, Kyung TW, Kim HJ, Kim YY, Kim SH, et al. Gold nanoparticles inhibited the receptor activator of

- nuclear factor- κ b ligand (RANKL)-induced osteoclast formation by acting as an antioxidant. *Biosci Biotechnol Biochem* 2010;74(11):2209-13.
11. Barathmanikanth S, Kalishwaralal K, Sriram M, Pandian SR, Youn HS, Eom S, et al. Anti-oxidant effect of gold nanoparticles restrains hyperglycemic conditions in diabetic mice. *J Nanobiotechnology* 2010;8:16.
 12. Kajita M, Hikosaka K, Iitsuka M, Kanayama A, Toshima N, Miyamoto Y. Platinum nanoparticle is a useful scavenger of superoxide anion and hydrogen peroxide. *Free Radic Res* 2007;41(6):615-26.
 13. Slot JW, Geuze HJ. A new method of preparing gold probes for multiple-labeling cyto-chemistry. *Eur J Cell Biol* 1985; 38:87-93.
 14. Ramanaviciene A, Nastajute G, Snitka V, Kausaite A, German N, Barauskas-Memenas D, et al. Spectrophotometric evaluation of gold nanoparticles as red-ox mediator for glucose oxidase. *Sensors and Actuators: B. Chemical* 2009;137: 483-9.
 15. Michaelsson E, Malmstrom V, Reis S, Engstrom A, Burkhardt H, Holmdahl R. T cell recognition of carbohydrates on type II collagen. *J Exp Med* 1994;180(2):745-9.
 16. Joe SM, Lee IS, Lee YT, Lee JH, Choi BT. Suppression of collagen-induced arthritis in rats by continuous administration of dae-bang-poong-tang (da-fang-feng-tang). *Am J Chin Med* 2001;29(2):355-65.
 17. Li S, Lu A, Li B, Wang Y. Circadian rhythms on hypothalamic-pituitary-adrenal axis hormones and cytokines of collagen induced arthritis in rats. *J Autoimmun* 2004;22(4): 277-85.
 18. Gavrilov VB, Gavrilova AR, Mazhul LM. Methods of determining lipid peroxidation products in the serum using a thiobarbituric acid test. *Vopr Med Khim* 1987;33(1):118-22.
 19. Koroliuk MA, Ivanova LI, Maiorova IG, Tokarev VE. A method of determining catalase activity. *Lab Delo* 1988; (1):16-9.
 20. Quinones MP, Ahuja SK, Jimenez F, Schaefer J, Garavito E, Rao A, et al. Experimental arthritis in CC chemokine receptor 2-null mice closely mimics severe human rheumatoid arthritis. *J Clin Invest* 2004;113(6):856-66.
 21. Palmblad K, Erlandsson-Harris H, Tracey KJ, Andersson U. Dynamics of early synovial cytokine expression in rodent collagen-induced arthritis: a therapeutic study using a macrophage-deactivating compound. *Am J Pathol* 2001; 158(2):491-500.
 22. Pan Y, Neuss S, Leifert A, Fischler M, Wen F, Simon U, et al. Size-dependent cytotoxicity of gold nanoparticles. *Small* 2007;3(11):1941-9.
 23. Takahashi H, Niidome Y, Niidome T, Kaneko K, Kawasaki H, Yamada S. Modification of gold nanorods using phosphatidylcholine to reduce cytotoxicity. *Langmuir* 2006; 22(1):2-5.
 24. Fletcher DS, Widmer WR, Luell S, Christen A, Orevillo C, Shah S, et al. Therapeutic administration of a selective inhibitor of nitric oxide synthase does not ameliorate the chronic inflammation and tissue damage associated with adjuvant-induced arthritis in rats. *J Pharmacol Exp Ther* 1998;284(2):714-21.
 25. Kean WF, Kean IRL. Clinical pharmacology of gold. *Inflammopharm* 2008;16:112-25.
 26. Nel A, Xia T, Mädler L, Li N. Toxic potential of materials at the nanolevel. *Science* 2006;311(5761):622-7.
 27. Connor EE, Mwamuka J, Gole A, Murphy CJ, Wyatt MD. Gold nanoparticles are taken up by human cells but do not cause acute cytotoxicity. *Small* 2005;1(3):325-7.
 28. Hall JB, Dobrovolskaia MA, Patri AK, McNeil SE. Characterization of nanoparticles for therapeutics. *Nanomedicine* 2007;2(6):789-803.

Received 27 September 2011, accepted 28 February 2012