

Gaucher's Disease in Lithuania: Its Diagnosis and Treatment

Grażina Kleinotienė¹, Anna Tylki-Szymanska², Barbara Czartoryska³

¹Center of Oncohematology, Vilnius University Children's Hospital, Lithuania, ²Department of Metabolic Diseases, Endocrinology and Diabetology, The Children's Memorial Health Institute, Warsaw, Poland,

³Department of Genetics, Institute of Psychiatry and Neurology, Warsaw, Poland

Key words: Gaucher's disease; lysosomal storage disease; glucocerebrosidase; hepatosplenomegaly.

Summary. Gaucher's disease is a lysosomal storage disease caused by the lack of beta-glucocerebrosidase enzyme, leading to the accumulation of glucocerebroside. Gaucher's disease is the most frequent type of sphingolipidosis as well as the most frequent lysosomal disease. Clinically, two forms of Gaucher's disease are defined: nonneuronopathic form, so-called type 1, characterized by hepatosplenomegaly, thrombocytopenia, anemia, and osteopenia, and neuronopathic form, known as types 2 and 3, which are also characterized by hepatosplenomegaly, hematological and bone changes; however, involvement of the central nervous system dominates in the clinical picture.

Severe deficiency of beta-glucocerebrosidase activity allows confirming the diagnosis based on the clinical picture or the findings of bone marrow examination.

Treatment with human glucocerebrosidase was introduced in 1991. Clinically good results are achieved: not only accumulation of glucocerebroside is stopped, but also positive changes in the reticuloendothelial system and an improvement in development and hematological parameters of children are observed as well as the development of bone lesions is reduced. To date, Gaucher's disease has been diagnosed in 8 patients in Lithuania: 3 persons have type 3 and 5 have type 1 disease. Enzyme replacement therapy was started in 2001, and currently 6 persons are being treated. In majority of patients, Gaucher's disease was suspected after exclusion of other possible proliferative diseases. All patients within the first or second year of treatment achieved the therapeutic goals, namely: normalization of hematological parameters, reduction in liver and spleen volumes, and bone pain relief.

Introduction

History Outline

Gaucher's disease is a lysosomal storage disease caused by deficiency in the activity of beta-glucocerebrosidase enzyme leading to the accumulation of glucocerebroside. The disease was first described by Phillippe Gaucher in his doctoral dissertation in 1882. Twenty years later, Nathan Brill proved its autosomal recessive inheritance and used Gaucher eponym to name it. In the 1920s, neuronopathic phenotype of the disease was described. In the 1960s, Roscoe Brady established that pathomechanism of Gaucher's disease stems from the deficiency of glucocerebrosidase activity (1).

Pathomechanism

Gaucher's disease is the most frequent type of sphingolipidosis as well as the most frequent lysosomal disease. A deficiency of the lysosomal enzyme beta-glucocerebrosidase, which cleaves glucose from cerebroside under physiological conditions, is the cause of the disease.

Fragments of cells including the pieces of cell membranes containing glucocerebroside are phagocytized by macrophages. Beta-glucocerebrosidase-deficient macrophages loaded with glucocerebroside have a characteristic appearance and are commonly known as foam cells or Gaucher's cells. Until the cause of Gaucher's disease was established, the diagnostic method was a microscopic examination of bone marrow biopsy specimens. Identification of foam cells in bone marrow and characteristic clinical symptoms were the basis of diagnosis of Gaucher's disease.

Currently, the only reliable and acknowledged method is a measurement of beta-glucocerebrosidase activity in blood leukocytes or fibroblasts.

Classification

Clinically, two forms of Gaucher's disease are defined:

- type 1, called also chronic nonneuronopathic type, which is characterized by hepatosplenomegaly, thrombocytopenia, anemia, and osteopenia.

Correspondence to G. Kleinotienė, Center of Oncohematology, Vilnius University Children's Hospital, Santariškių 2, 08661 Vilnius, Lithuania. E-mail: grazinakleinotiene@yahoo.com

Adresas susirašinėti: G. Kleinotienė, Vilniaus universiteto Vaikų ligoninės Hematologijos ir onkologijos centras, Santariškių 2, 08661 Vilnius. El. paštas: grazinakleinotiene@yahoo.com

- types 2 and 3, known as a neuronopathic form, characterized by hepatosplenomegaly, hematologic and osseous changes; however, involvement of the central nervous system with different degree of impairment dominates in the clinical picture.

Involvement of the central nervous system with bulbar symptoms, rapid course, and extremely unfavorable prognosis are characteristic of type 2 (infantile).

Type 3 (juvenile) is characterized by less intense symptoms of the nervous system and much more mild course comparing with type 2. In nonneuronopathic type, the pathological process takes place most intensively in cells stemming from macrophage lines. Residual activity of an enzyme is insufficient to metabolize the substrate originating mainly from cell membranes incoming in large quantities to macrophages. It is accumulated in lysosomes of macrophages leading to their proliferation and change of functions and structure (foam cells).

In the neuronopathic forms, pathological process in nervous system cells has a different course. The substrate originates from gangliosides synthesized in neurons, hence its quantity is much lower. Beta-glucocerebrosidase activity in these forms is on a trace or zero level, insufficient to decompose even tiny amount of glucocerebroside, which accumulates in endoplasmic reticulum. Calcium channels located in endoplasmic reticulum are damaged, leading to neuronal death.

Therefore, the pathomechanism of Gaucher's disease is different in the cells of endoplasmic reticulum than those of the nervous system (2).

Residual activity of the enzyme depends on the type of mutation/change in the gene for beta-glucocerebrosidase. N370S and L444P are the most frequent mutations in the gene for beta-glucocerebrosidase located on chromosome 1q21. The mutation N370S occurs only in the Caucasian population, which may prove the existence of founder effect distant in time. The presence of this mutation even on a single allele ensures the residual activity of the enzyme sufficient for correct catabolism of glucocerebroside in neurons and hence the lack of neurological symptoms. The mutation L444P is panethnic; homozygosity for this mutation leads to neuronopathic form of the disease and occurs in more than 70% of patients.

The frequency of neuronopathic form is estimated to be 1 per 40 000 live births. It occurs much more frequently in the Ashkenazi population, with an incidence being 1 per 1000 live births, where N370S (approx. 57%–70%) and 84GG (10%) are the most frequent mutations (3).

Symptomatology

Gaucher's disease is clinically characterized by hepatomegaly and splenomegaly, incorrect bone

modeling, so-called Erlenmeyer flask shape, osteopenia, and thus the increased risk of pathological fractures, including compression fractures of the vertebra.

Bone pain and bone crises are the most debilitating disease symptoms in adult patients with type 1 Gaucher's disease. Bone involvement is clearly displayed in magnetic resonance examination; bone marrow infiltration by macrophages and changes in proportion of bone marrow fat fraction are observed.

Hematological examination shows the following symptoms characteristic of the disease: anemia and thrombocytopenia, often generalized neutropenia, bleeding disorder, increased ferritin level, and low vitamin B₁₂ level.

Activated macrophages containing accumulated glucocerebroside excrete chitotriosidase. Chitotriosidase activity in serum reflects a measure of glucocerebroside storage in macrophages, being a sensitive marker of treatment effectiveness (4).

In the neuronopathic form, visceral and hematological symptoms are similar as in type 1, though more intense. Characteristic neurological symptoms are oculomotor apraxia in horizontal movement, ataxia, squint, myoclonus, and mental retardation. In the infantile form (type 2), bulbar symptoms and spasticity are most characteristic; life expectancy does not exceed 2 years.

Gaucher's cells can be detected in the spleen, liver, bone marrow, lymph nodes, and rarely in lungs. Infiltration in bone marrow may be focal. Patients with Gaucher's disease much more frequently develop lymphoma (5).

Natural History

The age at onset of first symptoms as well as the rate of their intensification are different in different patients, with the differences possible even between siblings.

If the first symptoms occur during childhood, more severe course of the disease is to be expected. It is assumed that homozygous persons for the N370S mutation may have mild symptoms or not have them at all. The symptoms almost always present in adult patients with type 1 Gaucher's disease are as follows: feeling of exhaustion, weakness, bone pain, increased tendency to bleed (bleeding from the nose, gingiva; subcutaneous effusions, hypermenorrhea), splenomegaly and hepatomegaly; spleen can be enlarged 10 times. Spleen infarctions, pathological fractures, bone necrosis (particularly often affecting hips), anemia, and thrombocytopenia occur frequently. In children, growth retardation and delayed puberty are observed.

Diagnostics

The basis for Gaucher's disease diagnosis is establishment of high deficiency in beta-glucocere-

brosidase activity in leukocytes or fibroblasts. Proving the deficiency of activity allows confirming diagnosis based on clinical picture or findings from examination of bone marrow biopsy specimens.

The measurement of chitotriosidase activity in serum is helpful. In Gaucher's disease, the level of chitotriosidase activity increases more than 4500 times as compared with the reference value. It is a quite specific examination for Gaucher's disease, since in other storage diseases such as Niemann-Pick disease A or B, the chitotriosidase activity level rises but never to such extent. Weaker side of this marker is the fact of frequent occurrence of homozygosity for 24-bp mutation in the Caucasian population, which is estimated to be around 6%–12% (6).

Knowledge of Genotype in Type 1 and 3 Gaucher's Disease

The presence of N370S mutation on a single allele allows the diagnosis of nonneuronopathic form (7). On the other hand, homozygosity for this mutation may indicate mild course of the disease. Identification of foam cells in bone marrow specimens cannot be the basis for the diagnosis of Gaucher's disease, since macrophages in Niemann-Pick's disease have similar morphology. Besides, bone marrow infiltration with macrophages is not even, it is often focused; therefore, it is possible that we "hit" the place, where there are no such cells, and erroneously exclude the disease.

Treatment

For the first time, enzyme replacement therapy in lysosomal diseases has been effectively used on a bigger scale in Gaucher's disease. It was already proposed by Roscoe Brady, but it required the modification of sugar chains so that it contained mannose residue which caused that protein was recognized by macrophage receptors and internalized to lysosomes via active endocytosis.

Treatment with human glucocerebrosidase was introduced in 1991. Clinically, very good results were achieved, based not only on stopping storage process, but also on withdrawing changes in reticuloendothelial system, improvement of development and hematological parameters of children as well as hampering the process of bone lesions increase. Enzymatic therapy is not effective in treatment of neuronopathic form (type 2) of Gaucher's disease, due to the fact that enzyme does not cross the blood-brain barrier.

Other treatment option in Gaucher's disease may be the substrate therapy.

Efficacy of the treatment is assessed on the basis of changes in the clinical picture; the method of "reaching therapeutic goals" is helpful here, which covers especially bone pain relief, reduction of in-

ternal organ volume, normalization of hematological parameters, reduction in serum chitotriosidase activity level and levels of other markers (8, 9).

Lithuanian Patients

To date, Gaucher's disease has been diagnosed in 8 patients in Lithuania: 3 persons have type 3 and 5 have type 1 disease. Enzymatic treatment was started in 2001, and currently 6 persons are being treated. Clinical characteristics of Lithuanian patients are present below.

S.M. is currently 17 years old. He is a first child of healthy parents who do not declare consanguinity, but coming from the same neighborhood. The first symptoms appeared around 18th month of life. These included paleness, enlarged liver and spleen (they reached the navel line), reduced body weight, and squint. Findings of hematological examinations indicated severe anemia (79 g/L) and significant thrombocytopenia ($480 \times 10^9/L$). Initially, leukemia was suspected. Bone marrow examination did not confirm this suspicion. Due to increasing hypersplenism, splenectomy was performed when the boy was 2 years old. Histopathological spleen examinations proved the presence of foam cells (Gaucher's cells). Examination of beta-glucocerebrosidase activity indicated severe deficiency in its activity; Gaucher's disease was finally confirmed. The homozygous L444P mutation was identified, which allowed defining type 3 of the disease.

Enzymatic replacement therapy was started in 2001 when the boy was 8 years old. Ceredase at a dosage of 60 U/kg per 2 weeks was administered, and homological laronidase (Cerezyme®) was given later. After the first year of treatment, an improvement in hemoglobin level was achieved together with reduction in the liver volume and significant reduction in the chitotriosidase activity level from 20 627 to 883 nmol/(mL·h) (reference value, <150) as well as improvement in body weight and height parameters. During the 9-year treatment, somatic and hematological parameters normalized; neurological symptoms have ameliorated and are limited to oculomotor apraxia. However, kyphosis of the thoracic spine and chest deformation continue to progress (Figs. 1–3).

A younger brother of S.M. (T.M.) already in the first year of his life demonstrated symptoms similar to those of older brother: paleness, hepatosplenomegaly, anemia and tendency to develop bruises, and reduced body weight. After diagnosis in older brother, it was also confirmed for T.M. Due to increasing hypersplenism, the spleen of the boy was resected at the age of less than 2 years. Treatment was started when the boy was 8 years old. The dosage of 40 U/kg every 2 weeks was given. After the two-year treatment, the normalization of hemo-



Fig. 1. S.M. before enzyme replacement therapy in 2001



Fig. 2. S.M. during enzyme replacement therapy in 2004

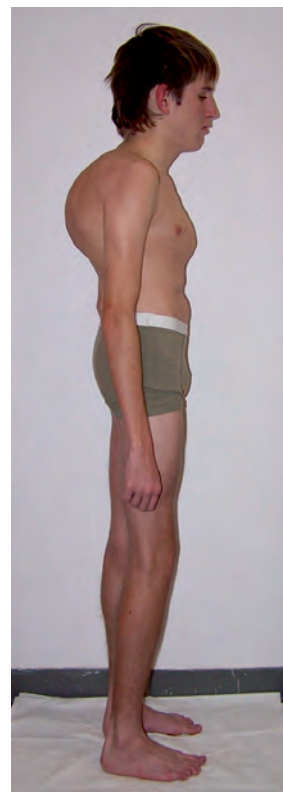


Fig. 3. S.M. during enzyme replacement therapy in 2009

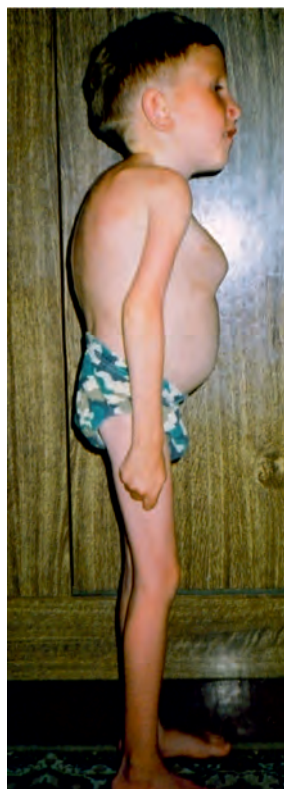

Fig. 4. T.M. before enzyme replacement therapy in 2001

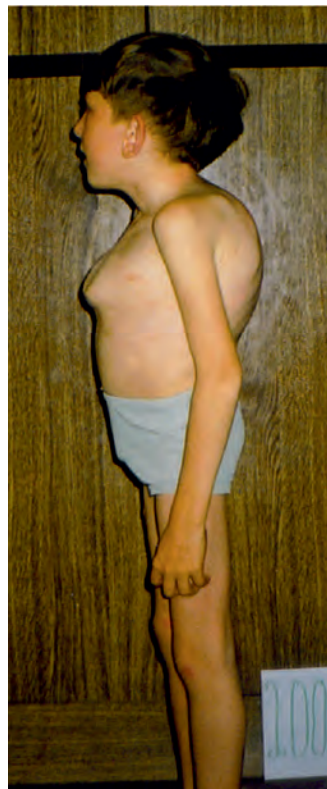

Fig. 5. T.M. during enzyme replacement therapy in 2005

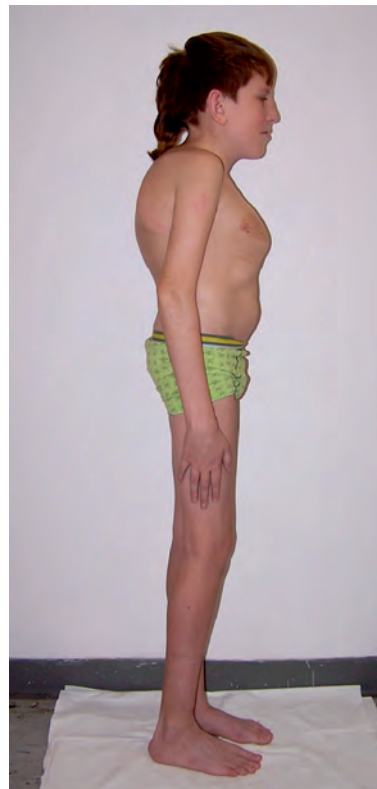


Fig. 6. T.M. during enzyme replacement therapy in 2009

globin level was achieved from 65 g/L to 123 g/L. The chitotriosidase activity level was significantly reduced from 14 894 to 2425 nmol/(mL·h). Currently the boy is developing properly, liver volume has normalized, also the body weight parameters, and even height has improved in spite of significant kyphosis. No neurological deterioration is observed; oculomotor apraxia and strabismus persist (Figs. 4–6).

A full-term girl (A.D.) from the first uncomplicated pregnancy firstly presented with splenomegaly and hepatomegaly. For this reason, she was hospitalized to the Department of Gastroenterology, where anemia (Hb level, 104 g/L) and thrombocytopenia ($57 \times 10^9/L$) were also proved besides hepatosplenomegaly. Besides oculomotor apraxia, squint, ataxia, slight delay in psychomotor development were documented (Fig. 7). The set of symptoms suggested Gaucher's disease, and results of the measurement of beta-glucocerebrosidase activity in leukocytes and chitotriosidase activity clearly confirmed Gaucher's disease. Molecular examination revealed the genotype C721G>/C1448T>C (neuronopathic phenotype). Enzymatic replacement therapy with laronidase at a dosage of 60 U/kg every 2 weeks was administered. During half a year of the therapy, normalization of hematological parameters was achieved together with normalization of spleen and liver volumes. The chitotriosidase activity level was reduced from 13 100 to 1175 nmol/(mL·h). Neurological symptoms persist with seizures refractory to antiepileptic drugs; dysarthria, psychomotor deterioration, and chest deformation continue to progress.

A 40-year-old man (A.V.) was admitted to the oncohematological ward due to symptoms of weakness, feeling of exhaustion, bone pain, hepatosplenomegaly as well as anemia (Hb level, 90 g/L). Lymphoma was suspected, but the examinations did not confirm it. Due to hypersplenism, the spleen was removed. Histological examination of the

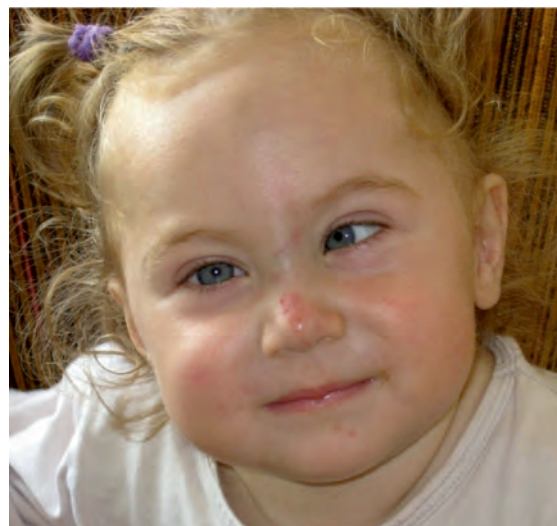

Fig. 7. The patient (A.D.) with oculomotor apraxia

spleen proved the presence of Gaucher's cells. Examinations for beta-glucocerebrosidase activity in fibroblasts were performed; the findings confirmed Gaucher's disease. The chitotriosidase activity level was significantly elevated (9120 nmol/[mL·h]); the N370S/RecNi genotype was identified. The patient displayed pathological fractures; at the age of 45 years, he underwent prosthesis treatment due to osteonecrosis of the coxa. Enzymatic replacement therapy was started when the patient was 54 years old; the dose of 60 U/kg per 2 weeks was administered. After 3 years of treatment, bone pain disappeared, the liver volume was reduced, and the chitotriosidase activity level was reduced to 780 nmol/(mL·h). Currently, the patient is given Cerezyme at a lower dosage (15 U/kg per 2 weeks).

A female patient (A.A.) at the age of 12 years was admitted to the oncohematological ward due to the enlarged spleen (2 cm below the umbilicus) and liver (4 cm below the arch of ribs), low body weight,

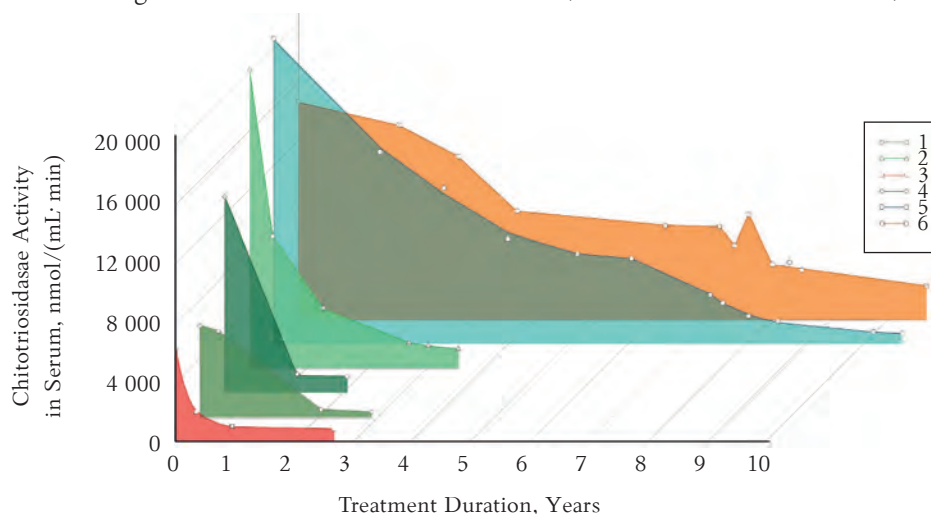


Fig 8. Chitotriosidase activity in serum of patients and duration of treatment

1, patient D.B.; 2, patient A.A.; 3, patient A.V.; 4, patient A.D.; 5, patient S.M.; 6, patient T.M.

anemia (Hb level, 100 g/L), and thrombocytopenia ($69 \times 10^9/L$). Leukemia was suspected, but it was not confirmed; however, examination of bone marrow specimens showed the presence of foam cells. Gaucher's disease was confirmed by the examination of beta-glucocerebrosidase activity in leukocytes. The chitotriosidase activity level was 20 325 nmol/(mL·h). Molecular examination revealed the G202R/V375L mutation (type 1).

After two years of enzymatic therapy, the normalization of hematological parameters (Hb level, 139 g/L; platelet count, $152 \times 10^9/L$) as well as liver and spleen volume was documented. The serum chitotriosidase activity level was reduced to 1333 nmol/(mL·h).

A female patient (D.B.) was hospitalized at the age of 11 due to hepatosplenomegaly, constant feeling of weakness, thrombocytopenia ($90 \times 10^9/L$), and anemia (Hb level, 105 g/L). Due to thrombocytopenia, the spleen was resected when the patient was 17 years old. Histology of the spleen showed typical Gaucher's cells. Afterwards, the disease was confirmed by enzymatic and molecular testing (N370S/128delG). After removal of the spleen, the patient began to feel bone pain. Treatment was begun at the age of 18 years. Normalization of hematological parameters was achieved quickly, though the feeling of exhaustion and bone pain remain.

A 58-year-old male patient (H.N.) underwent splenectomy at the age of 11 years (in 1963) most probably due to thrombocytopenia. At the time, he had already complained of bone pains. Histology of the spleen showed the presence of typical Gaucher's cells. In 2009, Gaucher's disease in the patient was confirmed enzymatically. Currently, the patient complains of severe bone pain. He suffered vascular necrosis of both hips. The chitotriosidase activity level is 40 000 nmol/(mL·h). Genotype is c.1240G>C/c.1448T>C.

A 33-year-old female patient (E.J.) was hospitalized due to vomiting and stomachache in February 2010. Abdominal ultrasound revealed significant hepatosplenomegaly; hematological examination showed anemia (Hb level, 109 g/L) and significant thrombocytopenia ($73 \times 10^9/L$). Thrombocytopenia was first documented 5 years ago, though no further diagnostics was performed at the time.

During the last biopsy, the presence of Gaucher's cells was confirmed. Enzymatic testing revealed a deficiency of beta-glucocerebrosidase, and the chitotriosidase activity level of 10 433 nmol/(mL·h) was determined. Genotype was found to be c.1226A>G/c.1448T>C.

Discussion

To date, 8 patients have been diagnosed with Gaucher's disease in Lithuania. The overall frequency of Gaucher's disease in Europe and United

States is 1 per 40 000 live births. According to such estimations, in Lithuania with 3.5 million inhabitants, there should be around 60 patients. It suggests that many persons might remain undiagnosed. In the majority of our patients, Gaucher's disease was suspected after exclusion of other possible causes of symptoms, such as hepatosplenomegaly, anemia and thrombocytopenia, characteristic of other proliferative diseases. All the patients underwent bone marrow biopsy. In two patients (A.V. and D.B.), no foam cells were detected in bone marrow biopsy specimens. Gaucher's disease was suspected after microscopic examination of the spleen following its resection; later the disease was confirmed enzymatically.

Three most recently diagnosed patients (A.A., A.D., and E.J.) were diagnosed with Gaucher's disease on the enzymatic assay basis, but splenectomy was not performed in these patients. In all of them, shortly after introduction of treatment, spleen and liver volumes normalized, and thrombocytopenia was ameliorated. Three patients with type 1 disease (A.V., D.B., and A.B.) suffered increased bone pain and complications (fractures) after removal of the spleen. Currently, there is a possibility to perform a simple screening test even before bone marrow biopsy. It measures chitotriosidase activity in serum. A significant increase in its level proves the activation of macrophages. Besides, it is a good marker of treatment effectiveness. However, there is no possibility to test beta-glucocerebrosidase or chitotriosidase activity in Lithuania; the tests are being performed abroad, mostly in Warsaw.

Based on the experience on enzymatic treatment of patients with Gaucher's disease gathered in Lithuania, high effectiveness of this treatment may be confirmed not only in patients with type 1 but also with type 3 disease. All patients within the first or second year of treatment achieved what we describe as "therapeutic goals" in Gaucher's disease, namely: normalization of hematological parameters, reduction of liver and spleen volumes, bone pain relief as well as decreased chitotriosidase activity level.

Conclusions

Possibility of Gaucher's disease in patients with enlarged liver and spleen volumes should always be considered in differential diagnostics of onco-hematological and gastrological diseases. Gaucher's disease should always be excluded before taking a decision to perform splenectomy. Examination of bone marrow biopsy specimens is not sufficient or reliable in confirmation or exclusion of Gaucher's disease. Enzyme replacement therapy in patients with Gaucher's provides excellent clinical results, which are reflected in reaching therapeutic goals described above.

Statement of Conflict of Interest

The authors state no conflict of interest.

Gošė liga Lietuvoje: diagnozė ir gydymas

Gražina Kleinotienė¹, Anna Tylki-Szymanska², Barbara Czartoryska³

¹Vilniaus universiteto Vaikų ligoninės Hematologijos ir onkologijos centras, Lietuva,

²Vaikų memorialinio sveikatos centro Metabolinių ligų, endokrinologijos ir diabetologijos skyrius, Varšuva, Lenkija,

³Psichiatrijos ir neurologijos instituto Genetikos skyrius, Varšuva, Lenkija

Raktažodžiai: Gošė liga, lizosominė kaupimosi liga, gliukocerebrozidazė, hepatosplenomegalija.

Santrauka. Gošė yra lizosominė kaupimosi liga, kurią sukelia fermento β -gliukocerebrozidės trūkumas leukocituose. Dėl to retikuloendotelinėje sistemoje kaupiasi gliukocerebrozidas. Gošė liga priklauso sfingolipidozių grupei ir yra dažniausia iš jų. Kliniškai skiriamos dvi Gošė ligos formos: neneuronopatinė (I ligos tipas), kuriai būdinga hepatosplenomegalija, trombocitopenija, anemija ir osteopenija bei neuronopatinė forma (II ir III ligos tipai), kuriai būdinga hepatosplenomegalija, kraujo, kaulų čiulpų pokyčiai ir centrinės nervų sistemos pažeidimai.

Diagnozę patvirtina didelis fermento β -gliukocerebrozidazės trūkumas. Specifinis gydymas donoro gliukocerebrozidaze pasaulyje buvo pradėtas 1991 m. Gydant β -gliukocerebrozidaze (pakaitine fermento terapija), ne tik pristabdomas kaupimosi procesas, bet sukeliami ir teigiami pokyčiai retikuloendotelinėje sistemoje, pagerėja kraujo rodikliai, sumažėja pažeidimų kauluose.

Lietuvoje Gošė liga diagnozuota aštuoniems pacientams. Trims pacientams nustatytas III ligos tipas, penkiems – I tipas. Pakaitinė fermento terapija Lietuvoje pradėta taikyti 2001 m. Šiuo metu gydomi šeši pacientai, sergantys Gošė liga. Daugumai pacientų pradžioje buvo įtartos kitos proliferacinės ligos. Visiems pacientams, taikant pakaitinę fermento terapiją, po 1–2 metų konstatuotas „terapinis efektas“: normalizavosi hematologiniai rodikliai, sumažėjo kepenų ir blužnies apimtis, sumažėjo kaulų skausmai.

References

1. Beutler E, Grabowski G. Glucosylceramide lipidosis: Gaucher disease. In: Scriver CR, Beaudet AL, Sly WS, editors. The metabolic and molecular bases of inherited diseases. McGraw-Hill; 1995. p. 2641–70.
2. Cox T, Schofield J. Gaucher's disease: clinical features and natural history. In: Zimran A, editor. Gaucher's disease. London: W. B. Saunders; 1997. vol 10. p. 657–90.
3. Grabowski G. Gaucher disease: gene frequencies and genotype/phenotype correlations. Genet Test 1997;1:5–12.
4. Hollak CEM, Aerts JMFG. Plasma and metabolic abnormalities in Gaucher disease. In: Zimran A, editor. Gaucher's disease. London: W. B. Saunders; 1997. vol 10. p. 691–709.
5. Tylki-Szymańska A, Czartoryska B, Vanier MT, Poorthuis BJ, Groener JA, Ługowska A, et al. Non-neuronopathic Gaucher disease due to saposin C deficiency. Clin Genet 2007;72(6):538–42.
6. Hollak CE, van Weely S, van Oers MHJ, Aerts JM. Marked elevation of plasma chitotriosidase activity: a novel hallmark of Gaucher disease. J Clin Invest 1994;93:1288–92.
7. Tylki-Szymańska A, Vellodi A, El-Beshlawy A, Cole JA, Kolodny E. Neuronopathic Gaucher disease: demographic and clinical features of 131 patients enrolled in the International Collaborative Gaucher Group Neurological Outcomes Subregistry. J Inherit Metab Dis 2010;33(4):339–46.
8. Vellodi A, Tylki-Szymańska A, Davies EH, Kolodny E, Bembi B, Collin-Histed T, et al. Management of neuronopathic Gaucher disease: revised recommendations. J Inherit Metab Dis 2009;32(5):660–4.
9. Cox TM, Aerts JM, Belmatoug N, Cappellini MD, vom Dahl S, Goldblatt J, et al. Management of non-neuronopathic Gaucher disease with special reference to pregnancy, splenectomy, bisphosphonate therapy, use of biomarkers and bone disease monitoring. J Inherit Metab Dis 2008; 31(3):319–36.

Received 15 November 2010, accepted 27 July 2011

Straipsnis gautas 2010 11 15, priimtas 2011 07 27