

Surgical treatment of metastatic tumors of the femur

Vytautas Toliušis¹, Romas Jonas Kalesinskas¹, Mindaugas Kiudelis²,
Almantas Maleckas², Mindaugas Grikšas¹

¹Department of Orthopedics and Traumatology, Kaunas University of Medicine,

²Department of Surgery, Kaunas University of Medicine, Lithuania

Key words: metastatic bone tumors; pathologic fractures fixation; bone cement; methylmethacrylate.

Summary. *Objective.* To evaluate the patients functional outcome and pain control after resection of metastatic femoral tumors.

Material and methods. A prospective randomized clinical study was conducted, which included 26 cases of metastatic tumors of the femur with an associated pathologic fracture. These selected cases were randomly divided into two groups based upon the using of methylmethacrylate cement in fracture fixation. Group 1 (n=13) included all cases where the fractures were treated with bone cement augmentation. Group 2 (n=13) included all cases where the fractures were treated without bone cement augmentation. Functional outcome was evaluated according the American Musculoskeletal Tumor Society system.

Results. Good and excellent pain control was achieved in 61.5%, satisfactory in 38.5% of all cases in the Group 1 versus 15.5% ($P=0.015$) and 69% ($\chi^2=2.4762$; $P=0.115$) of all cases in the Group 2. Functional outcome after femoral metastasis resection and pathologic fracture fixation was significantly better in the Group 1. Total lower extremity function of full normal function was 67% in the Group 1 versus 49% in the Group 2 ($P<0.05$). We did not observe significant difference between patients' postoperative survival in the groups ($P>0.05$). The postoperative durability of stable pathologic fracture fixation was shorter in the Group 2 (273.9 ± 51.7 vs. 358.9 ± 116.8 days) comparing with Group 1 ($P=0.03$).

Conclusions. The introduction of bone cement as the adjunct to the pathologic femoral fracture fixation significantly improved the clinical our study results: we achieved better functional outcome and better pain control.

Introduction

Femur is the most common site of the bone metastasis after spine and pelvis. From 30 to 50% of metastatic bone lesions are localized in the proximal part of the femur (1–3). In contrast to pathologic fracture of the upper limb, pathologic fracture of the femur adversely acts on patient's quality of life due to pain, loss of lower extremity function, and psychological problems (4–6). Surgery is indicated when the fracture is present. The main goals of surgery are pain reduction and patient's mobility restoration with full weight bearing, psychological improvement, and facilitation of nursing care (7). Healing of pathologic fractures of generally proceeds more slowly than normal. It is impeded by the metastatic tumor and by the side effects of radiation treatment, depends on the histological type of primary tumor (8). Various methods of surgical treatment for pathologic femur fractures are described in the literature (9–15). Classically, a dynamic hip screw combined with curettage and complete defect packing with bone cement is used for the internal

fixation (8). This is a rather simple technique, which preserves the hip joint. On the other hand, surgeons may not have much experience with bone defect packing, particularly around the fixation device. In this case, it is difficult to achieve a stable fixation of pathologic fracture, especially if a large segment of the medial bone is lost (8). Many authors recommended reconstructive intramedullary nails as the best choice of fixation of pathologic fractures because plates and screws are not so strong enough as reconstructive intramedullary nails (11). In order to evaluate the functional outcome and pain control after fixation of pathologic femur fractures with reconstruction and retrograde intramedullary nails with or without bone cement augmentation, we constructed this clinical study. This randomized study is the first clinical experience in cancer patients with pathologic femoral fractures in Lithuania.

Materials and methods

All the patients with radiologically and clinically evident extra-articular pathologic fractures of the

Correspondence to V. Toliušis, Department of Orthopedics and Traumatology, Kaunas University of Medicine, Eivenių 2, 50009 Kaunas, Lithuania. E-mail: toliusisvytautas@gmail.com

Adresas susirašinėti: V. Toliušis, KMU Ortopedijos ir traumatologijos klinika, Eivenių 2, 50009 Kaunas
El. paštas: toliusisvytautas@gmail.com

femur requiring surgery were enrolled in this study. All these patients were citizens of Lithuania, aged 18 years and more, who had normal daily living activities before pathologic fracture had occurred. We did not include the patients with multiple metastatic spine and pelvis lesions, solitary bone metastases, extensive femur destruction with soft tissue involvement, patients with insufficiency of the cardiovascular system and kidney function, and patients with diabetes mellitus and mental disorders. The local Ethics Committee approved the study (No. BE-2-15). Informed consent was obtained from all study participants before surgical treatment.

Eligible patients were randomly (envelope method) divided into two groups. Group 1 (n=13) included cases where the fractures were treated with bone cement augmentation and intralesional or marginal resection of metastases. Group 2 (n=13) included cases where fractures were treated without bone cement augmentation with intralesional resection of metastases.

Standard two-direction plain x-ray and computed tomography (CT) of the injured region of the entire femur were performed for all patients preoperatively. A licensed radiologist made radiological analysis. Special attention was paid to the assessment of the extent of tumor involvement and its relation to the femoral nerves and vessels. Bone scintigraphy was performed to detect other skeletal metastases. Selective arterial metastatic lesion embolization was performed one day before surgery in patients with metastatic renal cell carcinoma. Hemoglobin level, size of a metastatic lesion in the injured bone, Karnofsky performance index, number of diagnosed chronic diseases, and ASA group were recorded before the surgery. Hemoglobin level as a prognostic factor was assessed during the hospitalization (16). The size of metastatic lesions was measured in centimeters and assessed from two-plane x-ray or CT.

A rehabilitation specialist assessed the Karnofsky performance index, which illustrates the patients' self-care. According to this index, three groups can be defined: the first group, Karnofsky performance index of 80–100 points (normal activity); the second group, 50–70 points (needs assistance); and the third group, Karnofsky performance index of 0–40 points (needs nursing) (17).

Fixation of metastatic pathologic femoral fractures was done in two stages: tumor resection and reconstruction. Open reduction and bone fixation was performed in both groups of patients during surgery. Surgical treatment consisted of reconstruction-type intramedullary locked nailing (IM). We used carefully sized (ChM, Poland) 11-mm diameter no reamed antegrade insertion reconstruction-type intramedullary locked nails for the fixation of subtrochanteric and diaphyseal pathologic fractures

and (ChM, Poland) 11-mm diameter retrograde insertion no reamed intramedullary locked femoral nails for the fixation of pathologic fracture located in the distal part of the femoral diaphysis. The surgical technique was the same as we used for surgical treatment of trauma patients, except that resection of tumor before the fixation (insertion of an intramedullary nail) must be done (11). Resected bone segment was 0.5 cm longer than approved in radiological analysis. Fixation was considered as stable for a reconstruction nail if two interlocking screws 6.5 mm in diameter were placed into the head and neck region proximally and two interlocking screws 4.5 mm in diameter were placed transversally through the nail distally. Fixation was considered as stable for a retrograde femoral nail if two screws 6.5 mm in diameter distally and two screws 4.5 mm in diameter proximally were used for intramedullary nail fixation. The formation of osteolytic zone around the proximal and distal interlocking screws, radiologically evident broken screws, nails or their migration were evaluated as unstable fixation of pathologic fracture and considered fixation failure. For augmentation, high-viscosity DePuy CMW gentamicin bone cement (Johnson & Johnson United Kingdom) was used (40 g of bone cement dose has 1 g of gentamycin). Duration of the surgery was measured from the moment of the exposition of pathologic fracture zone to the end of fixation. Time from the dermal incision to the exposition of pathologic fracture zone and time from the fracture fixation to the incision suturing were not assessed (13–15).

Preoperative and postoperative antibiotic therapy with the second-generation cephalosporins was performed intravenously. Passive rehabilitation program was applied on the second postoperative day. No additional immobilization was used after surgery. The patients, according to the histological type of the tumor, were treated with radiotherapy using 3000–3500-Gy external beam radiation. Adjuvant chemotherapy and immunotherapy were given according to the treatment protocol.

All the patients were followed up to their death and were evaluated every three months. Physical examination, plain x-rays, evaluation of changes in entire leg function were performed during each visit. Two licensed orthopedic surgeons independently evaluated the function in all 26 patients, enrolled into the study, according to the American Musculoskeletal Tumor Society system (18). Pain, function, emotional acceptance, use of walking aids, gait, and walking were evaluated. The score is expressed as its numerical value or as the percentage of the maximum possible score. When surgeons' opinions regarding the score were different, the lowest score was chosen.

Statistical analysis. The data were processed using the Statistica v5 for Windows package. The absolute numbers (N), percentage (%), mean values with standard deviation are presented in this study. The study sample size was estimated in the pilot study comparing mean scores and their standard deviations (American Musculoskeletal Tumor Society system scale). We chose the research power $\beta=0.9$, confidence level $\alpha=0.05$. The representative sample size was 11 patients in each group. Statistical analysis included nonparametric tests: Mann-Whitney *U* test for comparing two independent samples and Wilcoxon test for comparing two related samples; Fisher exact test was used for the small number of cases. Patients' survival after surgery and the term of stable fixation of pathologic fracture was evaluated according to the Kaplan-Meier method. A *P* value less than 0.05 was considered significant.

Results

During the period of 2004–2008 years, 34 patients with pathologic fractures of the femur were included into the study. Eight patients died before the first evaluation. They survived less than three months after surgery and were excluded from the study. The survival rate was 18.7% in the Group 1 and 27.7% in the Group 2 ($P=0.67$). We did not observe any significant difference mortality rate in early postoperative period comparing both the groups.

The groups were similar regarding age, body mass index, number of chronic diseases at the time of surgery, ASA score, Karnofsky performance index (Table 1). Kidney and breast cancer were the most common sources of femoral metastases.

Retrograde nails were used for the fixation of pathologic fractures, which were located in the distal part of the femur: 38.5% in the Group 1 and 30.7% in the Group 2 ($P=0.69$). Reconstruction-type nails were used for the fixation of pathological fractures of the femoral shaft: 61.5% in the Group 1 versus 69.3% in the Group 2 ($P=0.68$). The overall failure rate was 30% in the Group 1 and 53% in the Group 2 ($P=0.25$). Failures due to local tumor pro-

gression accounted for 7.6% of cases in the Group 1 versus 15.3% in the Group 2 ($P=0.55$); 23% of failures occurred due to the migration or breakage of the interlocking screws in the Group 1 vs. 38% in the Group 2 ($P=0.41$). The mean operative time was 136.9 ± 30.3 min in the Group 1 and 108 ± 12.5 min in the Group 2 ($P=0.007$). Hospital stay was 12.2 ± 4.3 days for the Group 1 versus 11.2 ± 4.8 days for the Group 2 ($P=0.55$).

Excellent and good pain control was achieved in 61.5% of patients, satisfactory in 38.5% of patients in the Group 1 versus 15.5% ($P=0.015$) and 69% ($P=0.115$) of patients in the Group 2. There were no significant differences comparing functional criteria within the groups after 3 and 6 months postoperatively (Table 2). Significant differences in pain control, function, emotional acceptance, use of walking aids, gait, and walking were seen comparing the groups after 3 and 6 months postoperatively. According to the American Musculoskeletal Tumor system, the mean functional score for both the groups was 16.3 ± 3.5 at 3 months and 17.1 ± 3.4 at 6 months after surgery (Table 2).

Functional outcome after resection of femoral metastases and fixation of pathological fracture was significantly better in the Group 1. The patients in the Group 1 had a score of 19.1 ± 2.6 versus 13.6 ± 1.7 in the Group 2 at 3 months after surgery ($P<0.05$) and 20.1 ± 1.6 versus 14.8 ± 1.5 , respectively, at 6 months after surgery ($P<0.05$). The median postoperative survival was 450.6 ± 259 days in the Group 1 vs. 365.8 ± 147 days in the Group 2 ($P=0.25$). Durability of stable fixation of pathologic fracture was significantly lower in the Group 2 (Fig. 1).

Discussion

Pathological fracture of the femur is a serious complication for cancer patients. Complete loss of bone integrity due to metastatic lesion usually causes considerable complications, including pain and impaired mobility. Apart of this, cancer progression leads to multiple complications, which impact overall health condition (19). Taking into account these considera-

Table 1. General characteristics of patients

Characteristic	Groups		<i>P</i> value
	Group 1 (n=13) Mean (SD)	Group 2 (n=13) Mean (SD)	
Age, years	59.7 (8.4)	61.8 (9.9)	0.53
Karnofsky index, %	47.6 (7.2)	44.6 (7.7)	0.21
Hemoglobin level, g/L	115.6 (6.8)	112 (14.9)	0.08
Metastatic lesion size, cm	2.2 (0.23)	2.26 (0.24)	0.46
Body mass index, kg/m ²	29.1 (6.2)	30.2 (7.4)	0.91
ASA score	3.0 (0.7)	2.69 (0.85)	0.41
Number of coexisting diseases	2.54 (1.39)	2.38 (1.55)	0.68

Table 2. Functional criteria and Karnofsky performance index at 3 and 6 months after surgery

Criterion	Evaluation time		P value
	At 3 months	At 6 months	
Pain, score			
Group 1 (n=13)	3.69 (0.6)	3.85 (0.5)	0.15
Group 2 (n=13)	3.0 (0.5)	3.15 (0.3)	0.15
Function, score			
Group 1 (n=13)	2.85 (0.8)	3.08 (0.6)	0.08
Group 2 (n=13)	2.15 (0.5)	2.46 (0.6)	0.1
Emotional acceptance, score			
Group 1 (n=13)	3.62 (0.5)	3.77 (0.5)	0.15
Group 2 (n=13)	2.54 (0.6)	2.85 (0.5)	0.1
Use of walking aids, score			
Group 1 (n=13)	2.69 (1.2)	2.85 (1.3)	0.15
Group 2 (n=13)	1.46 (0.6)	1.62 (0.6)	0.15
Walking, score			
Group 1 (n=13)	3.15 (0.5)	3.46 (0.5)	0.1
Group 2 (n=13)	2.69 (0.4)	2.23 (0.7)	0.1
Gait, score			
Group 1 (n=13)	3.15 (0.5)	3.15 (0.5)	1.0
Group 2 (n=13)	1.77 (0.5)	1.85 (0.5)	0.31
Karnofsky performance index, score			
Group 1 (n=13)	75.3 (8.7)	88.4 (8.0)	0.001
Group 2 (n=13)	64.6 (6.6)	73.0 (6.3)	0.001

Values are presented as mean (SD).

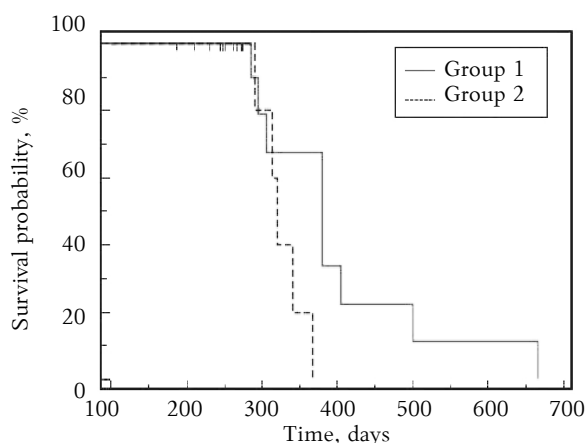


Fig. Durability of stable fixation of pathologic fractures in the groups by Kaplan-Meier curves

tions, the main goals of surgery are to restore the function of entire lower limb (full and unrestricted weight bearing) and to achieve good pain control as soon as possible. Considering that survival of cancer patients varies from a few weeks to many years, the recovery after surgery should be shorter than the expected survival (20). It is very important to choose an adequate implant and to achieve a stable fixation during surgery in order to ensure the successful outcome after surgery for pathologic femoral fracture. The implant must be sufficiently strong to withstand

the biomechanical forces of ambulation and motion. A strong implant protects the patient from significant loss in functional capacity postoperatively and fixation failure that may require second, more extensive surgical procedure. We support senior authors who recommend that all femoral lesions amenable to intramedullary fixation should be treated with reconstruction nails with interlocking screws placed into the femur head and neck through the distal femur transversely to provide resistance to torsional and angular displacement throughout the full length of the femur including the intertrochanteric region and femoral neck (11). We did not use plates and screws for fixation, because they stabilize the bone under the plate and biomechanically they are not as strong as intramedullary nails and can cause early fixation failure especially for patients with longer survival prognosis (11). The standard intramedullary locked nailing was not used in our study because it does not provide protection of the femoral neck or intertrochanteric area, which are the most common sites for metastatic involvement of the femur (21, 22). In the study by Maccauro et al., magnetic resonance imaging revealed that lesion in femoral bone was never isolated (14). Taking into account these considerations, intramedullary nailing should be considered the gold standard for patients with femoral fractures due to metastases (13).

Mortality rate within the first months after surgery in our study did not differ significantly from the mortality rate described in literature (14).

Duration of surgery varies from 80 to 150 minutes (13, 14). We observed significantly longer time in surgery for the Group 1, where osteosynthesis with bone cement was performed. We think that longer time in surgery was due to intramedullar bone cementing and bone cement polymerization. Time in surgery in both the groups was similar to the time reported in literature (9, 10, 13).

Patients' survival after surgery for pathologic femoral fracture is 10.3 months (14) and it differs from survival after surgery for imminent pathologic femoral fracture, where its average is 16.2 months (14). We observed slightly greater survival rate in our study: 87% of patients survived 89.1 months after surgery. Results of other study demonstrated (15) that postoperative survival rate was did not depend on extent and time of surgery and mostly depended on morphological type of cancer. Considering this, all data should be considered critically.

Time for stable fixation of implants varies from 12 to 52 months as described in the literature (14). In our study, stable fixation time was 9–11 months. This time was significantly longer in the Group 1, where bone cement as the adjunct to the fixation of pathologic femoral fracture was used.

One of our study goals was to evaluate patients' functional outcome and pain control after resection of femoral metastases. In the case of pathologic fracture, loss of mechanical bone integrity, soft tissue injury around the fracture zone, and local spread of tumors cause the pain and functional insufficiency of injured extremity. Considering this, it is very important to remove the metastatic tumor and to achieve the stable fixation of pathological fracture during the surgery. Various retrospective studies re-

ported that excellent and good pain control results could be achieved in 50–80% of operated patients after fixation of pathologic fracture (10, 14, 19). The results of our study demonstrate that significantly better pain control was achieved in the Group 1. Function is the main factor, assessing the efficacy of surgery for pathological femoral fractures. Talbot et al. (19) in their prospective study described the significant improvements in the functional score (MSTS) at 6 and 12 weeks postoperatively. They reported that the preoperative MSTS score improved from 7.9 ± 7.5 to 14.4 ± 5.8 points at 6 weeks ($P=0.00016$) and to 17.5 ± 6.9 points at 12 weeks after surgery ($P=0.0001$).

In our study, we observed functional improvements at 3 and 6 months after surgery too. On the other hand, the improvement, comparing the changes in total scores within the groups, was not significant, but we observed significant changes comparing total scores between the groups. The total function was 67% of full normal lower extremity function in the Group 1 versus 49% of full normal lower extremity function in the Group 2 ($P<0.05$). Better postoperative results were observed in the Group 1, where bone cement for fixation of pathologic fracture was used. In our opinion, better postoperative results in this group were achieved because of more stable fixation of pathologic fracture during the surgery. It augments structural stability and enables the patient withstand the stress of immediate motion and function.

Conclusion

Introduction of bone cement as the adjunct to the fixation of pathologic fracture of the femur significantly improved the clinical results of our study: better functional outcome and better pain control were achieved.

Šlaunikaulio metastazinių navikų chirurginis gydymas

Vytautas Toliušis¹, Romas Jonas Kalesinskas¹, Mindaugas Kiudelis²,
Almantas Maleckas², Mindaugas Grikšas¹

¹Kauno medicinos universiteto Ortopedijos ir traumatologijos klinika, ²Chirurgijos klinika

Raktažodžiai: kaulų metastaziniai navikai, patologiniai kaulų lūžiai, patologinių lūžių osteosintezė, kaulų cementas, metilmetakrilatas.

Santrauka. *Tyrimo tikslas.* Įvertinti operuotos kojos funkcijos atsikūrimo visavertiškumą ir skausminio sindromo kontrolę po šlaunikaulio metastazinio židinio rezekcijos ir fiksacijos.

Tyrimo medžiaga ir metodai. Atlikta atsitiktinių imčių perspektyvioji klinikinė studija, kurioje dalyvavo 26 onkologine liga sergantys pacientai, kuriems diagnozuotas šlaunikaulio nesąnarinis patologinis lūžis. Tiriamieji atsitiktinės atrankos būdu suskirstyti į dvi tiriamąsias grupes. Pirmosios grupės tiriamiesiems patologinio šlaunikaulio lūžio fiksacijai naudotas kaulų cementas, antrosios grupės tiriamiesiems kaulų cementas nenaudotas. Operuotos galūnės funkcijos atsikūrimo laipsnis vertintas vadovaujantis Amerikos judėjimo ir atramos aparato navikų draugijos vertinimo sistemos skale.

Rezultatai. Pirmojoje grupėje gera ir puiki skausmo kontrolė konstatuota 61,5 proc. atvejų, patenkinama – 38,5 proc. atvejų; antrojoje grupėje gera ir puiki skausmo kontrolė konstatuota 15,5 proc. atvejų ($p=0,015$), o patenkinama skausmo kontrolė – 69 proc. atvejų ($p=0,115$). Pirmojoje grupėje pastebėtas statistiškai reikšmingai geresnis operuotos galūnės funkcijos atsikūrimas. Šioje grupėje vidutinis operuotos kojos funkcijos atsikūrimas sudarė 67 proc., o antrojoje grupėje – 49 proc. normalios galūnės funkcijos ($p<0,05$). Pacientų pooperacinis išgyvenamumas tarp grupių statistiškai reikšmingai nesiskyrė ($p=0,25$). Stabilios pataloginio lūžio fiksacijos trukmė ilgesnė buvo pirmojoje grupėje ($358,9\pm116,8$ dienos) lyginant su antrąja grupe ($273,9\pm51,7$ dienos) ($p=0,03$).

Išvados. Kaulų cemento panaudojimas pataloginių šlaunikaulio lūžių fiksacijai užtikrina geresnį operuotos galūnės funkcijos atsikūrimo visavertiškumą ir efektyvesnę skausminio sindromo kontrolę.

References

1. Broos PLO, Rommens PM, Vanlangenaker MJU. Pathological fractures of the femur: improvement of quality of life after surgical treatment. Arch Orthop Trauma Surg 1992;111:73-7.
2. Habermann ET, Sachs R, Stern RE, Hirsh DM, Anderson WJ. The pathology and treatment of metastatic disease of the femur. Clin Orthop 1982;169:70-81.
3. Harrington KD. Orthopaedic management of extremity and pelvic lesions. Clin Orthop 1995;312:136-47.
4. Dijkstra S, Wiggers T, Geel BTV, Boxma H. Impending and actual pathological fractures in patients with bone metastases of long bones. Eur J Surg 1994;160:535-42.
5. Tillman RM. Oncological awareness in orthopaedic trauma. Injury 2002;33:741.
6. Weikert DR, Schwartz HS. Intramedullary nailing for impending pathological subtrochanteric fractures. J Bone Joint Surg Br 1991;73:668-70.
7. Kunec JR, Lewis RJ. Closed intramedullary rodding of pathologic fractures with supplemental cement. Clin Orthop Relat Res 1984;(188):183-6.
8. Damron TA, Sim FH. Surgical treatment for metastatic disease of the pelvis and the proximal end of the femur. Instr Course Lect 2000;49:461-70.
9. Kristy L. Weber, Randall RL, Grossman S, Parvizi J. Management of lower-extremity bone metastasis. J Bone Joint Surg 2006;88:11-9.
10. Ward WG, Holsenbeck S, Dorey FJ, Spang J, Howe D. Metastatic disease of the femur: surgical treatment. Clin Orthop Relat Res 2003;(415 Suppl):S230-44.
11. Ward WG. Orthopaedic oncology for the nononcologist orthopaedist: introduction and common errors to avoid. Instr Course Lect 1999;48:577-86.
12. Ward WG, Spang J, Howe D, Gordan S. Femoral recon nails for metastatic disease: indications, technique, and results. Am J Orthop (Belle Mead NJ) 2000;29(9 Suppl):34-42.
13. Maccauro G, Muratori F, Francesco L, Ross B, Logroscino CA. Anterograde femoral nail for the treatment of femoral metastases. Eur J Orthop Surg Traumatol 2008;18:509-13.
14. Maccauro GF, Muratori F, Liuzza A, Sgambato A, Leone A, Cianfoni MA, et al. Long proximal femoral nail for the treatment of femoral metastases: a report of 27 cases. Eur J Orthop Surg Traumatol 2005;15:289-94.
15. Sharma H, Bhagat S, McCaul J, MacDonald D, Rana B, Naik M. Intramedullary nailing for pathological femoral fractures. J Orthop Surg 2007;15(3):291-4.
16. Wedin R. Surgical treatment for pathologic fracture. Acta Orthop Scand Suppl 2001;72(302):2p.,1-29.
17. Taylor AE, Olver IN, Sivanthan T, Chi M, Pumell C. Observer error in grading performance status in cancer patients. Support Care Cancer 1999;7:332-5.
18. Enneking WF, Dunham W, Gebhardt MC, Malawar M, Pritchard DJ. A system for the functional evaluation of reconstructive procedures after surgical treatment of tumors of the musculoskeletal system. Clin Orthop 1993;286:241-6.
19. Talbot M, Turcotte RE, Isler M, Normandin D, Iannuzzi D, Downer P. Function and health status in surgically treated bone metastases. Clin Orthop Rel Res 2005;438:215-20.
20. Coleman RE. Skeletal complications of malignancy. Cancer 1997;80(8 Suppl):1588-94.
21. Levy RN, Sherry HS, Siffert RS. Surgical management of metastatic disease of bone at the hip. Clin Orthop 1982;169:62-9.
22. Wilkins RM, Sim FH, Springfield DS. Metastatic disease of the femur. Orthopedics 1992;15:621-30.

Received 30 January 2009, accepted 7 May 2010

Straipsnis gautas 2009 01 30, priimtas 2010 05 07