

Radiological changes after Nuss operation for pectus excavatum

Artūras Kilda, Saulius Lukoševičius¹, Vidmantas Barauskas,
Živilė Jankauskaitė, Algidas Basevičius¹

Department of Pediatric Surgery,

¹Department of Radiology, Kaunas University of Medicine, Lithuania

Key words: pectus excavatum; Nuss operation; radiological evaluation; postoperative results.

Summary. The objective of this study was to evaluate sternovertebral distance and the chest wall deformation after Nuss procedure.

Materials and methods. Anteroposterior and lateral chest radiographs were performed before Nuss procedure, 1, 6, and 12 months after operation and finally 1 month after bar removal. Sternovertebral distance and transversal chest dimension were measured on radiographs, as well as Haller and vertebral indexes were calculated.

Results. A total of 84 children with funnel chest were operated on. Preoperative sternovertebral distance was 79.81 ± 6.96 mm; 1 month after operation, 97.84 ± 17.08 mm; 6 months, 110.55 ± 13.85 mm; and 12 months, 113.6 ± 14.61 mm. After removal of the bar, the distance was 105 ± 11.95 mm. The mean increase in sternovertebral distance during the first month was 18 mm ($P < 0.0001$); 1–6 months, 12.8 mm ($P = 0.0006$); and 6–12 months, 3 mm ($P = 0.48$). The mean decrease in sternovertebral distance after removal of the bar was 8.6 mm ($P = 0.47$). The decrease in transversal chest dimension during the first month was significant (13.3 ± 12.86 mm, $P = 0.012$).

Conclusions. The sternovertebral distance was significantly increased after Nuss operation. Restoration of deformation proceeds during all the first year after operation. The dynamics of deformation is better depicted by means of vertebral index rather than Haller index.

Introduction

The first surgical corrections of pectus excavatum after 10 years of experience were described by Nuss in 1997 (1). The method of surgical correction proposed by Nuss is widely accepted as the “golden standard” for surgical repair of pectus excavatum. In earlier decades, there was some suspicion concerning early and long-term results (2–5). But at present, when authors report results of studies of hundreds of operated patients, there is no doubt that Nuss operation is widely spread all over the world (1, 3, 6–8).

Early results and postoperative complications are described in numerous publications in detail: vascular, pericardial injuries, even heart affection, residual pneumothorax, etc. (9–11). Postoperative pleuritis, allergy to steel, to suppuration are also mentioned (11–13). However, there is a lack of interpretation of long-term results. Quite often long-term results are briefly described as excellent, good, fair, and failed (1).

In our study, we attempted to evaluate quantitatively the deformation of chest after removal of supporting Lorenz bar. Moreover, based on the postoperative follow-up data, we tried to evaluate the

changes in the main radiological indices of deformation during the period with the Lorenz bar in situ.

Materials and methods

A total of 84 patients underwent Nuss operation in the Department of Pediatric Surgery, Hospital of Kaunas University of Medicine, during the period of 2003–2005. During the repair, a previously shaped Lorenz bar was introduced from the right side of the chest under thoracoscopic control. Afterwards, the bar was fixed with one lateral transverse stabilizer on the right side by means of nonabsorbable suture (Ethibond 2/0, Johnson and Johnson).

Informed consent was obtained from patients or their representatives; all the procedures were carried out in accordance with the ethical standards of the University and with the Helsinki Declaration of 1975, revised in 2000.

Analysis of the data of radiological evaluation of all 84 children was performed. Radiological evaluation and follow-up was performed in the Department of Radiology of the University Hospital. Before surgical repair, anteroposterior (AP) and lateral projec-

tion (LP) radiographs were performed. Postoperative evaluation was performed in the same way, accomplishing radiographic examination at 1, 6, and 12 months after operation. In addition, we performed radiological evaluation 1 month after removal of the bar in order to avoid errors due to early postoperative changes. Usually the bar is removed after a 2-year period on the average.

A regular viewing-box and a ferule, calibrated to 1-mm accuracy, were used to evaluate radiographs. On the LP radiograph, sternovertebral distance (the shortest distance from the sternal inner surface to the anterior surface of the body of the closest vertebra) (SV) and vertebral body length (the distance of the mentioned closest vertebral body beneath pedunculus vertebrae from anterior to posterior surface) (VL) were measured (Fig. 1). The longest transverse distance between the inner costal surfaces on the AP radiographs (transversal chest dimension) was measured as well.

The following deformation indices were calculated:

Haller index (HI) = transversal chest dimension / sternovertebral distance,

$$\text{vertebral index (VI)} = \frac{v}{v+c} \times 100,$$

where *v* indicates vertebral body length, and *c* indicates sternovertebral distance.

Statistical analysis was performed by applying “Statistica 6.0” software. Mean values were compared by the method for independent samples, according to the Student *t* method. Preoperative and postoperative results were assessed analyzing the Student *t* criterion for dependent samples. The difference was considered significant when *P* value was <0.05.

Results

Radiographic data of 84 children treated by Nuss operation were evaluated. All children were examined after 1 month, 76 after 6 months, 56 after 12 months following operation. The Lorenz bar was removed in 30 children. In the latter group of 30 children, the preoperative and postoperative HI was 3.58 ± 0.9 and 2.61 ± 0.26 , respectively ($P=0.0008$). There was no significant difference comparing these groups in regard to age, deformation degree before operation, concomitant pathology, i.e. groups were homogeneous.

The dynamics of changes in main indices was evaluated. No significant differences in VL during the 2-year period were recorded (Fig. 2).

Meanwhile, there was a decrease in transversal chest dimension during the first postoperative month; after 6 months, it reached the preoperative level and

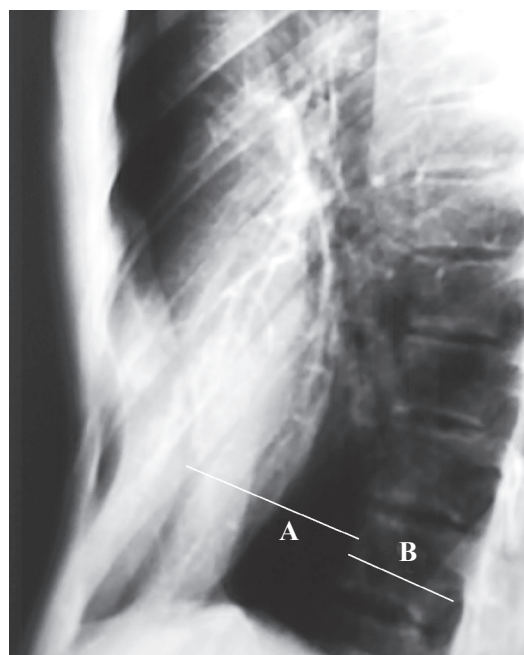


Fig. 1. Lateral projection radiograph

A – sternovertebral distance, B – vertebral body length.

remained constant afterwards (Fig. 3).

The decrease in transversal chest dimension during the first month was significant (13.3 ± 12.86 mm, $P=0.012$).

The preoperative SV was 79.81 ± 6.96 mm, 1 month after operation – 97.84 ± 17.08 mm, 6 months – 110.55 ± 13.85 mm, and 12 months – 113.6 ± 14.61 mm. After the bar removal, the distance remained 105 ± 11.95 mm (Fig. 4).

The mean increase in SV during the first month was 18 mm ($P<0.0001$), during 1–6 months – 12.8 mm ($P=0.0006$), and 6–12 months – 3 mm ($P=0.48$). The mean decrease in the distance after removal of the bar was 8.6 mm ($P=0.47$).

VI decreased rapidly during the first year; later the decrease was not significant (Fig. 5). The mean increase in VI after removal of the bar was 1.25 ± 0.84 ($P=0.062$).

The changes in HI were similar to those of vertebral index (Fig. 6), while percentage change in HI during the first month is greater than in VI (Fig. 7). Due to insufficient sample size, this difference was not significant ($P=0.071$). The presumed cause of the latter could be the decrease in transversal chest dimension during the first month after operation.

Discussion

Nuss operation is considered as the first-choice method of treatment of pectus excavatum. We can agree with the majority of authors that this is a mini-

mally invasive, relatively simple method with a few complications during operation and early postoperative period. Cosmetic appearance is improved immediately. Long-term results are also good. However, in evaluation of long-term results, the majority of authors are not precise the same way as evaluating the deformation before surgical repair. Nuss described results of his operation 1 year after removal of the bar as

excellent in 78.5%, good in 13.1%, satisfactory in 4.7%, and failed in 3.7% of cases (1).

However, there is a lack of quantitative evaluation of chest deformation indexes as such. Similar results are presented by Bohosiewicz et al. Good results were achieved in 24 cases after removal of the bar, one patient developed recurrence (14), but no evaluation of deformation indexes was performed. Several

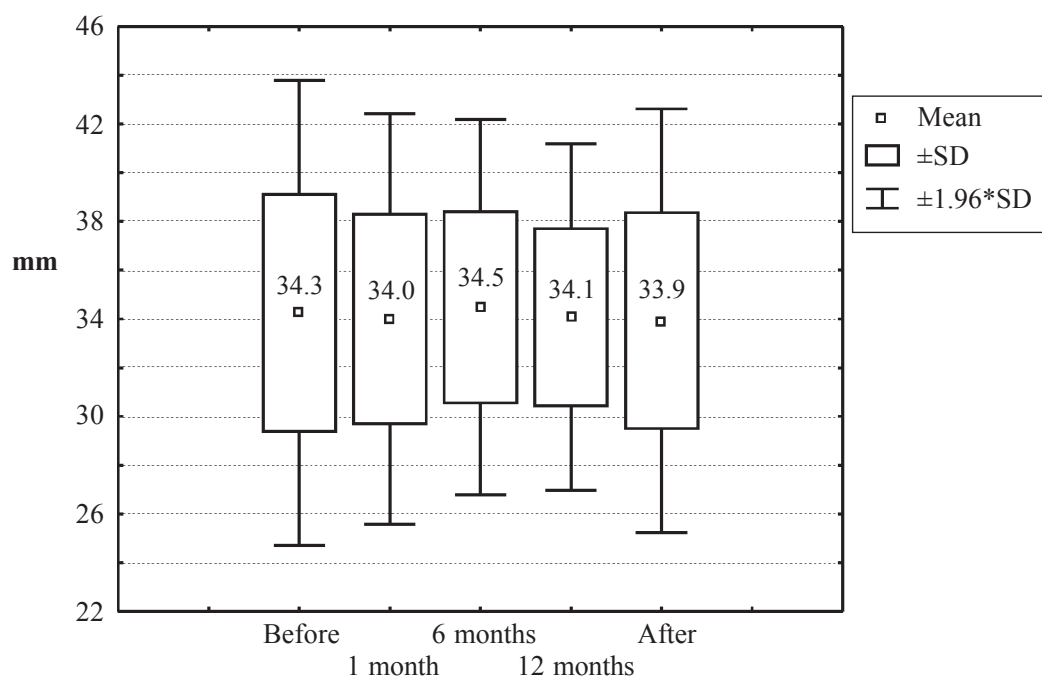


Fig. 2. Changes in vertebral body length (box-and-whisker plot)

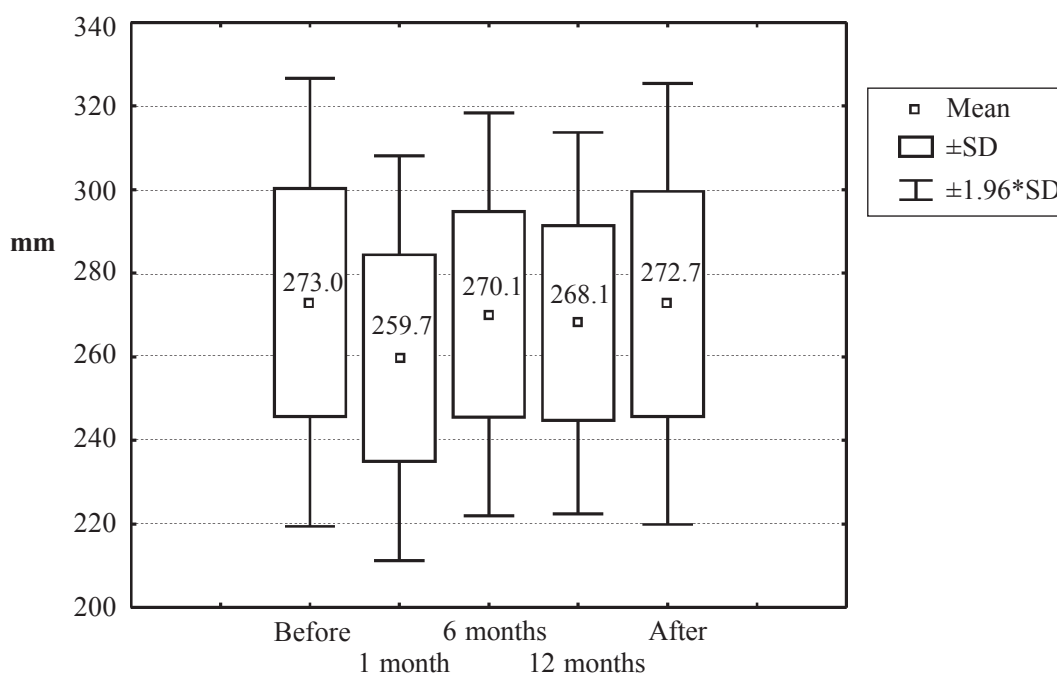


Fig. 3. Changes in transversal chest dimension (box-and-whisker plot)

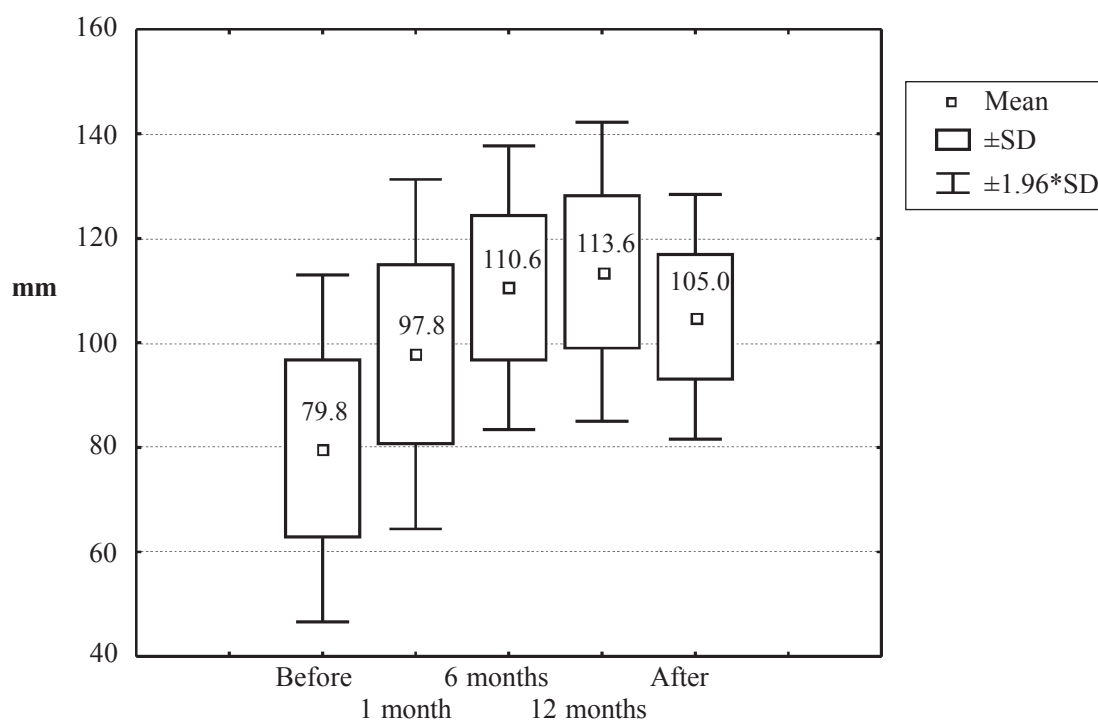


Fig. 4. Changes in sternovertebral distance (box-and-whisker plot)

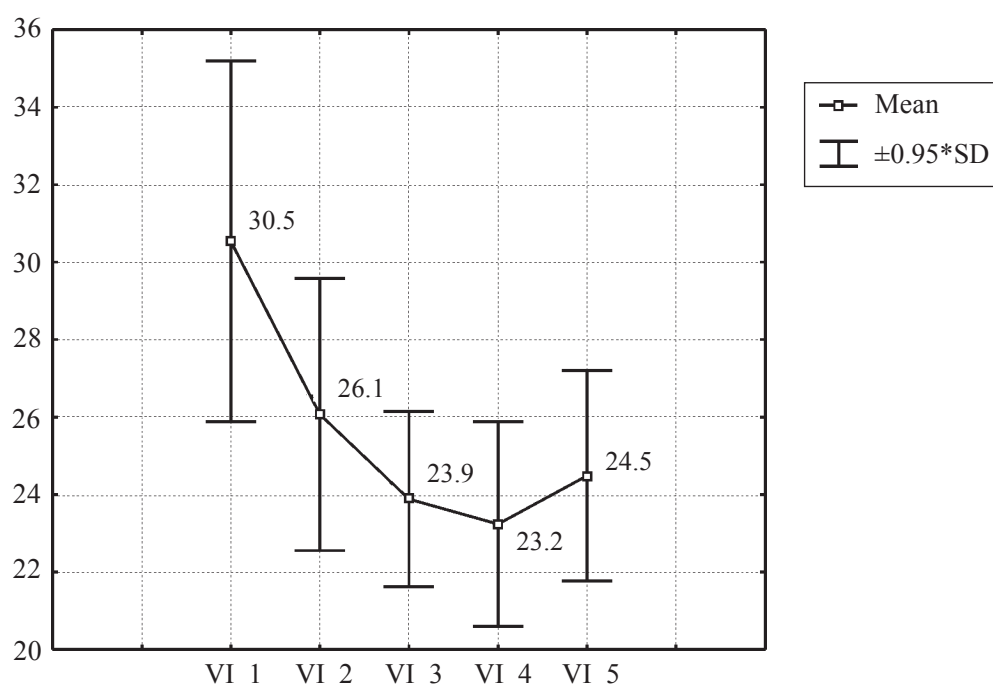


Fig. 5. Changes in vertebral index (mean plot)

VI_1, VI_2, VI_3, VI_4, VI_5 – evaluation of vertebral index (VI) before operation, 1, 6, and 12 months after operation and after removal of the bar, respectively.

authors presented quite similar results as well (3, 7, 8). We evaluated the changes in deformation indexes after removal of the bar and detected that HI decreased significantly from 3.58 to 2.61. Of course, the most common indication for surgical repair of pectus

excavatum is cosmetic (1, 3, 7, 15–20); consequently, the evaluation of treatment means the evaluation of improvement in cosmetic appearance.

Other goal of our study was to evaluate the changes in chest shape after the operation. We failed to find

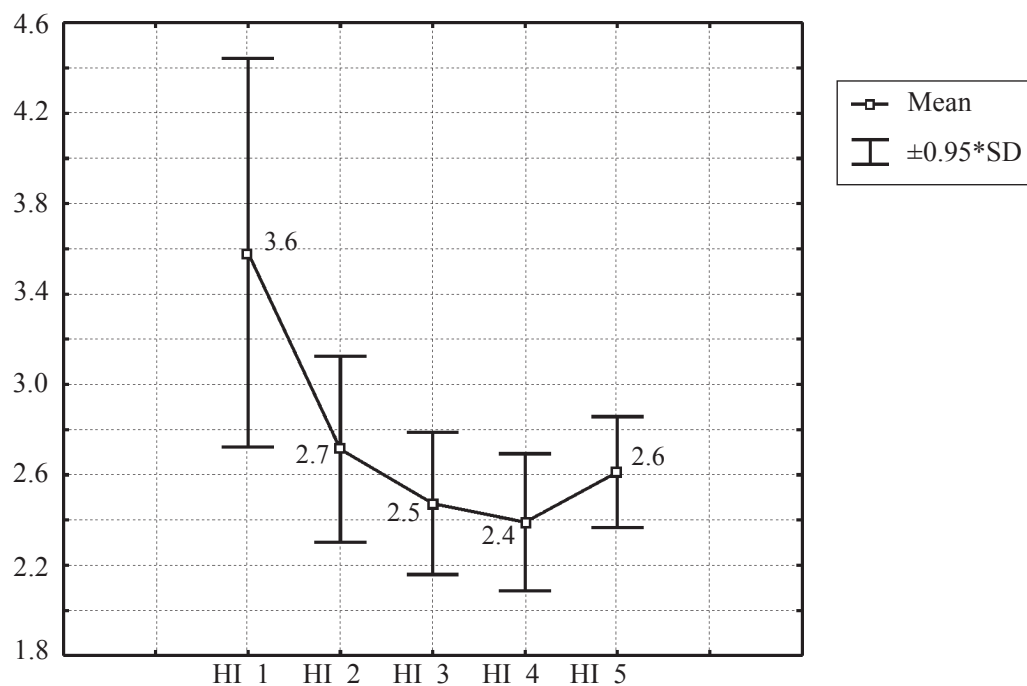


Fig. 6. Changes of Haller index (mean plot)

HI_1, HI_2, HI_3, HI_4, HI_5 – evaluation of Haller index (HI) before operation, 1, 6, and 12 months after operation and after removal of the bar, respectively.

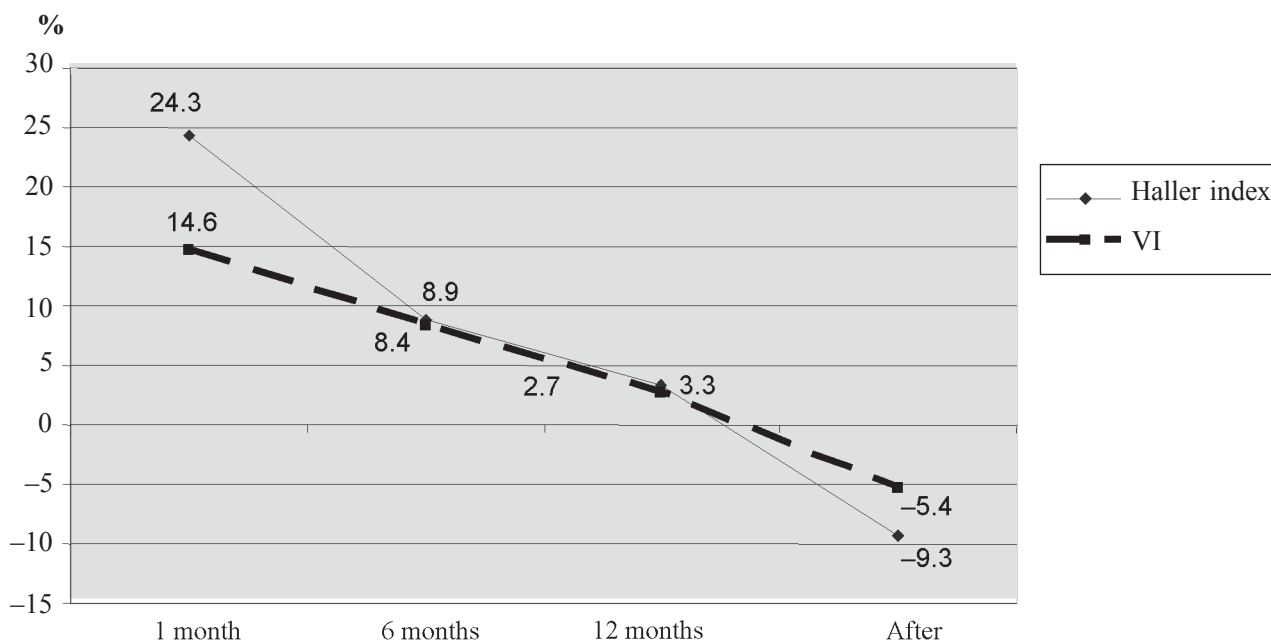


Fig. 7. Percentage changes in Haller index and vertebral index (VI) after operation
(1, 6, and 12 months after operation)

any publication about evaluation of chest radiographs during treatment period. Of course, most of the authors performed at least LP chest radiographs in order to detect possible dislocation of the Lorenz bar. However, SV was not measured. It is pointed out that rotation of the bar is one of the main early problems, leading

to imperfect results of treatment (4, 5, 7, 8, 11, 14).

We performed radiographic measurements of all follow-up patients. The results were grouped according to the time elapsed from the surgical repair; paired cases were not evaluated. Afterwards, the mean changes in chest dimensions were assessed. It was

unexpected that SV was increasing during one year after the operation, but was not restored immediately. After removal of the bar, SV showed a tendency to decrease (8.6 mm), but it was not significant, and follow-up radiographs were performed only 1 month after removal of the bar. In order to evaluate the results more precisely, long-term follow-up is necessary, as recurrence is possible later than 1 year after surgical repair (1, 3, 7). It is stated that recurrence is frequent in patients with Marfan syndrome (1), also in case of application of titanium bars. In our study, there were no patients with Marfan syndrome, and we used steel bar (Lorenz Surgical, Inc, Jacksonville, Fla).

The decrease in transversal chest dimension during the first month postoperation could be due to early postoperative changes such as pain, edema. We pre-

sume that this decrement is not significant in the overall evaluation of results of operation. In our opinion, for postoperative follow-up, it is more rational to apply VI, which is the ratio of SV to vertebral body length, but not widely used indexes, including sternovertebral and transverse dimensions (HI, frontosagittal index, pectus index, CT index). According to our data, vertebral body length was stable during the 2-year period.

Conclusions

Sternovertebral distance was significantly increased after Nuss operation. Restoration of deformation proceeds during all the first year after operation. The dynamics of deformation is better depicted by means of vertebral index rather than Haller index.

Rentgenologiniai pokyčiai atlikus Nuss'o operaciją dėl įdubios krūtinės

Artūras Kilda, Saulius Lukoševičius¹, Vidmantas Barauskas,
Živilė Jankauskaitė, Algidas Basevičius¹

Kauno medicinos universiteto Vaikų chirurgijos klinika, ¹Radiologijos klinika

Raktažodžiai: įdubi krūtinė, Nuss'o operacija, rentgenologiniai tyrimai, pooperaciniai rezultatai.

Santrauka. Tyrimo tikslas. Įvertinti sternovertebrinį atstumą ir krūtinės ląstos deformaciją po Nuss'o operacijos.

Medžiaga ir metodai. Tiesinė bei šoninė rentgenogramos padarytos prieš Nuss'o operaciją ir po operacijos praėjus 1, 6, 12 mėn. bei 1 mėn. po plokštelės išėmimo. Rentgenogramose buvo matuojamas sternovertebrinis atstumas, skersinis krūtinės ląstos matmuo, apskaičiuoti Haller'io ir vertebrinis indeksai.

Rezultatai. Nuss'o metodu dėl įdubios krūtinės operuoti 84 vaikai. Sternovertebrinis atstumas iki operacijos buvo $79,81 \pm 6,96$ mm, praėjus mėnesiui po operacijos – $97,84 \pm 17,08$ mm, praėjus 6 mėn. – $110,55 \pm 13,85$ mm, praėjus 12 mėn. – $113,6 \pm 14,61$ mm. Pašalinus plokštelę, atstumas išliko $105 \pm 11,95$ mm. Sternovertebrinis atstumas pirmąjį mėnesį padidėjo vidutiniškai 18 mm ($p < 0,0001$), 1–6 mėn. – 12,8 mm ($p = 0,0006$), 6–12 mėn. – 3 mm ($p = 0,48$). Pašalinus plokštelę, sternovertebrinis atstumas sumažėjo vidutiniškai 8,6 mm ($p = 0,47$). Skersinis krūtinės ląstos matmuo per pirmąjį mėnesį buvo reikšmingas ($13,3 \pm 12,86$ mm, $p = 0,012$).

Išvados. Sternovertebrinis atstumas po Nuss'o operacijos padidėjo reikšmingai. Deformacijos atsistatymas vyksta visus pirmuosius metus po operacijos. Deformacijos dinamikai vertinti tikslesnis vertebrinis indeksas nei Haller'io.

Adresas susirašinėti: S. Lukoševičius, KMU Radiologijos klinika, Eivenių 2, 50009 Kaunas
El. paštas: slu@delfi.lt, saulius.lukosevicius@kmuk.lt

References

1. Nuss D. Recent experiences with minimally invasive pectus excavatum repair "Nuss procedure". *Jpn J Thorac Cardiovasc Surg* 2005;53:338-44.
2. Ong CC, Choo K, Morreau P, Auldist A. The learning curve in learning the curve: a review of Nuss procedure in teenagers. *ANZ J Surg* 2005;75:421-4.
3. Park HJ, Lee SY, Lee CS, Youm W, Lee KR. The Nuss procedure for pectus excavatum: evolution of techniques and early results on 322 patients. *Ann Thorac Surg* 2004;77:289-95.
4. Molik KA, Engum SA, Rescorla FJ, West KW, Scherer LR, Grosfeld JL. Pectus excavatum repair: experience with standard and minimal invasive techniques. *J Pediatr Surg* 2001;36:324-8.
5. Engum S, Rescorla F, West K, Rouse T, Scherer LR, Grosfeld J. Is the grass greener? Early results of the Nuss procedure. *J Pediatr Surg* 2000;35:246-51.
6. Croitoru DP, Kelly RE Jr, Goretsky MJ, Gustin T, Keever R,

- Nuss D. The minimally invasive Nuss technique for recurrent or failed pectus excavatum repair in 50 patients. *J Pediatr Surg* 2005;40:181-6.
7. Uemura S, Nakagawa Y, Yoshida A, Choda Y. Experience in 100 cases with the Nuss procedure using a technique for stabilization of the pectus bar. *Pediatr Surg Int* 2003;19:186-9.
 8. Hosie S, Sitkiewicz T, Petersen C, Gobel P, Schaarschmidt K, Till H, et al. Minimally invasive repair of pectus excavatum – the Nuss procedure. A European multicentre experience. *Eur J Pediatr Surg* 2002;12:235-8.
 9. Rushing GD, Goretsky MJ, Gustin T, Morales M, Kelly RE Jr, Nuss D. When it is not an infection: metal allergy after the Nuss procedure for repair of pectus excavatum. *J Pediatr Surg* 2007;42:93-7.
 10. Ohno K, Morotomi Y, Ueda M, Yamada H, Shiokawa C, Nakaoka T, et al. Comparison of the Nuss procedure for pectus excavatum by age and uncommon complications. *Osaka City Med J* 2003;49:71-6.
 11. Park HJ, Lee SY, Lee CS. Complications associated with the Nuss procedure: analysis of risk factors and suggested measures for prevention of complications. *J Pediatr Surg* 2004;39:391-5.
 12. Calkins CM, Shew SB, Sharp RJ, Ostlie DJ, Yoder SM, Gittes GK, et al. Management of postoperative infections after the minimally invasive pectus excavatum repair. *J Pediatr Surg* 2005;40:1004-7.
 13. Van Renterghem KM, von BS, Bax NM, Fleer A, Hollwarth ME. Should an infected Nuss bar be removed? *J Pediatr Surg* 2005;40:670-3.
 14. Bohosiewicz J, Kudela G, Koszutski T. Results of Nuss procedures for the correction of pectus excavatum. *Eur J Pediatr Surg* 2005;15:6-10.
 15. Aronson DC, Bosgraaf RP, van der HC, Ekkelkamp S. Nuss procedure: pediatric surgical solution for adults with pectus excavatum. *World J Surg* 2007;31:26-9.
 16. Krasopoulos G, Dusmet M, Ladas G, Goldstraw P. Nuss procedure improves the quality of life in young male adults with pectus excavatum deformity. *Eur J Cardiothorac Surg* 2006;29:1-5.
 17. Kim DH, Hwang JJ, Lee MK, Lee DY, Paik HC. Analysis of the Nuss procedure for pectus excavatum in different age groups. *Ann Thorac Surg* 2005;80:1073-7.
 18. Lawson ML, Mellins RB, Tabangin M, Kelly RE Jr, Croitoru DP, Goretsky MJ, et al. Impact of pectus excavatum on pulmonary function before and after repair with the Nuss procedure. *J Pediatr Surg* 2005;40:174-80.
 19. Roberts J, Hayashi A, Anderson JO, Martin JM, Maxwell LL. Quality of life of patients who have undergone the Nuss procedure for pectus excavatum: preliminary findings. *J Pediatr Surg* 2003;38:779-83.
 20. Kilda A, Basevicius A, Barauskas V, Lukosevicius S, Ragaisis D. Radiological assessment of children with pectus excavatum. *Indian J Pediatr* 2007;74:143-7.

Received 12 December 2007, accepted 4 September 2009

Straipsnis gautas 2007 12 12, priimtas 2009 09 04