

APŽVALGINIS STRAIPSNIS

Cardiovascular magnetic resonance imaging for detection of myocardial viability in chronic ischemic left ventricular dysfunction

Sigita Glaveckaitė^{1,2}, Nomeda Valevičienė^{1,3}, Aleksandras Laucevičius^{1,2}, Jelena Čelutkienė^{1,2},
Alfredas Rudys^{1,2}, Algirdas Tamošiūnas^{1,3}

¹Faculty of Medicine, Vilnius University, ²Centre of Cardiology and Angiology,

³Centre of Radiology, Vilnius University Hospital Santariškių Klinikos, Lithuania

Key words: cardiovascular magnetic resonance; chronic ischemic left ventricular dysfunction; myocardial viability; hibernation; late contrast enhancement.

Summary. Chronic ischemic left ventricular dysfunction is present in number of clinical syndromes in which myocardial revascularization results in an improvement of left ventricular function, patients' functional class, and their survival. Coronary arteriography is of limited value in diagnosis of viability. Noninvasive testing, traditionally nuclear imaging, stress echocardiography and (stress) electrocardiography have been the clinical mainstays for assessing myocardial viability as well as to detect myocardial ischemia. However, cardiovascular magnetic resonance is a rapidly emerging noninvasive imaging technique, providing high-resolution images of the heart in any desired plane and without radiation. Rather than a single technique, cardiovascular magnetic resonance consists of several techniques that can be performed separately or in various combinations during a patient examination. Whereas, no single cardiovascular magnetic resonance technique has a perfect, or near perfect, sensitivity and specificity, therefore, a combination of various cardiovascular magnetic resonance techniques are needed for the assessment of myocardial viability.

The aim of this review article is to summarize our current understanding of the concept of myocardial viability, to discuss the clinical value of cardiovascular magnetic resonance (in particular the different cardiovascular magnetic resonance techniques to assess viability) for the evaluation of patients with coronary artery disease and chronic left ventricular dysfunction and to present the current place of cardiovascular magnetic resonance among other techniques for the assessment of viable myocardium.

Introduction: importance of detecting viable myocardium

Heart failure (HF) has become a major problem in clinical cardiology, with recent estimations showing that 4.9 million patients in the USA have chronic HF, with 550 000 new patients diagnosed annually, resulting in 970 000 hospitalizations (1). It appears that coronary artery disease (CAD) is the underlying cause of HF in 70% of patients (1). Currently, three routinely available directions of HF treatment are available: medical treatment, heart transplantation, and revascularization. In daily clinical practice, the choice is frequently made between medical treatment and revascularization. From this perspective, assessment

of myocardial viability is important to guide management of patients with ischemic left ventricular dysfunction (LVD); patients with viable myocardium may improve in left ventricle (LV) function and/or survival after revascularization, whereas patients with only scar tissue will not improve. Identification of patients with the potential of improvement in LV function and survival is needed to justify the higher risk of surgery in this group.

The main value of noninvasive assessment of viability is in the more severely and chronically disabled patient, in whom the outcome without intervention is poor, but the risk of revascularization is high (2). In patients with left ventricular ejection fraction (LVEF)

below 35%, the perioperative, in hospital and one year outcome is better when the need for revascularization is guided by preoperative assessment of viability (3). It is important to note that there are no prospective controlled studies of revascularization in patients with hibernating myocardium, and no randomized comparisons between revascularization and medical therapy. The strongest evidence to support revascularization will come from randomized trials (e.g., Surgical Treatment for Ischemic Heart failure [STICH] trial), but there is a reasonable body of nonrandomized evidence supporting revascularization of hibernating myocardium. A meta-analysis by Allman et al. (4) compiled the survival results of 24 studies involving 3088 patients with a mean LVEF of 32%. This meta-analysis provided evidence that patients with CAD and LVD who have viable myocardium not only have improved function after revascularization but also represent a high-risk group in whom survival is improved with revascularization (Fig. 1). In patients with myocardial viability, the annual mortality rate was significantly lower in patients treated with revascularization (3.2%) compared to those treated with medical therapy (16%). In contrast, patients in whom there was minimal or no evidence of myocardial viability appear to have no benefit with revascularization compared to the results of medical therapy (4).

Revascularization of hibernating myocardium results in an improvement of regional and global LV systolic function (5), remodeling is reversed (4, 6),

survival is increased (7), and there is a decrease of the composite of myocardial infarction (MI), HF, and unstable angina (8). Importantly, patients with the most severe LV dysfunction derived the greatest benefit from revascularization (8).

Definition and pathophysiology of hibernation

In the early 1980s, Rahimtoola et al. (9) reviewed the results of coronary bypass surgery trials and identified patients with CAD and chronic LVD that improved upon revascularization. They proposed the concept of hibernating myocardium as “prolonged ischemia... in which myocardial metabolism and ventricular function are reduced to match the reduced blood supply..., a new equilibrium... whereby necrosis is prevented, and the myocardium is capable of returning to normal or near-normal function on restoration of an adequate blood supply” (9).

The physiologic down-regulation of contractile function, also referred to as myocardial hibernation, is probably an adaptive response to myocardial ischemia, to protect myocytes from irreversible damage. Such down-regulation of function is associated with “down-regulation” of structure. Changes at cellular or subcellular level could therefore be reversible before significant structural disorders occur because long-term hibernation may lead to irreversible loss of myocardial function. Studies with PET, however, showed that chronically dysfunctional myocardium frequently had (near-) normal resting blood flow

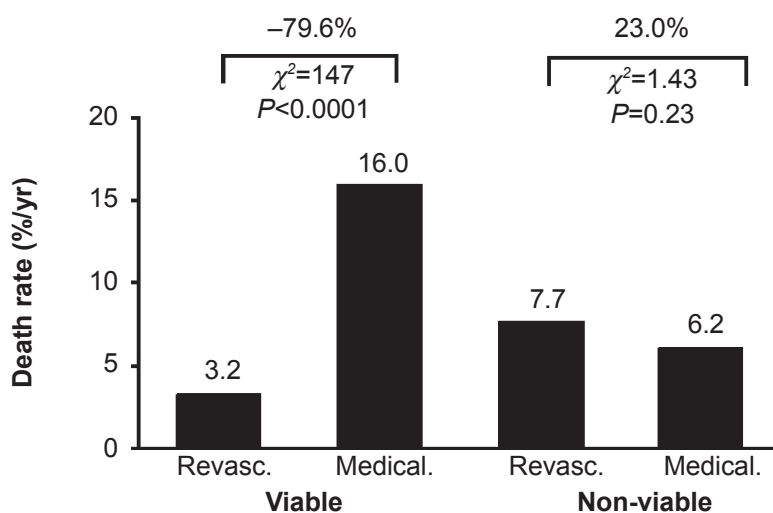


Fig. 1. Meta-analysis of 24 studies investigating the prognostic potential of myocardial viability testing

In patients with viable myocardium, assessed by either positron emission tomography, single-photon emission computed tomography, or dobutamine echocardiography (left panel), mortality was significantly lower among those undergoing revascularization compared to medical therapy. This finding was not observed in patients without evidence of myocardial viability (right panel). Reprinted from Allman et al. (4) with permission from the Journal of American College of Cardiology.

instead of reduced blood flow. Further studies subsequently revealed that not resting transmural myocardial blood flow, but rather subendocardial myocardial blood flow and coronary flow reserve were reduced in patients with chronically dysfunctional myocardium (8). These findings have led to the hypothesis that repeated ischemic attacks may result in chronic contractile dysfunction, with flow remaining normal or mildly reduced – a situation referred to as “repetitive stunning” (10). From a clinical viewpoint, the differentiation between repetitive stunning and hibernation may not be that important, since revascularization is required in both conditions in order to improve contractile function; from a practical viewpoint, both conditions can be grouped as “jeopardized myocardium” (11) or as single category of dysfunctional but viable myocardium.

It is particularly important to distinguish between viable and hibernating myocardium since the presence of viable myocardium does not *per se* imply recovery of function after revascularization. All reversible LVD must occur in viable tissue but not all viable tissue has the potential for reversible contractile dysfunction. Tests aimed solely at reversible LVD as the definition of viability will underestimate viability (consequently, tests aimed primarily at viability cannot be specific) (12). Infarcts where there has been vessel recanalization and preserved subepicardial tissue will not improve further if there is no element of severe ischemia producing hibernation or repetitive stunning. In addition, cardiomyopathies are viable but will not improve with revascularization. A combination of resting and/or inducible ischemia and preserved viability is required for reversible LVD in most cases (12). Thus, the most useful surrogate definition of hibernation is viable and dysfunctional myocardium in which impaired perfusion reserve leads to inducible ischemia (13).

Methods to assess myocardial viability

Some information on myocardial viability can be derived from the surface electrocardiogram, but imaging is more contributing in this clinical setting. Several noninvasive imaging techniques have been developed to identify dysfunctional but viable tissue: dobutamine stress echocardiography, single-photon emission computed tomography (SPECT) imaging with thallium-201 or technetium-99m-labeled tracers, and positron emission tomography (PET) metabolic imaging with ^{18}F -fluorodeoxyglucose (^{18}F -FDG). Magnetic resonance imaging (MRI) is another technique for assessment of myocardial viability.

The sensitivity, specificity, positive predictive value (PPV), and negative predictive value (NPV) of the various techniques for recovery of regional and for recovery of global LV function presented in Fig. 2.

A pooled analysis of studies reporting the performance of ^{18}F -FDG PET, ^{201}Tl stress redistribution-reinjection imaging, ^{201}Tl rest-redistribution imaging, $^{99\text{m}}\text{Tc}$ sestamibi SPECT imaging, and dobutamine echocardiography suggested a high sensitivity (83% to 90%) and modest specificity (54% to 81%) for the prediction of recovery of regional function. Radionuclide imaging had in general higher sensitivity, while imaging of contractile reserve (CR) by dobutamine echocardiography had higher specificity, and PET was slightly more accurate overall (15).

Still, specificities were in general lower than sensitivities, indicating that a substantial percentage of segments that are classified as viable by the imaging techniques overestimate recovery of function. Probably not, since various explanations, as why viable segments do not improve in function after revascularization have been published recently. These can be divided into issues before revascularization (severity of cellular damage in the hibernating myocardium; extent of LV remodeling; subendocardial scar formation; duration of hibernation before revascularization; large scar adjacent to viable myocardium), during revascularization (incomplete revascularization; ischemic damage during revascularization), and after revascularization (graft occlusion or restenosis, timing of assessment of function after revascularization) (14).

Cardiovascular magnetic resonance techniques to assess viability

Several cardiovascular magnetic resonance (CMR) techniques have been proposed for the assessment of myocardial viability. These techniques include resting CMR (which provides information on end-diastolic wall thickness [EDWT]), dobutamine stress CMR (DSMR) (which provides information on CR), and delayed contrast-enhanced CMR (DE-CMR) (which provides information on scar tissue). Compared with conventional cardiac diagnostic tests, there are advantages and disadvantages in using MRI to assess myocardial viability (Table 1).

Overall, CMR evaluation of patients with LV dysfunction is a powerful clinical tool when performed by experienced clinicians. Fig. 3 offers a simplified algorithm for the patient who is thought to have ischemic left ventricular dysfunction with HF and in whom revascularization to improve LV function is considered (13).

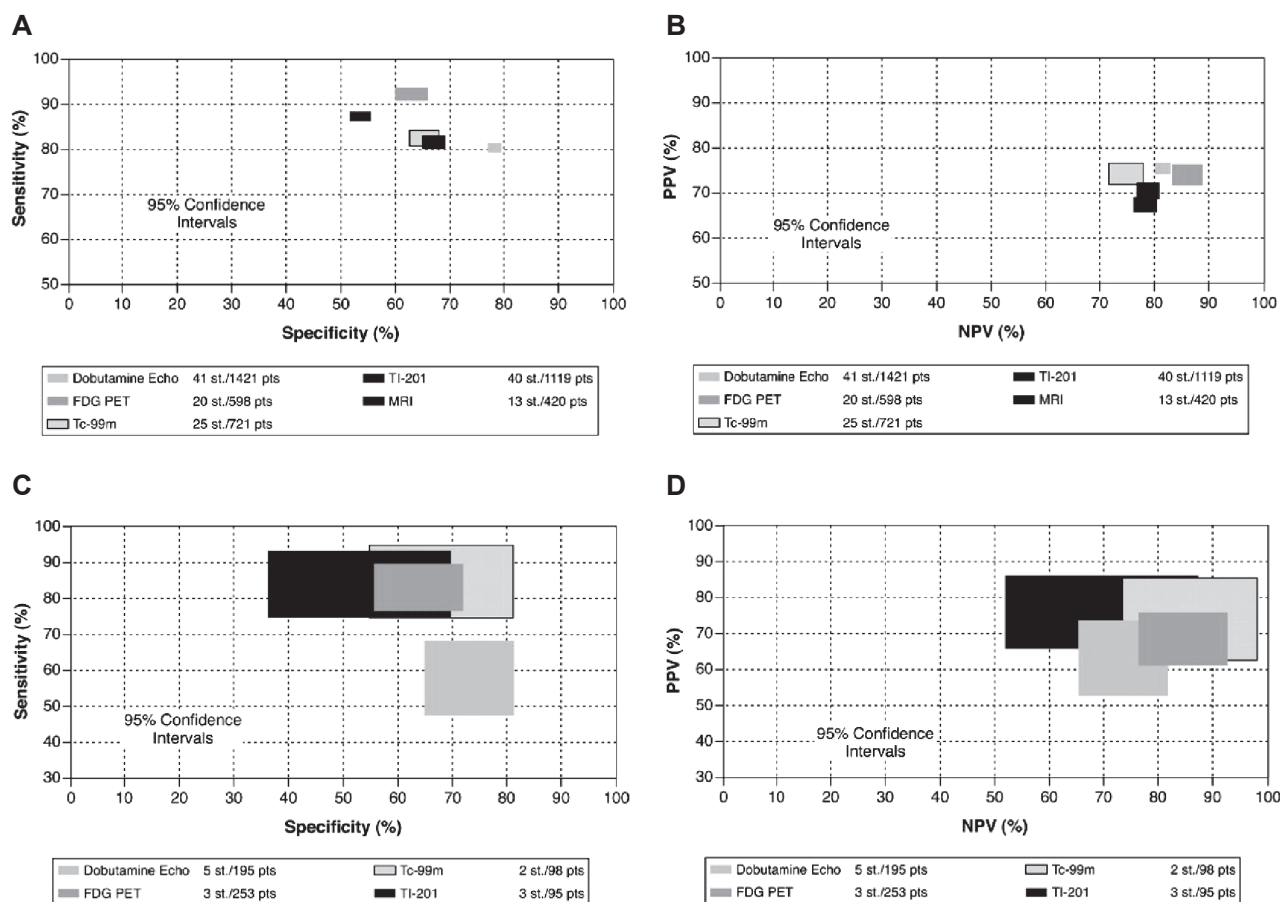


Fig. 2. Diagnostic accuracy of various techniques for functional recovery

Comparison of sensitivities and specificities (A) and predictive values (B) with 95% confidence intervals for the recovery of regional wall function. Comparison of sensitivities and specificities (C) and predictive values (D) of the various techniques with 95% confidence intervals for prediction of the recovery of global left ventricular function. FDG – 18F fluorodeoxyglucose; NPV – negative predictive value; PPV – positive predictive value; pts – number of patients; st – number of studies; Tc-99m – technetium-99m-labeled agents; Tl-201 – thallium 201; MRI – magnetic resonance imaging; dobutamine echo – dobutamine stress echocardiography. Reprinted, with permission, from Schinkel et al. (14).

Table 1. Advantages and disadvantages of using CMR to assess myocardial viability

Advantages	Disadvantages
High resolution (approximately 1 mm)	Image quality may be suboptimal if the patient has arrhythmias
Relatively simple imaging protocol	Best imaging done during breath holds, respiratory artefacts can degrade images
Gadolinium agents are well tolerated	Claustrophobia prevents some subjects from completing the study
Can assess viability with and without stress	Many obese patients cannot fit into many scanners used for cardiac imaging makers
Comprehensive exam of function, perfusion, and viability is practical	Contraindications currently include pacemakers and defibrillators
Better reproducibility	Limited availability
Not dependent on anatomy	Relative high cost
No ionizing radiation	Comparatively long study times
Possible to differentiate epicardial and endocardial processes	
Good sensitivity and specificity of integrated assessment protocols	

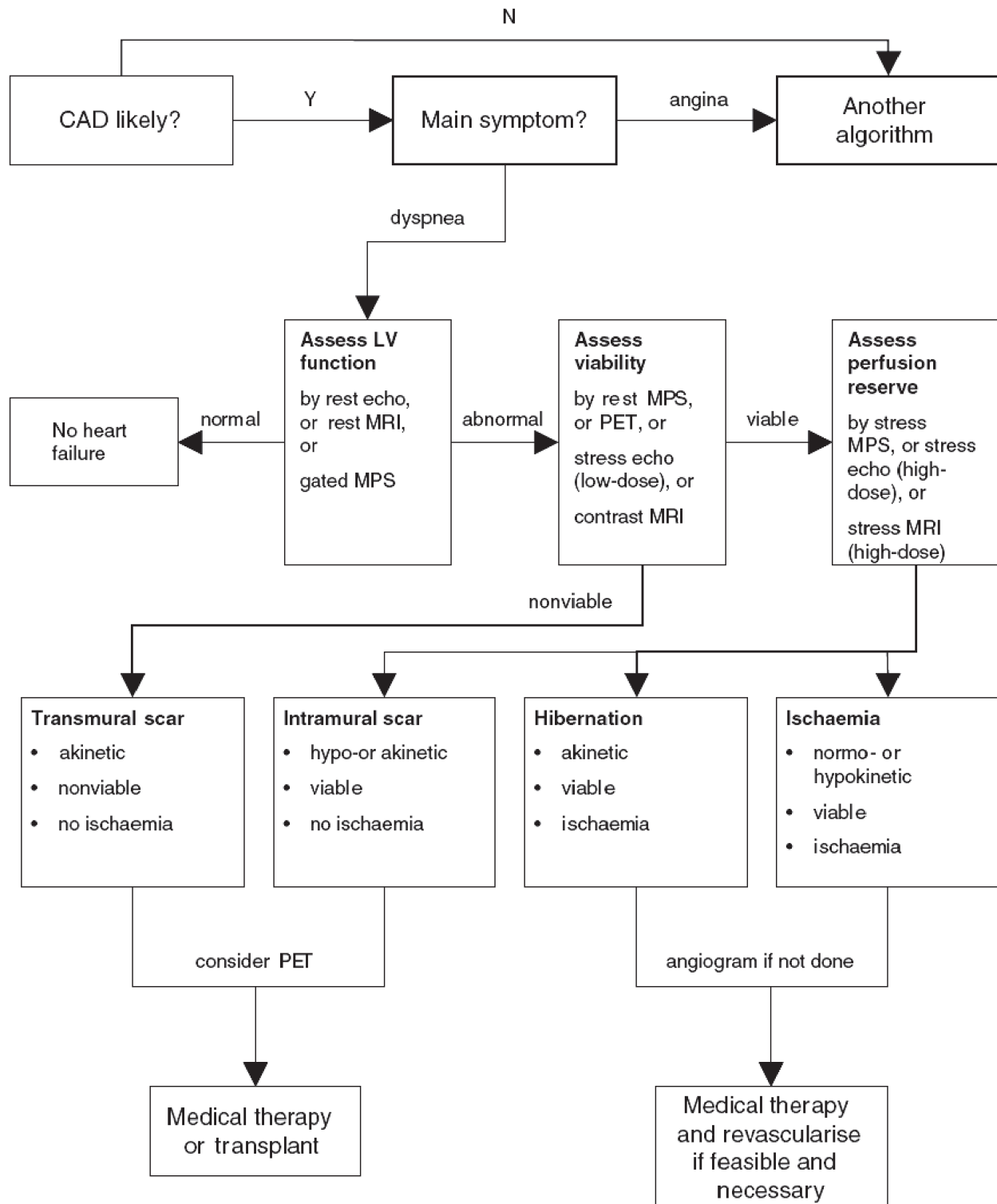


Fig. 3. Simplified clinical algorithm for the use of imaging techniques in selecting therapy in the patient thought to have ischemic left ventricular systolic dysfunction and heart failure

CAD – coronary artery disease; PET – positron emission tomography; MRI – magnetic resonance imaging; MPS – myocardial perfusion scintigraphy. Reprinted with permission of Oxford Journals (13).

Testing CMR to assess LV end-diastolic wall thickness

CMR is now considered gold standard for the evaluation of LV volume and mass, as well as myocardial wall thickness and thickening. As in other imaging modalities, the LV is divided into 17 segments, each of which can be attributed to a coronary artery (Fig. 4).

Due to scar formation and loss of myocytes after MI, the myocardium becomes thinned. Therefore, the measurement of EDWT may give information about the viability of dysfunctional myocardium. This, however, is only true for the chronic setting, as in the acute state, wall thickness may even increase due to interstitial edema. Histological data of transmural scar confirm an EDWT of 6 mm or less in chronic infarction (17). Various studies have demonstrated that wall thinning is frequently associated with transmural scar tissue. Baer et al. (18) performed a head-to-head comparison between resting CMR and FDG PET in 35 patients with chronic ischemic LVD. It was shown that regions with an EDWT <5.5 mm had significantly reduced FDG uptake, whereas regions with an EDWT ≥5.5 mm had preserved FDG uptake. In a subsequent study, Baer et al. (19) tested the value of EDWT for prediction of functional recovery postrevascularization. The authors showed that segments with an EDWT <5.5 mm virtually never showed recovery of function postrevascularization. The alternative was not true: segments with an EDWT ≥5.5 mm did not always improve in function postrevascularization. Segments with an EDWT ≥5.5 mm frequently contain subendocardial scar tissue, with residual viability in the epicardial layers. In the absence of jeopardized myocardium though, recovery of function will not occur after revascularization. However, it was recently demonstrated that even in the presence of severe wall

thinning, recovery of function may occur, but only when contrast enhanced CMR excludes scar tissue (20).

Three studies (with a total of 100 patients) have used EDWT to predict improvement of regional function after revascularization. Pooled analysis (Table 2) resulted in a weighted mean sensitivity and specificity of 95 and 41%, whereas the PPV and NPV were 56 and 92% (14).

Although measurement of EDWT gives important information in patients with ischemic HF, more accurate parameters for the assessment of viability such as CR and the late enhancement technique exist. Using only functional parameters at rest for the evaluation of viability is not recommended.

Dobutamine stress CMR to assess contractile reserve

There is a large body of evidence by echocardiography that the assessment of myocardial CR is a good predictor of contractile improvement after revascularization in chronic infarction as dysfunctional but viable myocardium will respond to adrenergic stimulation. However, several limitations of dobutamine echocardiography have been shown, for example, reduced accuracy in severely depressed LV (33). Similar to echocardiography, CMR can assess endocardial motion and systolic wall thickening before and during the infusion of low-dose dobutamine (LDD) (5–10 µg/min/kg body weight); however better image quality is obtained in patients with reduced image quality in echocardiography (34). Disadvantages of this technique are the use of dobutamine, which, however, carries a small risk.

For the assessment of viability, quantification is recommended to document improvement, especially

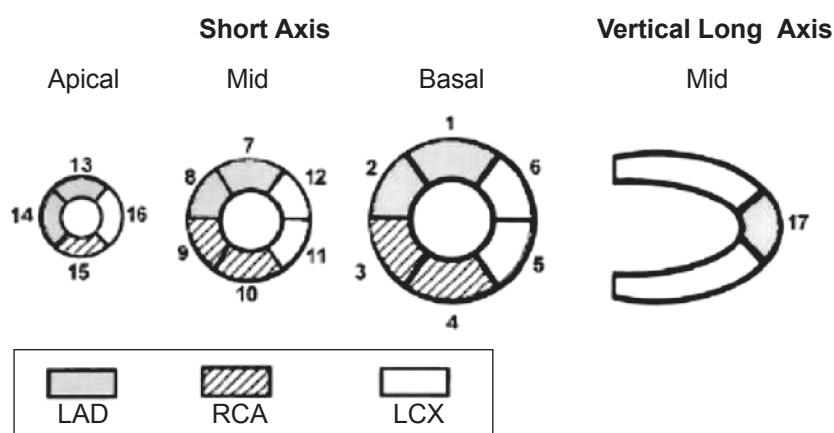


Fig. 4. Assignment of the 17 myocardial segments to the territories of the left anterior descending (LAD), right coronary artery (RCA), and the left circumflex coronary artery (LCX)

Reprinted with permission, from Cerqueira et al. (16).

Table 2. Pooled data of studies that evaluated the value of MRI in prediction of improvement of regional function after revascularization

Reference	No. of patients	Male (%)	Age (years)	LVEF (%)	Patients with MVD (%)	Patients with MI (%)	Segments with recovery*	Sensitivity (%)**	Specificity (%)***
EDWT									
Baer et al. (19)	43	93	58±9	42±10	70	100	46	94 (176/188)	52 (113/219)
Klow et al. (21)	17	88	63	40	NA	100	35	98 (63/64)	19 (23/120)
Schmidt et al. (22)	40	93	57±9	42±10	73	100	63	96 (24/25)	53 (8/15)
Weighted mean								95 (263/277)	41 (144/354)
DSMR									
Baer et al. (23)	52	92	58±9	41±10	75	100	56	86 (24/28)	92 (22/24)
Schmidt et al. (22)	40	84	57±9	42±10	73	100	63	96 (24/25)	87 (13/15)
Gunning et al. (24)	30	90	61±NA	24±8	100	100	57	50 (41/81)	81 (51/63)
Sayad et al. (25)	10	70	NA	NA	NA	NA	65	89 (25/28)	93 (14/15)
Baer et al. (19)	43	93	58±9	42±10	70	100	46	82 (155/188)	81 (177/219)
Sanstede et al. (26)	25	88	58±10	NA	NA	84	51	61 (65/106)	90 (91/101)
Trent et al. (27)	25	100	64±9	53±16	NA	100	33	71 (81/114)	70 (163/232)
Van Hoe et al. (28)	18	56	62±8	52±16	83	67	62	78 (56/72)	82 (37/45)
Wellnhofer et al. (29)	29	93	68±7	32±8	NA	93	50	75 (93/124)	93 (152/164)
Weighted mean								74 (564/766)	82 (720/878)
DE-CMR									
Wellnhofer et al. (29)	29	93	68±7	32±8	NA	93	50	90 (111/124)	52 (85/164)
Kuehl et al. (30)	29	72	66±9	32±10	NA	83	51	98 (94/96)	70 (64/91)
Kim et al. (31)	50	88	63±11	43±13	NA	42	53	86 (365/425)	61 (232/379)
Selvanayagan et al. (32)	52	NA	60	62±12	NA	NA	56	78 (266/343)	64 (173/269)
Van Hoe et al. (28)	18	56	62±8	52±16	83	67	62	78 (56/72)	92 (56/61)
Weighted mean								84 (891/1060)	63 (610/964)

LVEF, left ventricular ejection fraction; MI, myocardial infarction; MVD, multivessel disease; NA, not available; EDWT, end-diastolic wall thickness; DSMR, dobutamine stress magnetic resonance; DE-CMR, delayed contrast-enhanced cardiovascular magnetic resonance;

* percentage of segments with improved contractility after revascularization from all dysfunctional segments before revascularization;

** test-viable segments/segments with recovery after revascularization;

*** test-nonviable segments/segments without recovery after revascularization. Adapted, with permission, from Schinkel et al. (14).

in cases where stimulated myocardium is improved in comparison to rest, but may still be classified as hypokinetic. A minimal EDWT of >5 mm with resting thickening or resting akinesis with an improvement of systolic wall thickening of ≥2 mm during dobutamine stimulation are the CMR diagnostic criteria for viable myocardium (35).

Baer et al. (23) have demonstrated an excellent agreement between DSMR and ¹⁸F-FDG PET. When LDD stimulation was compared with scar imaging, it was found that low dose DSMR is superior to DE-CMR in predicting recovery of function after revascularization (29). This observation was most pronounced in segments with nontransmural scar. Subgroup analysis showed superiority of low dose DSMR for 1% to 74% transmural extent of infarction. As an explanation, it was suggested that even though

DE-CMR depicts the area of myocardial fibrosis, it does not assess the functional state of the surrounding (potentially viable) myocardium, and thus its capability for the prediction of functional recovery of nontransmurally scarred myocardium is limited (36).

A total of nine studies with 272 patients using DSMR to predict recovery of regional function have been published with a mean sensitivity of 74% and a mean specificity of 82% (Table 2); PPV and NPV were both 78% (14). Thus, DSMR has a high specificity with a slightly lower sensitivity for prediction of recovery of regional function.

Delayed contrast-enhanced CMR to assess scar tissue

Contrast hyperenhancement on delayed rest MR images is defined as regions with increased intensity

on T1-weighted images acquired more than 5 min after the intravenous administration of a contrast agent (37). The contrast agent applied in CMR is a gadolinium-chelated contrast agent with paramagnetic properties. This metabolically inert molecule is a freely diffusible agent that has extracellular distribution and accentuates the difference in tissue relaxation characteristics between infarcted and normal myocardium. Following intravenous administration, the contrast agent diffuses rapidly from the intravascular to the extracellular compartment, but not into intact cells. The hypothesis of enhancement is the increased distribution volume of the contrast agent in the acute setting, due to cell death, and in the chronic setting due to an increased interstitial space due to cell loss and scar formation and an altered wash-in and wash-out kinetic (38). Depending on the dose, 10 to 15 minutes after injection, a “late” steady-state phase is reached when gadolinium-chelated contrast agents have washed out of normal myocardium but remain in scarred or acutely infarcted tissue. With current T1-weighted inversion recovery scans, myocardial scar should appear bright against a uniformly dark background of normal myocardium (Fig. 5). This has led to the aphorism that “bright is dead.”

Using this technique, many studies have been conducted in acute and chronic myocardial infarction. Kim et al. (39) elegantly validated the value of DE-CMR to detect scar tissue in animal experiments. In chronically instrumented dogs with previous infarction, the authors showed a perfect agreement between the extent of scar tissue on DE-CMR and the histological extent of necrosis using triphenyltetrazolium chloride staining of the explanted hearts. There were close correlations between infarct size by CMR and histopathology on day 1, day 3, and week 8 postinfarct. Furthermore, stunned myocardium induced by brief coronary occlusion of a noninfarct-related coronary artery did not exhibit delayed enhancement. This work was extended by the same group in 24 canine infarcts studied 4 hours, 1 day, 10 days, 4 weeks, and 8 weeks after infarction (40). The later work clearly demonstrated that ischemic but viable myocardium did not enhance with gadolinium.

The clinical validation of DE-CMR imaging has been comprehensive and of sufficient quality that the method is accepted as a CMR standard for viability assessment (41). Kim et al. (31) found that the transmural extent of infarction was inversely proportional to the probability of regional recovery of function after

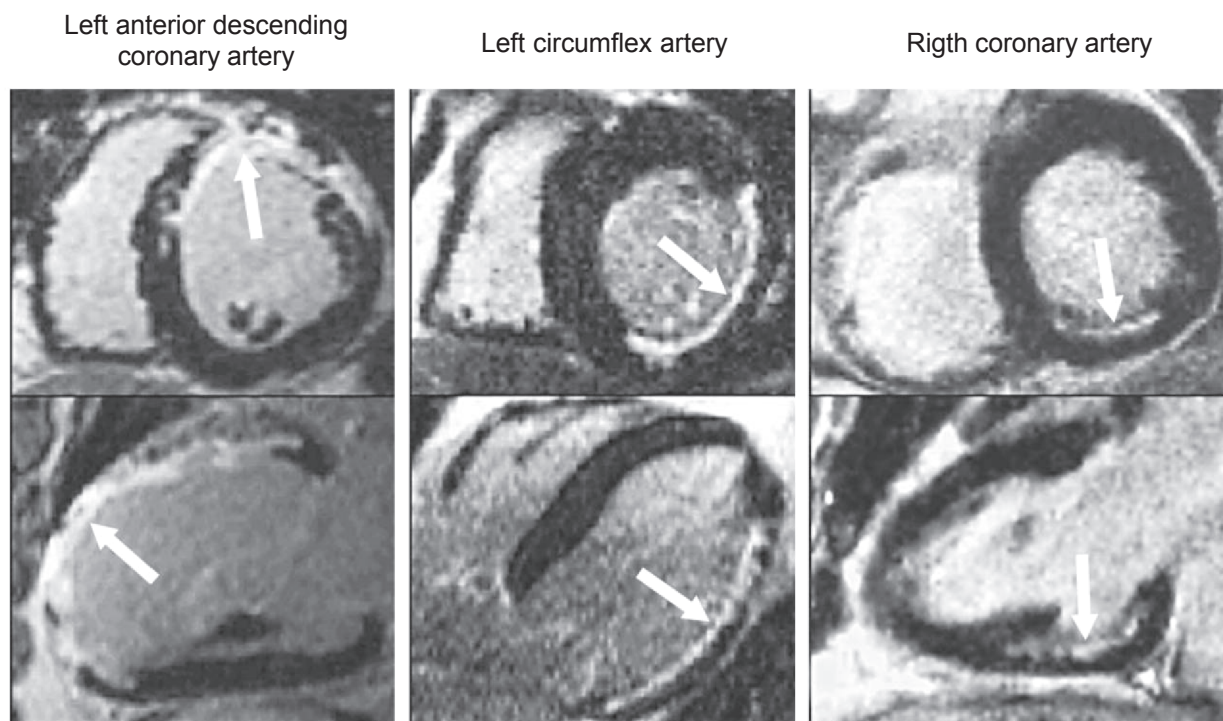


Fig. 5. Typical contrast-enhanced images obtained by MRI in a short-axis view (upper panels) and a long-axis view (lower panels) in three patients

Hyperenhancement is present (arrows) in various coronary perfusion territories – the left anterior descending coronary artery, the left circumflex artery, and the right coronary artery – with a range of transmural involvement. Reprinted from Kim et al. (31) with permission from New England Journal of Medicine.

revascularization. This study provided the first clinical evidence that DE-CMR imaging was able to assess viability with recovery of function after revascularization as the study endpoint. This study also provided pathophysiological insight into the role of subendocardial and transmural MI. Kim et al. (31) found that the transmural extent of myocardial scarring predicted the probability of recovery of function: improvement of function decreased progressively as the transmural extent of scar tissue increased. In particular, 78% of dysfunctional segments without contrast enhancement improved in function, as compared to 2% of segments with scar tissue extending >75% of the LV wall (Fig. 6). Using a cut-off value of 25% transmural extent of scar tissue, the positive and negative predictive values would be 71 and 79%, respectively, for regions with any degree of dysfunction and 88 and 89%, respectively, for regions with akinesia or dyskinesia. Changing the cut-off value to 75% transmural extent, none of the 57 segments with at least severe hypokinesia at baseline would be considered to have increased contractility after revascularization, yielding a negative predictive

accuracy of 100%. In this study (31), 90% of the regions with hyperenhancement of 51 to 75% of tissue before revascularization did not improve after revascularization; therefore, the transmural extent of >50% seems to be the threshold. In segments with a transmural extent between 25% and 50%, in which the likelihood of improvement is approximately 50%, the additional employment of low-dose dobutamine to test the CR may increase diagnostic accuracy (29). The latter data can be interpreted in two ways (41). If the primary clinical goal is predicting changes in regional function, then a physiological test that directly assesses regional function under dobutamine stimulation may be more optimal. However, there may be additional considerations, such as ischemia and arrhythmias that are modulated by reperfusion but may not be manifested in regional assessments of function. The detection of an epicardial rim of viable tissue by DE-CMR represents diagnostic information that is not available with the use of other noninvasive imaging techniques.

Pooling of the five available studies (total 178 patients) using DE-CMR to predict recovery of regional

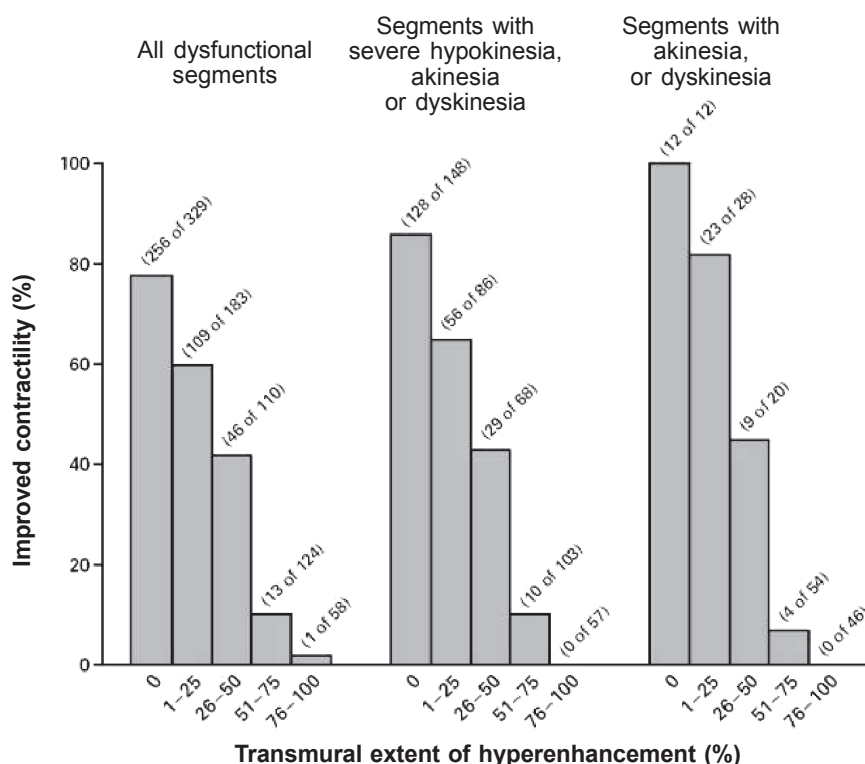


Fig. 6. The likelihood of dysfunctional segments to improve contractile performance after revascularization according to the transmural extent of enhancement

The higher the transmural enhancement, the lower likelihood of improvement, while the threshold seems to be about 50% transmural enhancement. Segments with no or only up to 25% transmural enhancement recover to a high percentage. Reprinted from Kim et al. (31) with permission from New England Journal of Medicine.

function after revascularization revealed a mean sensitivity of 84% with a mean specificity of 63% (Table 2), and PPV and NPV of 72 and 78% (14).

The suboptimal specificity is related to the presence of segments with subendocardial necrosis (and epicardial viability) that do not improve in function. The low specificity indicates that information on the constitution of the epicardial regions is needed: do they contain normal, viable tissue or jeopardized myocardium (11)?

Validation of DE-CMR infarct images in humans has also relied on correlations with nuclear imaging. The enhancement technique is highly reproducible (42) and shows good agreement with SPECT (43) and PET (44, 45). Klein and colleagues (44) evaluated 31 patients with depressed LVEF (mean (SD), 28 (9)%) using FDG PET and DE-CMR. The agreement between both techniques for assessing scar tissue was 91%. Importantly, 11% of segments defined as viable on FDG PET had some extent of scar tissue on DE-CMR. This reflects the superior spatial resolution of CMR allowing discrimination of small subendocardial infarcts. Delayed-enhancement imaging by MRI has several advantages over PET and SPECT methods. The two biggest are the improved resolution properties of the CMR image and the ability to measure a positive image rather than a negative image (measuring what

you cannot see). Due to better spatial resolution, MRI is able to resolve subendocardial infarction from transmural infarction.

From studies mentioned above, it is reasonable to conclude that DE-CMR imaging is an excellent clinical tool for assessing the transmural extent of MI. DE-CMR can predict recovery of function after revascularization and is capable of determining myocardial viability in the setting of chronic CAD. It correlates with SPECT imaging but has significant advantages in resolution for detecting small subendocardial infarctions.

Comparison of CMR techniques to predict functional recovery

When pooled data are compared, the differences in accuracy of the various CMR techniques to predict recovery of regional function postrevascularization become more clear (Fig. 7). The sensitivity of EDWT and DE-CMR are significantly higher than that of DSMR. Conversely, the specificity of DSMR is significantly higher than that of EDWT and DE-CMR. Integrated use of CMR techniques can be considered for optimal prediction of functional recovery. A very sensitive technique, such as DE-CMR, may serve as first step. In the presence of minimal scar tissue (transmurality, 25%), recovery of function is likely to

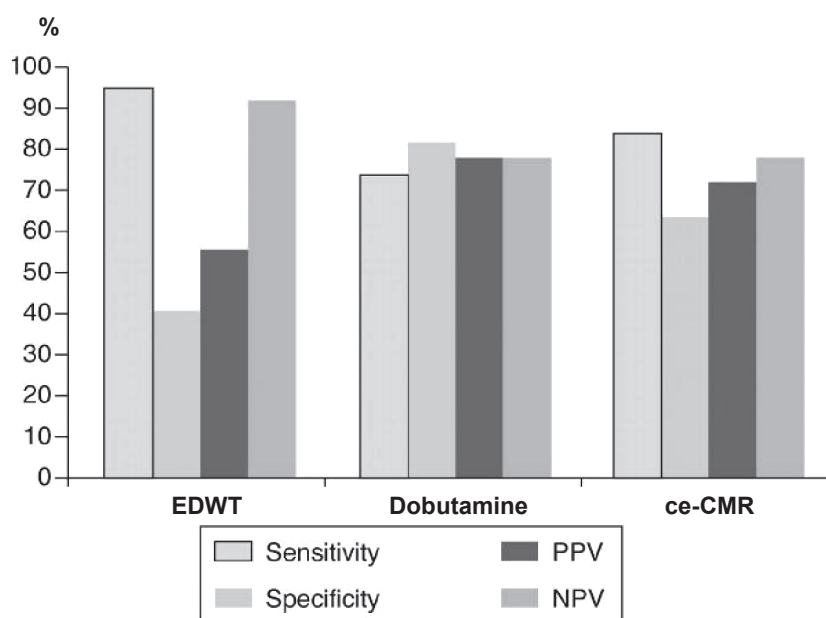


Fig. 7. Diagnostic accuracy of MRI for postrevascularization improvement in regional function

Sensitivity, specificity, positive predictive value (PPV), and negative predictive value (NPV) of data from various techniques with cardiac magnetic resonance (CMR).

DE-CMR – contrast-enhanced cardiac magnetic resonance; EDWT – end-diastolic wall thickness.

Figure reprinted from data of Schinkel et al. (14), with permission.

occur, whereas segments with extensive scar tissue (transmurality, >50–100%) will not recover (as shown in the study by Kim et al. (31)). Segments with an intermediate extent of scar tissue (transmurality, 25–50%) have an intermediate likelihood of recovery, and in these segments, additional testing may be needed. DSMR may serve as a second step in these segments in order to further differentiate between segments with low (without CR) and high likelihood (with CR) to improve in function postrevascularization. Kaandorp et al. (46) demonstrated the feasibility of integrated assessment of DE-CMR and DSMR only before revascularization. Bodi et al. (47) imaged 40 patients at both 7 days and 6 months following a first acute MI and evaluated them for four previously validated viability indices: wall thickness (>5.5 mm), CR with LDD, contrast-enhanced perfusion, and contrast enhancement (<50%). Viability was defined as an improvement in wall thickening during rest 6 months after reperfusion therapy. At the completion of the study, 39% of dysfunctional segments initially detected had regained resting function. As expected, the transmural extent of necrosis was a powerful predictor of viability, with a positive predictive value of 85%, whereas diastolic wall thickness had the best negative predictive value (87%). The value of the dobutamine response was in its specificity, which varied widely according to the presence and transmural extent of necrosis. A “comprehensive viability assessment” that

integrated all four parameters provided the strongest predictive assessment. For example, in cases of non-transmural necrosis, a positive response to dobutamine increased the likelihood of functional recovery from 77 to 95%.

Only one up to now available study of Bove et al. (48) prospectively tested the hypothesis that addition of LDD and quantification of CR in segments with 1–50% infarct transmurality would improve the predictive value for recovery of regional function after revascularization (coronary artery bypass grafting) in chronic MI. Fifteen patients with multivessel CAD and LVD (LVEF, $37 \pm 4\%$) were enrolled prior to surgery. The presence of wall thickening was measured with cine cardiac MR imaging at rest and during infusion of $10 \mu\text{g/kg/min}$ dobutamine. Repeat CMR imaging was performed 20 ± 4 weeks later. In segments with 1–50% infarct transmurality, improvement in wall thickening after revascularization was predicted better by the response to dobutamine prior to revascularization than by infarct transmurality (Fig. 8). This suggests that if functional recovery after revascularization is the goal of viability imaging, then CR may add to the available information in segments with 1–50% infarct transmurality. Both the above-mentioned studies advance the concept that a more comprehensive approach to defining viability by CMR is warranted when functional recovery of regional function is the desired endpoint (29). The accuracy of

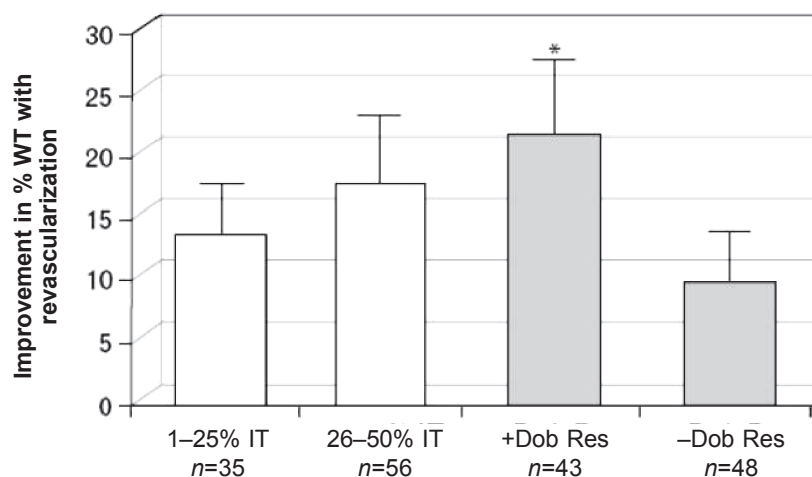


Fig. 8. Improvement in percentage wall thickening after revascularization in all 91 segments with 1–50% infarct thickness, by infarct thickness (white bars) and dobutamine response (gray bars)

No difference was seen in the improvement in wall thickening (WT) between segments with 1–25% and with 26–50% infarct thickness (IT), whereas a significant difference was noted between dobutamine responding segments (+Dob Res) and those that did not respond (–Dob Res);

* $P < 0.04$ compared with no dobutamine response (48). Reprinted by permission of RSNA Publications.

integrated approach, however, needs further evaluation especially in patients with more severe LV dysfunction undergoing revascularization and regarding other desired study endpoints such as global LV function (there is one study by Kim et al. (31) that reported the predictive value of DE-CMR relative to improved LVEF after revascularization) and clinical benefit even without functional improvement after revascularization.

Finally, by CMR additional information can be provided such as LV function, LV volumes, presence and degree of ischemic mitral regurgitation, LV geometry. This information is needed preoperatively to determine the optimal surgical procedure.

Other CMR techniques to assess viability

There are studies using integrated approach of other various CMR techniques for assessing of myocardial viability. For example, instead of visual evaluation of CR during DSMR, combination of myocardial tagging and DSMR can be used to make a more quantitative assessment of mechanical function. Sayad et al. (25) described quantification of LV thickening using CMR with myocardial tagging in 10 patients with segmental wall abnormalities at rest. Each subject underwent CMR scanning at baseline, after dobutamine infusion up to 10 $\mu\text{g/kg/min}$, and 4–8 weeks after revascularization. Using CMR with tagging, resting end-diastolic and end-systolic wall thicknesses in abnormal segments at rest were compared with those measured at peak dobutamine and again after revascularization. It was found that end-systolic wall thickness after LDD infusion predicted improvement in segmental function after revascularization. Alternatively, segments with a resting end-systolic wall thickness of less than 7 mm did not improve after revascularization. Thus, DSMR with tagging techniques predicted viability in myocardial segments with resting wall motion abnormalities.

CMR is capable of detecting improvement in myocardial perfusion before and after revascularization (28, 49). However regarding myocardial viability, Sanstede et al. (50) found that cine MRI and DE-CMR were more useful in predicting recovery of regional myocardial function after revascularization compared with rest perfusion imaging. The high predictive value of DE-CMR relegates the main benefit of perfusion imaging to further defining the pathophysiology of segments with intermediate degrees of delayed enhancement or in special circumstances where the presence of myocardial ischemia is in question despite the presence of some degree of coronary stenosis (51).

Kuehl et al. (52) compared EDWT and thickness of the residual noncontrast-enhanced myocardial rim for the prediction of myocardial viability as determined by FDG-PET. Twenty-two patients with ischemic cardiomyopathy (LVEF, $31\pm 11\%$) were investigated. Cutoffs of 5.4 mm for EDWT and 3.0 mm for unenhanced myocardial rim were found to optimally differentiate viability by FDG-PET. In 25 segments with divergent results, 94% of segments with an EDWT ≤ 5.4 mm and an unenhanced myocardial rim > 3.0 mm were scored as viable by FDG-PET, whereas 57% of segments with an EDWT > 5.4 mm and an unenhanced myocardial rim ≤ 3.0 mm were scored nonviable with the reference technique. In conclusion, unenhanced myocardial rim is superior to EDWT for the prediction of myocardial viability as determined by FDG-PET and may be clinically useful for assessment of myocardial viability in patients with ischemic cardiomyopathy and regional wall thinning.

There are studies using new technological achievements in CMR field and CMR spectroscopic techniques for assessing of myocardial viability. Clinical role of those advanced CMR techniques is not established at the moment.

Conclusions

With the increasing number of patients with ischemic HF, information on myocardial viability is needed to guide patient treatment. Accurate viability assessment is possible with CMR using different techniques including EDWT measurement, DSMR, and DE-CMR. While DSMR has the highest specificity to predict functional recovery postrevascularization, EDWT and DE-CMR have a higher sensitivity. Integrated use of particularly DSMR and DE-CMR may be preferred for optimal prediction of functional recovery. Finally, CMR can provide additional information on LVEF, LV volumes, ischemic mitral regurgitation and LV shape (aneurysms), which can be used to plan the surgical strategy.

MR imaging will normally be reserved to assess rest and/or stress LV function if further clarification is required after echocardiography and/or myocardial perfusion scintigraphy. However, if MR imaging is readily available, it is a good alternative to echocardiography for the assessment of rest and stress LV function (13).

With increasing availability of scanners and dissemination of imaging expertise, CMR is poised to take on an even larger role in routine viability evaluation, making a comprehensive understanding of the CMR approach imperative (53).

Sergančiųjų lėtine išemine kairiojo skilvelio disfunkcija miokardo gyvybingumo nustatymas širdies ir kraujagyslių magnetinio rezonanso tyrimu

Sigita Glaveckaitė^{1,2}, Nomedė Valevičienė^{1,3}, Aleksandras Laucevičius^{1,2}, Jelena Čelutkienė^{1,2},
Alfredas Rudys^{1,2}, Algirdas Tamošiūnas^{1,3}

Vilniaus universiteto ¹Medicinos fakultetas, Vilniaus universiteto ligoninės Santariškių klinikų

²Kardiologijos ir angiologijos centras, ³Radiologijos centras

Raktažodžiai: širdies ir kraujagyslių magnetinis rezonansas, lėtinė išeminė kairiojo skilvelio disfunkcija, miokardo gyvybingumas, hibernacija, vėlyvasis kontrastinės medžiagos kaupimas.

Santrauka. Lėtinė išeminė kairiojo skilvelio disfunkcija būdinga keletui klinikinių sindromų, kuriems esant miokardo revaskulizacija lemia kairiojo skilvelio funkcijos, paciento funkcinės klasės bei paciento išgyvenamumo pagerėjimą. Vainikinių arterijų angiografijos reikšmė, įvertinant miokardo gyvybingumą, yra ribota. Tradiciniai neinvaziniai tyrimų metodai, pvz., radioizotopiniai širdies tyrimai, krūvio echokardiografija ir (krūvio) elektrokardiografija iki šiol buvo pagrindiniai metodai miokardo gyvybingumui ir miokardo išemijai įvertinti. Šiuo metu širdies ir kraujagyslių magnetinio rezonanso tyrimas yra sparčiai tobulinamas neinvazinis vaizdinis metodas, kuriuo gaunami didelės skiriamosios gebos vaizdai bet kurioje plokštumoje nenaudojant radiacijos. Širdies ir kraujagyslių magnetinio rezonanso tyrimas susideda ne iš vieno, bet iš kelių skirtingų metodų, kurie gali būti naudojami atskirai arba derinami tarpusavyje. Kadangi nėra vienas širdies ir kraujagyslių magnetinio rezonanso miokardo gyvybingumo nustatymo metodas nepasižymi idealiu ar beveik idealiu jautrumu ir specifiškumu, todėl, norint tiksliau įvertinti miokardo gyvybingumą, reikėtų derinti skirtingus širdies ir kraujagyslių magnetinio rezonanso metodus.

Šio apžvalginio straipsnio tikslas – apibendrinti šiuolaikinį supratimą apie miokardo gyvybingumą, aptarti širdies ir kraujagyslių magnetinio rezonanso tyrimo klinikinę vertę (ypač skirtingų širdies ir kraujagyslių magnetinio rezonanso metodų vertę, naudojamų miokardo gyvybingumui nustatyti) tiriant pacientus, sergančius išemine širdies liga bei turinčius kairiojo skilvelio disfunkciją, taip pat įrodyti širdies ir kraujagyslių magnetinio rezonanso tyrimo svarbą, lyginant su kitais neinvaziniais tyrimo metodais, naudojamais miokardo gyvybingumui įvertinti.

Adresas susirašinėti: S. Glaveckaitė, VU Medicinos fakulteto Širdies ir kraujagyslių ligų klinika, Santariškių 2, 08661 Vilnius. El. paštas: sigita.glaveckaite@santa.lt

References

1. American Heart Association. Heart disease and stroke statistics, 2005 update. Dallas, Texas: American Heart Association; 2005.
2. Auerbach MA, Schroder H, Hoh C, Gambhir SS, Yaghoubi S, Sayre JW, et al. Prevalence of myocardial viability as detected by positron emission tomography in patients with ischemic cardiomyopathy. *Circulation* 1999;99:2921-6.
3. Haas F, Haehnel CJ, Picker W, Nekolla S, Martinoff S, Meisner H, et al. Preoperative positron emission tomographic viability assessment and perioperative and postoperative risk in patients with advanced ischemic heart disease. *J Am Coll Cardiol* 1997;30:1693-700.
4. Allman KC, Shaw LJ, Hachamovitch R, Udelson JE. Myocardial viability testing and impact of revascularization on prognosis in patients with coronary artery disease and left ventricular dysfunction: a metaanalysis. *J Am Coll Cardiol* 2002;39:1151-8.
5. Carluccio E, Biagioli P, Alunni G, Murrone A, Giombolini C, Ragni T, et al. Patients with hibernating myocardium show altered left ventricular volumes and shape, which revert after revascularization: evidence that dyssynergy might directly induce cardiac remodelling. *J Am Coll Cardiol* 2006;47:969-77.
6. Rahimtoola SH, La Canna G, Perrari R. Hibernating myocardium: another piece of the puzzle falls into place. *J Am Coll Cardiol* 2006;47:978-80.
7. Allman KC, Shaw LJ, Hachamovitch R, Udelson JE. Prognostic value of myocardial viability testing: a meta-analysis. *Circulation* 2000;102 Suppl II:576.
8. Rahimtoola SH, Dilsizian V, Marwick TH, Vanoverschelde JJ. Chronic ischemic left ventricular dysfunction. From pathophysiology to imaging and its integration into clinical practice. *JACC Cardiovasc Imaging* 2008; 1:536-555.
9. Rahimtoola SH. A perspective on the three large multicenter randomized clinical trials of coronary bypass surgery for chronic stable angina. *Circulation* 1985;72(Suppl V):V-123-35.
10. Vanoverschelde JJJ, Wijns W, Depre C, Essamri B, Heyndrickx GR, Borgers M, et al. Mechanisms of chronic regional postischemic dysfunction in humans. New insights from the study of noninfarcted collateral-dependent myocardium. *Circulation* 1993;87: 1513-23.

11. Kaandorp TAM, Lamb HJ, van der Wall EE, de Roos A, Bax JJ. Cardiovascular MR to assess myocardial viability in chronic ischemic LV dysfunction. *Heart* 2005;91:1359-65.
12. Cristian TF. Nuclear cardiology and CMR for assessment of coronary heart disease. In: Kwong RY, editor. *Cardiovascular magnetic resonance imaging*. Totowa, New Jersey: Humana Press Inc 2008:388-9.
13. Underwood SR, Bax JJ, vom Dahl J, Henein MI, van Rossum AC, Schwarz ER, et al. Imaging techniques for the assessment of myocardial hibernation. Report of a Study Group of the European Society of Cardiology. *Eur Heart J* 2004;25:815-36.
14. Schinkel AF, Bax JJ, Poldermans D, Elhendy A, Ferrari R, Rahimtoola SH. Hibernating myocardium: diagnosis and patient outcomes. *Curr Probl Cardiol* 2007;32:375-410.
15. Udelson JE, Finely JIV, Dilsizian V. Comparison of imaging modalities in the assessment of myocardial viability. In: Di Carli MF, Lipton MJ, editors. *Cardiac PET and PET/CT imaging*. New York: Springer; 2007. p. 295-322.
16. Cerqueira MD, Weissman NJ, Dilsizian V, Jacobs AK, Kaul S, Laskey WK, et al. Standardized myocardial segmentation and nomenclature for tomographic imaging of the heart: a statement for healthcare professionals from the Cardiac Imaging Committee of the Council on Clinical Cardiology of the American Heart Association. *Circulation* 2002;105:539-42.
17. Dubnow MH, Burchell HB, Titus JL. Postinfarction ventricular aneurysm. A clinicomorphologic and electrocardiographic study of 80 cases. *Am Heart J* 1965;70:753-60.
18. Baer FM, Voth E, Schneider CA, Theissen P, Schicha H, Sechtem U. Comparison of low-dose dobutamine gradient-echo magnetic resonance imaging and positron emission tomography with [18F]fluorodeoxyglucose in patients with chronic coronary artery disease. A functional and morphological approach to the detection of residual myocardial viability. *Circulation* 1995;91:1006-15.
19. Baer FM, Theissen P, Schneider CA, Voth E, Sechtem U, Schicha H, et al. Dobutamine magnetic resonance imaging predicts contractile recovery of chronically dysfunctional myocardium after successful revascularization. *J Am Coll Cardiol* 1998;31:1040-8.
20. John AS, Dreyfus GD, Pennell DJ. Images in cardiovascular medicine. Reversible wall thinning in hibernation predicted by cardiovascular magnetic resonance. *Circulation* 2005;111:e24-5.
21. Klow NE, Smith HJ, Gullestad L, Seem E, Endresen K. Outcome of bypass surgery in patients with chronic ischemic left ventricular dysfunction. Predictive value of MR imaging. *Acta Radiol* 1997;38:76-82.
22. Schmidt M, Voth E, Schneider CA, Theissen P, Wagner R, Baer FM, et al. F-18-FDG uptake is a reliable predictor of functional recovery of akinetic but viable infarct regions as defined by magnetic resonance imaging before and after revascularization. *Magn Reson Imaging* 2004;22:229-36.
23. Baer FM, Theissen P, Crnac J, Schmidt M, Deutsch HJ, Sechtem U, et al. Head to head comparison of dobutamine transoesophageal echocardiography and dobutamine-magnetic resonance imaging for the prediction of left ventricular functional recovery in patients with chronic coronary artery disease. *Eur Heart J* 2000;21:981-91.
24. Gunning MG, Anagnostopoulos C, Knight CJ, Pepper J, Burman ED, Davies G, et al. Comparison of 201Tl, 99mTc-tetrofosmin, and dobutamine magnetic resonance imaging for identifying hibernating myocardium. *Circulation* 1998;98:1869-74.
25. Sayad DE, Willett DL, Hundley WG, Grayburn PA, Peshock RM. Dobutamine magnetic resonance imaging with myocardial tagging quantitatively predicts improvement in regional function after revascularization. *Am J Cardiol* 1998;82:1149-51, A10.
26. Sandstede JJ, Bertsch G, Beer M, Kenn W, Werner E, Pabst T, et al. Detection of myocardial viability by low-dose dobutamine cine MR imaging. *Magn Reson Imaging* 1999;17:1437-43.
27. Trent RJ, Waiter GD, Hillis GS, McKiddie GS, Redpath FI, Walton TW. Dobutamine magnetic resonance imaging as a predictor of myocardial functional recovery after revascularisation. *Heart* 2000;83:40-6.
28. Van Hoe L, Vanderheyden M. Ischemic cardiomyopathy: value of different MRI techniques for prediction of functional recovery after revascularization. *Am J Roentgenol* 2004;182:95-100.
29. Wellnhofer E, Olariu A, Klein C, Grafe M, Wahl A, Fleck E, et al. Magnetic resonance low-dose dobutamine test is superior to scar quantification for the prediction of functional recovery. *Circulation* 2004;109:2172-4.
30. Kuehl HP, Lipke CS, Krombach GA, Katoh M, Battenberg TF, Nowak B, et al. Assessment of reversible myocardial dysfunction in chronic ischemic heart disease: comparison of contrast-enhanced cardiovascular magnetic resonance and a combined positron emission tomography-single photon emission computed tomography imaging protocol. *Eur Heart J* 2006;27:846-53.
31. Kim RJ, Wu E, Rafael A, Chen EL, Parker MA, Simonetti O, et al. The use of contrast-enhanced magnetic resonance imaging to identify reversible myocardial dysfunction. *N Engl J Med* 2000;343:1445-53.
32. Selvanayagam JB, Kardos A, Francis JM, Wiesmann F, Petersen SE, Taggart DP, et al. Value of delayed-enhancement cardiovascular magnetic resonance imaging in predicting myocardial viability after surgical revascularization. *Circulation* 2004;110:1535-41.
33. Pagano D, Bosner RS, Townend JN, Ordoubadi F, Lorenzoni R, Camici PG. Predictive value of dobutamine echocardiography and positron emission tomography in identifying hibernating myocardium in patients with postischemic heart failure. *Heart* 1998;79:281-8.
34. Nagel E, Lehmkuhl HB, Klein C, Schneider U, Frantz E, Ellmer A, et al. Influence of image quality on the diagnostic accuracy of dobutamine stress magnetic resonance imaging in comparison with dobutamine stress echocardiography for the non-invasive detection of myocardial ischemia. *Z Kardiol* 1999;88:622-30.
35. Nagel E. Dobutamine stress MR. In: Nagel E, Van Rossum AC, Fleck E, editors. *Cardiovascular magnetic resonance*. Darmstadt: Steinkopff Verlag 2004. p. 169-79.
36. Nagel E. Stress cine MR. In: Kwong RY, editor. *Cardiovascular magnetic resonance imaging*. Totowa, New Jersey: Humana Press Inc; 2008. p. 388-9.
37. Schinkel AFL, Poldermans D, Elhendy A, Bax JJ. Assessment of myocardial viability in patients with heart failure. *J Nucl Med* 2007;48:1135-46.
38. Lima JAC, Judd RM, Bazile A, Schulman SP, Atalar E, Zerhouni EA. Regional heterogeneity of human myocardial infarcts demonstrated by contrast-enhanced MRI. Potential mechanisms. *Circulation* 1995;92:1117-25.
39. Kim RJ, Fieno DS, Parrish TB, Harris K, Chen EL, Simonetti O, et al. Relationship of MRI delayed contrast enhancement to irreversible injury, infarct age, and contractile function. *Circulation* 1999;100:1992-2002.

40. Fieno DS, Kim RJ, Chen EL, Lomasney JW, Klocke FJ, Judd RM. Contrast-enhanced magnetic resonance imaging of myocardium at risk: distinction between reversible and irreversible injury throughout infarct healing. *J Am Coll Cardiol* 2000;218:215-23.
41. Arai AE. Myocardial infarction and viability with an emphasis on imaging delayed enhancement. In: Kwong RY, editor. *Cardiovascular magnetic resonance imaging*. Totowa, New Jersey: Humana Press Inc; 2008. p. 351-75.
42. Mahrholdt H, Wagner A, Holly TA, Elliott MD, Bonow RO, Kim RJ, et al. Reproducibility of chronic infarct size measurement by contrast-enhanced magnetic resonance imaging. *Circulation* 2002;106:2322-7.
43. Ramani K, Judd RM, Holly TA, Parrish TB, Rigolin VH, Parker MA, et al. Contrast magnetic resonance imaging in the assessment of myocardial viability in patients with stable coronary artery disease and left ventricular dysfunction. *Circulation* 1998;98:2687-94.
44. Klein C, Nekolla SG, Bengel FM, Momose M, Sammer A, Haas F, et al. Assessment of myocardial viability with contrast enhanced magnetic resonance imaging: comparison with positron emission tomography. *Circulation* 2002;105:162-7.
45. Kuehl HP, Beek AM, van der Weerd AP, Hofman MB, Visser CA, Lammertsma AA, et al. Myocardial viability in chronic ischemic heart disease: comparison of contrast-enhanced magnetic resonance imaging with (18)F-fluorodeoxyglucose positron emission tomography. *J Am Coll Cardiol* 2003;41:1341-8.
46. Kaandorp TA, Bax JJ, Schuijf JD, Viergever EP, Der Wall EE, de Roos A, et al. Head-to-head comparison between contrast-enhanced magnetic resonance imaging and dobutamine magnetic resonance imaging in men with ischemic cardiomyopathy. *Am J Cardiol* 2004;93:1461-4.
47. Bodi V, Sanchis J, Lopez-Lereu MP, Losada A, Nunez J, Pellicer M, et al. Usefulness of a comprehensive cardiovascular magnetic resonance imaging assessment for predicting recovery of left ventricular wall motion in the setting of myocardial stunning. *J Am Coll Cardiol* 2005;46:1747-52.
48. Bove CM, DiMaria JM, Voros S, Conaway MR, Kramer CM. Dobutamine response and myocardial infarct transmural: functional improvement after coronary bypass grafting – initial experience. *Radiology* 2006;240:835-41.
49. Sensky PER, Samani NJ, Horsfield MA, Cherryman GR. Restoration of myocardial blood flow following percutaneous coronary balloon dilatation and stent implantation: assessment with qualitative and quantitative contrast-enhanced magnetic resonance imaging. *Clin Radiol* 2002;57:593-9.
50. Sanstede JJ, Lipke C, Beer M, Harre K, Pabst T, Kenn W, et al. Analysis of first-pass and delayed contrast-enhancement patterns of dysfunctional myocardium on MR imaging: use in the prediction of myocardial viability. *Am J Roentgenol* 2000;174:1737-40.
51. Arai AE, Hsu L. Myocardial perfusion using first-pass gadolinium-enhanced cardiac magnetic resonance. In: Kwong RY, editor. *Cardiovascular magnetic resonance imaging*. Totowa, New Jersey: Humana Press Inc.; 2008. p. 313-29.
52. Kuehl HP, Van der Weerd A, Beek A, Visser F, Hanrath P, Van Rossum A. Relation of end-diastolic wall thickness and the residual rim of viable myocardium by magnetic resonance imaging to myocardial viability assessed by fluorine-18 deoxyglucose positron emission tomography. *Am J Cardiol* 2006;97:452-7.
53. Isbell DC, Kramer CM. Magnetic resonance for the assessment of myocardial viability. *Curr Opin Cardiol* 2006;21:469-72.

Received 5 November 2008, accepted 6 August 2009

Straipsnis gautas 2008 11 05, priimtas 2009 08 06