

## Experience of acetylcholinesterase histochemistry application in the diagnosis of chronic constipation in children

Robertas Bagdzevičius, Vytautas Vaičekas<sup>1</sup>, Sigita Bagdzevičiūtė<sup>2</sup>

Department of Pediatric Surgery, <sup>1</sup>Institute of Anatomy,

<sup>2</sup>Faculty of Medicine, Kaunas University of Medicine, Lithuania

**Key words:** colonic dysganglionosis; Hirschsprung's disease; intestinal neuronal dysplasia; constipation; acetylcholinesterase.

**Summary.** The aim of this study was to review our experience in applying acetylcholinesterase histochemistry for diagnosing colonic dysganglionoses in children.

**Patients and methods.** We analyzed acetylcholinesterase histochemistry results of rectal biopsy specimens obtained from 85 children. The indications for biopsy were suspicion of Hirschsprung's disease in neonates and infants (Group 1; n=21) and older children (Group 2; n=17); megarectum (Group 3; n=44); and colostomy (Group 4; n=3). Specimens were taken at 5 and 10 cm using endoscopic forceps or excised with scissors at 2.5 cm above the dentate line. Acetylcholinesterase activity was evaluated using Karnovsky-Roots method.

**Results.** The diagnosis of Hirschsprung's disease was confirmed in 17 children of the first group and in 3 of the second group. In the third group, 2 children were diagnosed with ultrashort-segment Hirschsprung's disease and 3 children with intestinal neuronal dysplasia. In one case, acetylcholinesterase reaction was false positive. Hirschsprung's disease was diagnosed in 2 children with colostomies; in one case acetylcholinesterase activity caused false-positive results. Colonic dysganglionoses were diagnosed in 78% of infants and in 14% of children over 1 year of age. The diagnostic specificity of acetylcholinesterase in Hirschsprung's disease was 92%.

**Conclusions.** 1) The analysis of acetylcholinesterase activity in children's rectal biopsy specimens is a reliable method for diagnosing Hirschsprung's disease, especially in infants; 2) This method of examination is irreplaceable in diagnosing ultrashort-segment Hirschsprung's disease and remains the only method to confirm the diagnosis of this disease; 3) Acetylcholinesterase histochemistry is not sufficiently informative in diagnosing intestinal neuronal dysplasia type B, because authors applying other neurohistochemical investigation methods have reported higher incidence of this disease.

### Introduction

Chronic constipation is a common and persistent problem in childhood, accounting for approximately 3–5% of visits to pediatric outpatient clinics and 10–20% of visits to pediatric gastroenterology clinics (1, 2). Although 40–50% of childhood cases respond to drug treatment, in many children the constipation remains refractory to drug therapy (2). In these cases, all organic causes for constipation such as anatomical (colonic stenosis, duplication, etc.) or neurological (Hirschsprung's disease (HD), intestinal neuronal dysplasia (IND), etc.) abnormalities, endocrine and metabolic causes should be considered (1).

Traditionally, the diagnosis of HD is made by means of a full-thickness rectal biopsy and confirmation of

the absence of ganglion cells in Auerbach's plexus, but this is associated with some morbidity and technical difficulties. Since the development of rectal suction biopsy technique by Noblett (1969) (3) and the introduction of acetylcholinesterase (AChE) histochemistry by Meier-Ruge *et al.* (1972) (4), which have demonstrated that the absence of ganglion cells in Meissner's plexus and increased AChE activity in lamina propria mucosae are specific to HD, AChE histochemical staining of rectal suction biopsies has gradually replaced conventional full-thickness biopsy at many institutions. When histochemical AChE and dehydrogenase reactions were introduced in the routine diagnosis of HD, more abnormalities of the submucosal plexus, clinically resembling HD, were identified. These entities were

grouped under the designation of colonic dysganglionoses and included HD, IND type A and B, hypoganglionosis, immaturity of ganglion cells, and a group of less well-characterized conditions. The above-mentioned colonic dysganglionoses can be either isolated or associated and may be related to a common pathogenesis. It is widely accepted that the pathological diagnosis can only be made through special histochemical and/or immunohistochemical methods (5, 6). Though the value of these methods is undoubted for diagnosing HD, the diagnosis of other dysganglionoses is still under discussions.

The aim of this study was to review our experience in applying acetylcholinesterase histochemistry in rectal biopsy specimens in diagnosing colonic dysganglionoses in children.

### Patients and methods

We analyzed AChE histochemistry test results of rectal biopsy specimens obtained from 85 children treated in the Department of Pediatric Surgery of Kaunas University of Medicine Hospital from 1991 to 2004. All patients presented with bowel obstruction or chronic constipation. According to indications (bowel obstruction in neonates and infants; dilatation of sigmoid colon or megarectum in older children; colostomy) for rectal mucosal-submucosal biopsy, children were divided into four groups. In Group 1, 21 neonates and infants having clinical, ultrasound, and radiological symptoms suggesting HD (constipation since birth, distended abdomen, sigmoid colon is wider than the rectum in the ultrasound or x-ray examinations) were examined. Their ages ranged from 2 weeks to 10 months (mean age 3 months). In Group 2, 17 children with constipation refractory to drug therapy, when hydrocolonoscopy revealed that sigmoid colon was wider than the rectum, and irregular rectoanal inhibitory reflex was discovered during anorectal manometry test, were examined. Their ages ranged from 1 to 10 years (mean age 4.5 years). In Group 3, 44 children with megarectum, diagnosed by hydrocolonoscopy and having irregular rectoanal inhibitory reflex that was discovered during anorectal manometry test, were examined. Long-term drug treatment of chronic constipation in these patients was ineffective. Their ages ranged from 3 to 12 years (mean age 6.5 years). In Group 4, two children who had colostomies performed because of low large-bowel obstruction at the first days of their lives (they were examined at the age of 1 month) and one 7-year-old patient who has been operated on for bowel obstruction in infancy were examined.

Before the biopsy procedure, children had one

cleansing enema in the evening and one in the morning. Biopsies in younger children were performed under general anesthesia, in older children without it. The endoscope was inserted into the rectum 5 and 10 cm above the dentate line, and rectal biopsies containing mucosa and submucosa were taken using endoscopic forceps. Additionally bowel tissue was excised with surgical scissors using rectal speculum at 2.5 cm above the dentate line. No profuse bleeding from the biopsy places was identified after the procedure.

All the samples were frozen immediately in liquid nitrogen. In the pathology laboratory, the samples were mounted on cryostat carriers exactly vertical to the surface of the mucosa and cut in serial 10- $\mu$ m-thick sections. AChE staining was done according to the method of Karnovsky and Roots (7) (substratum, acetylcholine iodide; pH of the incubation medium, 5.5–5.6; incubation time, 1.5 hours). AChE reaction in the mucosal layer was evaluated according to these features:

1. Negative AChE reaction – no AChE-positive nerve fibers in the lamina propria mucosae and muscularis mucosae (Fig. 1);
2. Slightly positive AChE reaction – there are AChE-positive nerve fibers in the muscularis mucosae, and some fibers run transversely to the lamina propria mucosae;
3. Positive AChE reaction – a thick network of AChE-positive nerve fibers in the muscularis mucosae and lamina propria mucosae (Fig. 2).

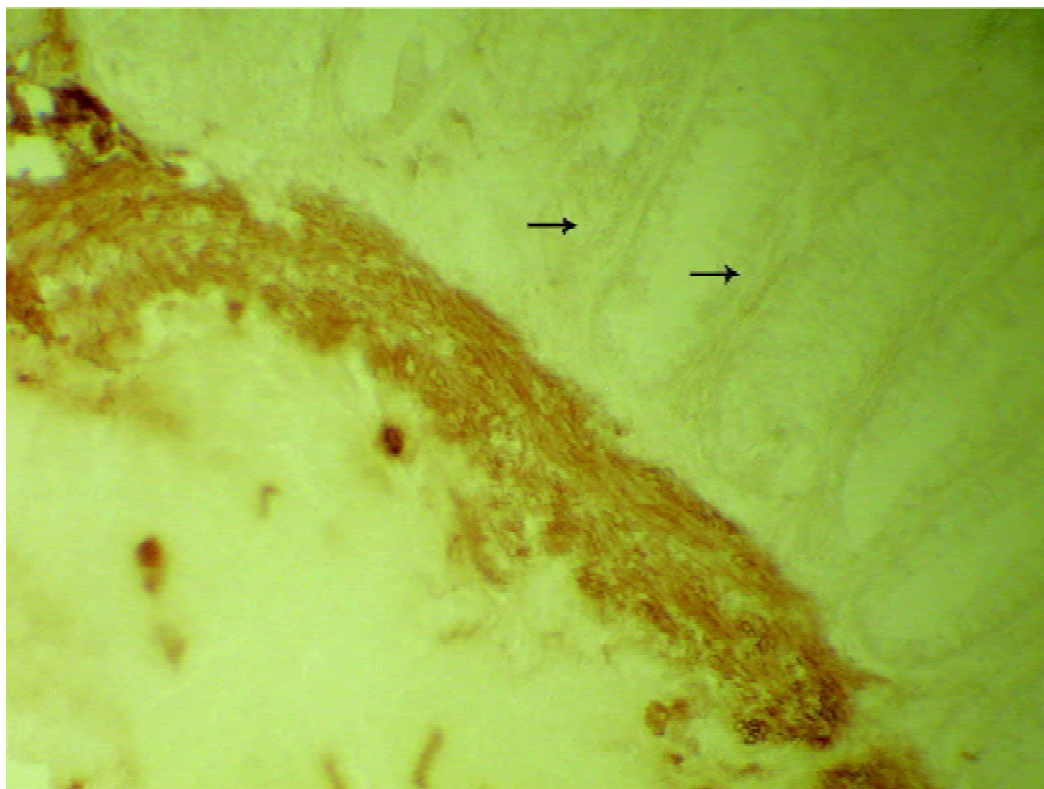
We also evaluated submucosal ganglia (Fig. 3).

According to the pathologists' consensus (8), these diseases were diagnosed based on biopsy specimen examination.

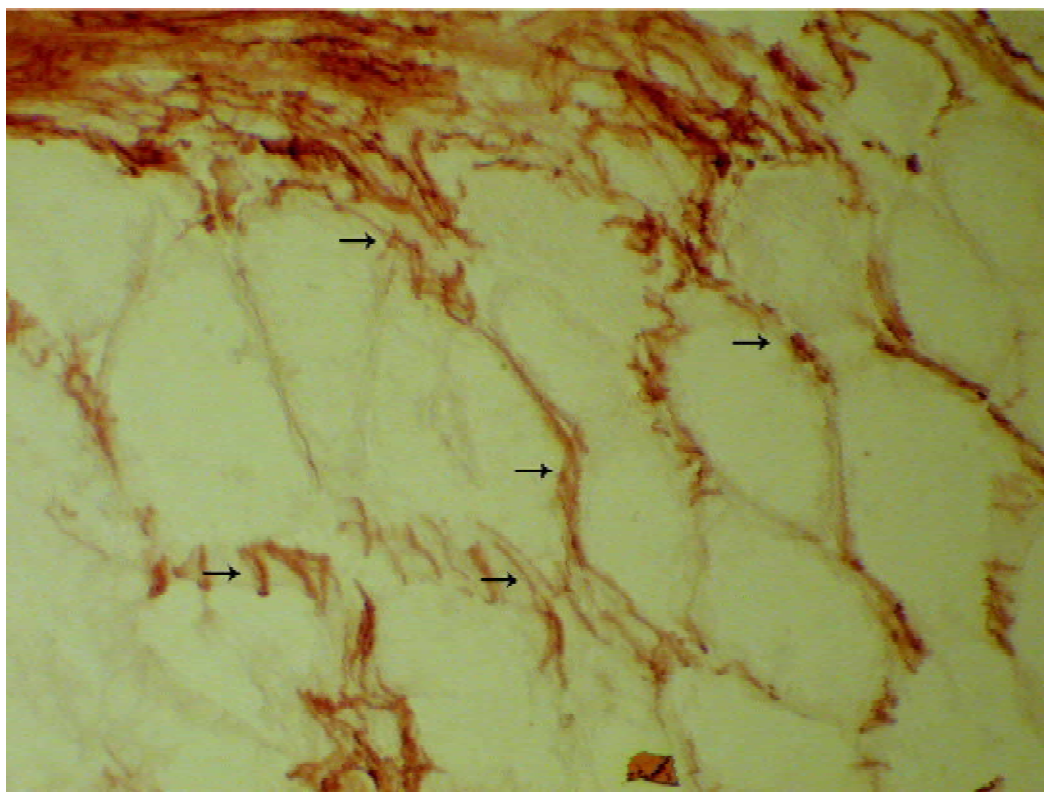
HD is characterized by profuse nerve plexuses in the submucosa, muscularis mucosae and nerve fibers running transversely and making a network in the lamina propria mucosae. All of these nerve plexuses have very intense AChE activity. There are no ganglia in the submucosa. These alterations are identified in all biopsy specimens (2.5, 5, and 10 cm above the dentate line).

Ultrashort-segment Hirschsprung's disease (UHD) shows networks of parasympathetic nerve fibers with increased AChE activity only in the muscularis mucosae. In the submucosa, many thick nerve fibers with high AChE activity are observed. These alterations are observed in biopsies taken at 2.5 cm above the dentate line, while in biopsies taken at 5 and 10 cm above the dentate line, AChE reaction in the mucosal layer is negative.

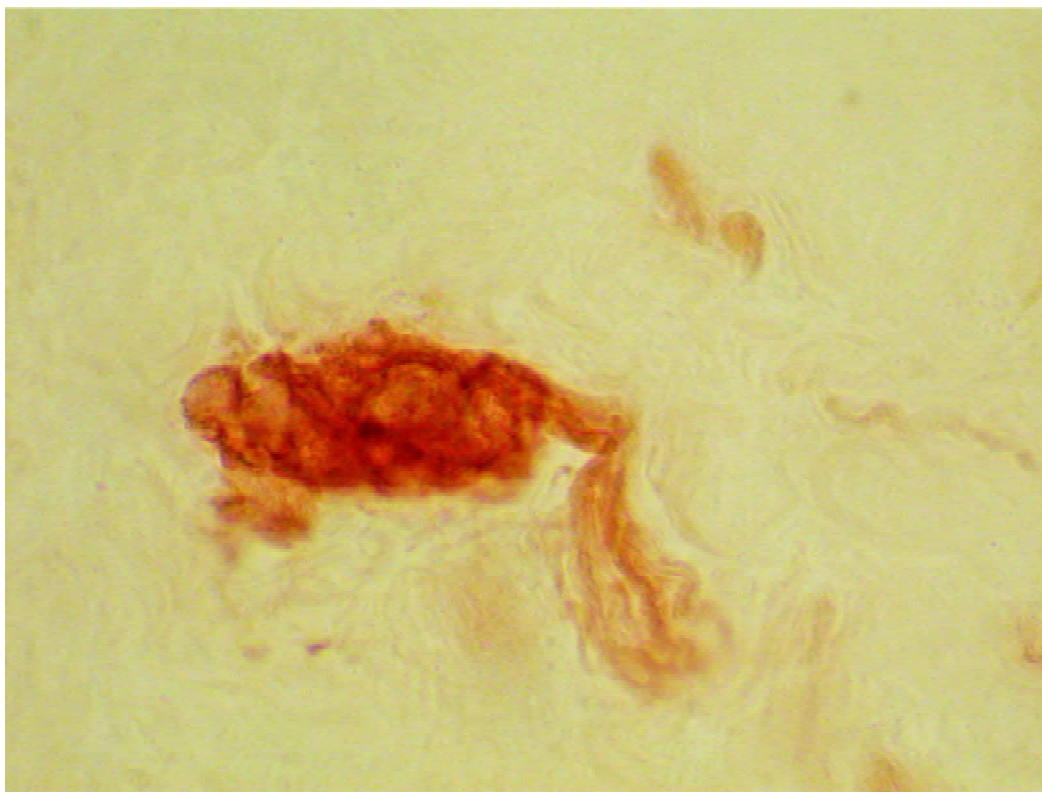
IND is characterized by profuse nervous plexuses



**Fig. 1. Acetylcholinesterase staining of healthy subject (original magnification  $\times 400$ )**  
The proliferation of acetylcholinesterase-positive fibers is not seen in lamina propria mucosae.



**Fig. 2. Acetylcholinesterase staining in Hirschsprung's disease (original magnification  $\times 400$ )**  
The proliferation of acetylcholinesterase-positive fibers is seen in lamina propria, and thick fiber bundles are also seen in muscularis mucosa.



**Fig. 3. Acetylcholinesterase staining of normal case (original magnification  $\times 400$ )**

Several ganglion cells are found in submucosal layer.

in the submucosa, muscularis mucosae and nerve fibers running transversely and making a network in the lamina propria mucosae. All of these nervous plexuses have very intense AChE activity. As distinct from HD, massive nerve ganglia are observed in the submucosa.

A total of 255 biopsy specimens were examined, 170 of which were taken endoscopically with forceps and 85 were excised with scissors. Only 54 specimens taken with forceps included submucosa. These biopsies were taken from children under 2 years of age. All biopsy specimens excised with scissors included mucosa and submucosa.

### Results

In Table, results of AChE histochemistry in rectal biopsy specimens are presented in summary.

In the first group, 16 (76%) of the 21 neonates and infants had neuromorphological alterations characteristic to HD. All of these patients were treated surgically. The diagnosis of HD was confirmed in all the cases. In five cases, AChE reaction was negative. The diagnosis of HD was not confirmed. All of these children recovered after drug treatment.

In the second group, neuromorphological alterations characteristic to HD were observed in 3 (18%) out of 17 children. They had had constipation since infancy.

All of these patients underwent radical operations and were confirmed to have HD pathologically. In 14 cases, AChE reaction was negative. The diagnosis of HD was not confirmed. All of these children recovered after drug treatment.

In the third group, negative AChE reaction was observed in 38 cases. The diagnosis of HD was not confirmed. In two cases, AChE reaction was positive in the biopsy specimens taken at 2.5 cm above the dentate line. UHD was diagnosed. Manual dilatations of the internal sphincters were performed under anesthesia, and positive clinical effects were achieved. In three cases, AChE reaction was positive in all biopsy specimens, but massive nerve ganglia were observed in the submucosa. IND type B was diagnosed. These children received drug treatment, and clinical effects were positive. One girl at the age of 7 years had a slightly positive AChE reaction in all biopsy specimens. Additional x-ray examinations did not help to clarify the diagnosis. During laparotomy, tubular duplication of the ascending colon was found, and this segment of the colon was resected. The girl has recovered. Dysganglionoses were diagnosed in 5 (11%) out of 44 children; in one case, the AChE reaction was false positive.

In the fourth group, a positive AChE reaction was observed in the biopsy specimens taken from the infant

who had a colostomy because of low large-bowel obstruction at the age of 4 days. The diagnosis of HD was confirmed after the conventional histological analysis of the colonic segment resected during the surgery. In the other case of an infant who had had a colostomy for low large-bowel obstruction at the age of 3 days, all biopsy specimens showed positive reaction for AChE. During the surgery, a segment of a colon was removed, and after the examination of this segment, massive ganglia were found in the submucosa. IND type B was diagnosed. A 7-year-old boy who had been operated on in infancy in other hospital for a bowel obstruction of unknown cause in our hospital underwent a surgery for mechanical ileus. During the surgery, alterations of the left colon characteristic to the long-segment HD were observed. Colostomy was performed. Positive AChE reaction was identified in the biopsy specimens, and the diagnosis of HD was confirmed. Left hemicolectomy was performed, and the boy has recovered. Dysganglionoses were diagnosed in 3 (100%) out of 3 children. AChE reaction in diagnosing HD was false positive.

The diagnoses of dysganglionoses were established by biopsies more frequently in neonates and infants (Fig. 4). The difference in the results between the second and third patient groups was not statistically significant ( $P>0.05$ ). The dilatation of sigmoid colon and megarectum were equally significant symptoms when selecting children for the biopsy procedure.

The diagnostic specificity of AChE in HD was 92% (23 out of 25).

## Discussion

The indications for mucosal-submucosal rectal

biopsies are still under discussions (1, 2, 9, 10). Ghosh and Griffiths state that if the onset of constipation is after the neonatal period, the child is unlikely to have Hirschsprung's disease, and therefore a rectal biopsy is unnecessary (9). Other authors partially agree with this statement and present following indications for rectal biopsies in children before 6 months of age: (a) failure to pass meconium within 48 hours; (b) low intestinal obstruction of unknown cause; (c) severe constipation; (d) chronic abdominal distention; (e) failure to thrive (1). Even if the biopsy results are normal in the neonatal period, careful clinical follow-up is required, and in the case of persistent symptoms, the repeated mucosal biopsy at the age of 6 months is recommended (10). In infants under 1 year of age, the diagnosis of HD is confirmed by AChE histochemistry in 43–45% of biopsies (1, 9, 10). On the other hand, most constipated children aged more than 6 months (90% to 95%) have functional constipation; therefore, the biopsy should be performed only after thorough anamnesis is obtained, the child is examined carefully, blood tests helping to exclude endocrine causes and electrolyte imbalances are performed, and adequate dietary and drug therapy is administered (1). Kobayashi determined an elevated AChE reaction in all mucosal layers in children with refractory constipation who did not have any other neuromorphological changes characteristic to dysganglionoses. He suggested using the term *AChE-positive disease* to describe these disorders and to treat this group of children surgically even if ganglion cells are normal (11). If the biopsy is taken, its results in the children over 1 year of age depend on the spectrum of analysis methods of biopsy specimens and pathological changes revealed

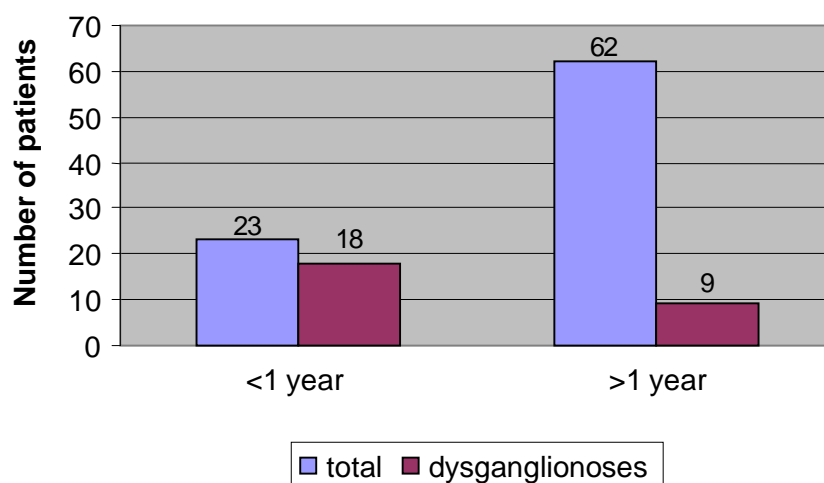


Fig. 4. Age at which rectal biopsies were performed

**Table. Results of acetylcholinesterase histochemistry**

Condition	Group 1 (n=21)	Group 2 (n=17)	Group 3 (n=44)	Group 4 (n=3)	Total (n=85)
Hirschsprung's disease	16	3	–	2	21
Ultrashort-segment Hirschsprung's disease	–	–	2	–	2
Intestinal neuronal dysplasia type B	–	–	3	1	4
Unaffected	5	14	39	–	58

by these methods. Ghosh and Griffiths used hematoxylin and eosin as well as AChE staining methods and diagnosed HD in 1.3% of examined children over 1 year of age (9). Meier-Ruge used AChE, lactate dehydrogenase, succinate dehydrogenase, and nitrooxide synthase staining methods and diagnosed colonic dysganglionoses in 75.9% of examined children (12). Therefore, the majority of authors state that mucosal-submucosal rectal biopsies should be taken in cases of severe, refractory constipations in order to exclude colonic dysganglionoses in children over 1 year of age (1, 2, 11–13). Our study also supports the opinion that using AChE histochemistry, bowel innervation disorders are diagnosed more often in neonates and infants than in children over 1 year of age. We diagnosed colonic dysganglionoses in 18 (78%) out of 23 infants and in 9 (14%) out of 62 children over 1 year of age.

When Noblett (1969) introduced rectal suction biopsy procedure, it became the most widely used diagnostic procedure for children with bowel motility disorders. This procedure does not require anesthetics and can be performed on the ward or in the outpatient clinic (1, 14, 15). The disadvantages of this procedure are as follows: it is performed blindly, and the biopsy site and thickness of the specimen may vary; feces and mucus may influence the thickness of the specimen; the thickness of the specimen may be insufficient because of edematous swollen mucosal layers following an x-ray examination or low-pressure suction (14, 15). Khan *et al.* have reported that suction rectal biopsy was not suitable for children over 1 year of age (1). Several studies have reported that 34% of biopsy specimens were insufficient as they did not include a substantial piece of submucosa (14, 15). Some authors have reported that an abnormal AChE reaction in the mucosal layer can be used for diagnosing HD (15, 16), but Kobayashi and coworkers state that such reaction can sometimes be found in normal bowel as well as in IND. Therefore, diagnostic rectal biopsies have to include sufficient submucosa to show the

submucosal plexuses (14). If IND is suspected, the biopsies should be taken endoscopically using large forceps, or bowel tissue should be excised with scissors or a scalpel (9, 13–15). According to our investigation, in 32% of cases, the thickness of the biopsy specimens taken endoscopically with forceps was sufficient. These specimens were taken from children younger than 2 years of age. Biopsies taken using scissors were adequate in all cases. Noblett recommended that specimens should be taken 3 to 4 cm from the anal valves. Kobayashi and coworkers recommended that specimens should be taken 2 cm above the dentate line, and biopsies above that level are unnecessary (14). Meanwhile, Meier-Ruge states that alterations characteristic to IND are found no closer than 7 cm above the dentate line (13). To diagnose UHD, biopsies must be taken at 1, 2, 4, and 6 cm above the dentate line (17).

Most authors report that AChE staining of a rectal mucosal biopsy is essential for a definite diagnosis of HD, especially when barium enema and anorectal manometry tests are not informative (total colonic aganglionosis, short-segment HD, neonatal age, or children with a colostomy) (10). HD is characterized by profuse nerve plexuses in the submucosa, muscularis mucosae and nerve fibers running transversely and making a network in the lamina propria mucosae. All of these nerve plexuses have very high AChE activity. There are no ganglia in the submucosa (1, 6, 10, 16, 18, 19). A number of studies have reported a 99–100% diagnostic accuracy for HD using the criteria of increased AChE staining of nerve fibers in the lamina propria and muscularis mucosae (16). False-positive results are obtained analyzing hemorrhagic specimens, as the red blood cell membrane contains high concentration of AChE (16). False-negative results are associated with the patient's age. Abnormal AChE activity was identified only in 83% of infants less than 3 months of age (10, 16). Above-mentioned morphological alterations are detected only in the distal parts of colon below the lienal flexure, because this part of large bowel



receives parasympathetic innervation from the medullar S2–S4 segments. Therefore, AChE staining of the ascending and transversal colon biopsy specimens is not informative. This explains false-negative results of AChE staining in children with total colonic aganglionosis (16, 19). In our study, we detected 2 (7.1%) cases with false-positive results of the 28. In one case, a weak positive AChE reaction was found examining a child with large bowel duplication. In another case, an infant with IND was examined, and the ganglia in submucosal plexus were evaluated inadequately. No false-negative results were found.

UHD can only be reliably diagnosed by AChE reaction in native mucosal biopsies of the distal colon. UHD cannot be diagnosed without this procedure (17, 19). As distinct from the long-segment HD, fibers with high AChE activity are detected in the muscularis propria mucosa and submucosa. Absence of nerve ganglia in the submucosa does not prove the presence of UHD, because in the very distal part of rectum and anal segment, ganglia are rarely seen even in healthy patients (17, 19). Biopsies must be taken at the dentate line and 1, 2, 4, and 6 cm above the dentate line. At 5–6 cm above the dentate line, normal muscularis mucosae are seen. If a biopsy 6 cm above the dentate line still shows nets of nerve fibers with increased AChE activity in the muscularis mucosae and lamina propria mucosae, a long-segment HD or a total colonic aganglionosis can be expected (17, 19). It is determined that the rectum develops in the craniocaudal direction during the first months of person's life. UHD diagnosed in the first 2 months of life may evolve into a short-segment HD (5–6 cm in length) up to the first or second year of life, which renders a resection of the rectum. Therefore, a control biopsy 2 years after the first diagnosis is recommended (17). UHD makes up 8.9–13.4% of all aganglionoses diagnosed by experienced pathologists (12, 17, 19). In our investigation, UHD was observed in 2 (8.7%) out of 23 cases. Clinical symptoms and megarectum were not informative in diagnosing UHD.

IND is being mostly discussed. Various authors have reported different opinions. Csury and Peña have performed a literature review and questioned the validity of diagnosis of this disease (20). Koletzko and coworkers after a prospective multicenter study have reported a high interobserver variation with regard to the different morphological features and final diagnosis of IND (22). Meier-Ruge has clearly defined clinical symptoms, diagnostic criteria, and treatment methods

of IND and has reported that this disease make up 40.6% of all dysganglionoses (5, 12, 21). There are other authors who agree with Meier-Ruge (6, 23, 24). Schmittenbecher *et al.* have reported that rectal suction biopsy is a well-accepted diagnostic procedure to prove IND (15). Kobayashi and coworkers have stated that full-thickness rectal biopsy is necessary for diagnosing IND (23). Although some authors (23) report that IND can be diagnosed by AChE staining, most of the scientists acknowledge that other staining methods of biopsy specimens (hematoxylin and eosin, lactate dehydrogenase, succinate dehydrogenase, and nitrooxide synthase staining methods) and immunohistochemical methods are necessary (5, 6, 13, 15, 21, 22, 24). Universally accepted diagnostic criteria for diagnosing IND are as follows: 1) Hyperplasia of nerve plexuses in the submucous layer. These plexuses reach muscularis mucosa and lamina propria mucosa. High AChE activity is observed in all of these plexuses. 2) Giant nerve ganglia containing seven and more ganglion cells are observed in the submucous and myenteric plexuses (5, 6, 12, 13, 15, 21, 22, 24). Other structural changes in the nerve cells of the colon are also observed (6). It has been reported that structural alterations are associated with the patient's age and change as the patient matures (5, 6, 12, 13, 15, 21–24). IND may be associated with HD and may influence poor postoperative results (24). During our investigation, IND was diagnosed in three cases according to the results of rectal biopsy. In one case, the false-negative result was obtained, and the diagnosis was confirmed after the surgery. In our study, IND totaled 4 (14.8%) out of all 27 cases with dysganglionoses.

### Conclusions

1. The analysis of acetylcholinesterase activity in children's rectal biopsy specimens is a reliable method for diagnosing Hirschsprung's disease, especially in infants and in the cases of constipation refractory to medical therapy;
2. This method of examination is irreplaceable in diagnosing ultrashort-segment Hirschsprung's disease and remains the only method to confirm the diagnosis of this disease;
3. Acetylcholinesterase histochemistry is not sufficiently informative in diagnosing intestinal neuronal dysplasia type B, because authors applying other neurohistochemical investigation methods have reported higher incidence of this disease.

## Acetilcholinesterazės histocheminio tyrimo metodo naudojimo patirtis diagnozuojant vaikų lėtinį vidurių užkietėjimą

Robertas Bagdzevičius, Vytautas Vaičekas<sup>1</sup>, Sigita Bagdzevičiūtė<sup>2</sup>

Kauno medicinos universiteto Vaikų chirurgijos klinika,

<sup>1</sup>Anatomijos institutas, <sup>2</sup>Medicinos fakultetas

**Raktažodžiai:** žarnų disgangliozė, Hiršprungo liga, žarnų neuroninė displazija, vidurių užkietėjimas, acetilcholinesterazė.

**Santrauka.** Darbo tikslas. Apibendrinti tiesiosios žarnos biopsinių preparatų acetilcholinesterazės aktyvumo tyrimo svarbą diagnozuojant vaikų disgangliozes.

*Tirtųjų kontingentas ir tyrimo metodai.* Analizavome 85 vaikų tiesiosios žarnos biopsinių preparatų tyrimo duomenis. Indikacijos tyrimui buvo Hiršprungo ligos įtarimas naujagimiams ir kūdikiams (I gr. n.=21) bei vyresniems vaikams (II gr. n.=17), tiesiosios žarnos išsiplėtimas (III gr. n.=44) ir kolostoma (IV gr., trys vaikai). Tiriamoji medžiaga buvo imama rektoskopinėmis biopsinėmis žnyplėmis 10 cm ir 5 cm bei žirkutėmis 2,5 cm atstumu nuo dantytosios linijos. Acetilcholinesterazės aktyvumas tirtas Karnovskio-Ruts metodu.

*Rezultatai.* Pirmoje grupėje – 17 vaikų; antroje – trys vaikai, kuriems patvirtinta Hiršprungo ligos diagnozė; trečioje – du vaikai, kuriems diagnozuota ultratrumpo segmento Hiršprungo liga, trims – B tipo neuroninė žarnų displazija, vienam – su tubuline storosios žarnos duplikacija tyrimas buvo klaidingai teigiamas. Dviem vaikams, kuriems nustatyta kolostoma, patvirtinta Hiršprungo ligos diagnozė, vienam vaikui tyrimas buvo klaidingai teigiamas. Žarnyno disgangliozė diagnozuota 18 (78 proc.) iš 23 kūdikių bei 9 (14 proc.) iš 62 vaikų vyresnių nei vienerių metų. Tyrimo specifiškumas, diagnozuojant Hiršprungo ligą, buvo 92 proc. (23 iš 25).

*Išvados.* Acetilcholinesterazės aktyvumo tyrimas yra patikimas Hiršprungo ligos diagnostikos metodas, ypač svarbus tiriant mažus vaikus bei tais atvejais, kai liga atspari vaistams. Šis tyrimas nepakeičiamas diagnozuojant ultratrumpo segmento Hiršprungo ligą, be to, yra vienintelis tyrimas, kuriuo šią ligą galima patvirtinti. Tyrimas nepakankamai informatyvus diagnozuojant B tipo neuroninę žarnyno displaziją, nes autoriai, naudodę ir kitus neurohistocheminio tyrimo metodus, pateikia didesnę šios patologijos dažnį.

Adresas susirašinėti: R. Bagdzevičius, KMU Vaikų chirurgijos klinika, Eivenių 2, 50009 Kaunas  
El. paštas: robertas.bagdzevicius@kmuk.lt

### References

1. Khan AR, Vujanic GM, Huddart S. The constipated child: how likely is Hirschsprung's disease? *Pediatr Surg Int* 2003; 19:439-42.
2. Simpson BB, Ryan DP, Schnitzer JJ, Flores A, Doody DP. Surgical evaluation and management of refractory constipation in older children. *J Pediatr Surg* 1996;31(8): 1040-2.
3. Noblett HR. A rectal suction biopsy tube for use in the diagnosis of Hirschsprung's disease. *J Pediatr Surg* 1969;4:406-9.
4. Meier-Ruge W, Lutterbeck PM, Herzog B, Morger R, Moser R, Schärli A. Acetylcholinesterase activity in suction biopsies of the rectum in the diagnosis of Hirschsprung's disease. *J Pediatr Surg* 1972;7:11-7.
5. Meier-Ruge WA, Brönnimann PB, Gambazzi F, Schmidt PC, Schmidt CP, Stoss F. Histopathological criteria for intestinal neuronal dysplasia of the submucosal plexus (type B). *Virchows Arch* 1995;426:549-56.
6. Nogueira A, Campos M, Soares-Oliveira M, Estevão-Costa J, et al. Histochemical and immunohistochemical study of the intrinsic innervation in colonic dysganglionosis. *Pediatr Surg Int* 2001;17:144-51.
7. Karnovsky MJ, Roots L. A "direct coloring" thiocholine method of cholinesterase. *J Histochem Cytochem* 1964;12:219-21.
8. Borchard E, Meier-Ruge W, Wiebecke B, Briner J, Müntefering H, Födisch HJ, et al. Innervationsstörungen des Dickdarms – Klassifikation und Diagnostik. (Disorders of the innervation of the large intestine: classification and diagnosis.) *Pathologe* 1991;12:171-4.
9. Ghosh A, Griffiths DM. Rectal biopsy in the investigation of constipation. *Arch Dis Child* 1998;79:266-8.
10. Nakao M, Suita S, Taguchi T, Hirose R, Shima Y. Fourteen-year experience of acetylcholinesterase staining for rectal mucosal biopsy in neonatal Hirschsprung's disease. *J Pediatr Surg* 2001;36(9):1357-63.
11. Kobayashi H, Zhixin L, Yamataka A, Lane GJ, Yokota H, Watanabe A, et al. Acetylcholinesterase distribution and refractory constipation – a new criterion for diagnosis and management. *Pediatr Surg Int* 2002;18:349-53.
12. Meier-Ruge W. Epidemiology of congenital innervation defects of the distal colon. *Virchows Archiv A Pathol Anat* 1992;420: 171-7.
13. Meier-Ruge W, Schmidt Ch. Diagnostik und Verlauf der Neuronalen Intestinalen Dysplasie des Kindes. (Diagnostics and course of intestinal neuronal dysplasia in children.) *Zentralbl Kinderchir* 1994;4:161-71.
14. Kobayashi H, Zhixin L, Yamataka A, Lane GJ, Miyano T. Rectal biopsy: what is the optimal procedure? *Pediatr Surg Int* 2002;18:753-56.



15. Schmittenbecher PP, Schmidt A, Meier-Ruge W, Wiebecke B. Rectal suction biopsy: can it be sufficient to diagnose neuronal intestinal dysplasia? *Eur J Pediatr Surg* 1995;5:277-9.
16. Moore SW, Johnson G. Acetylcholinesterase in Hirschsprung's disease. *Pediatr Surg Int* 2005;21:255-63.
17. Meier-Ruge WA, Bruder E, Holschneider AM, Lochbühler H, Piket G, Posselt HG, et al. Diagnosis and therapy of ultrashort Hirschsprung's disease. *Eur J Pediatr Surg* 2004;14:392-7.
18. Byard RW, Carli M. Temporal stability of acetylcholinesterase staining in colonic and rectal neural tissue. *Pediatr Surg Int* 1998;13:29-31.
19. Meier-Ruge W. Die enzymhistochemische Biopsiediagnostik des Morbus Hirschsprung. (The diagnostics of Hirschsprung's disease by biopsy specimen enzyme histochemistry.) *Zentralbi Kinderchir* 1994;3:119-25.
20. Csury L, Peña A. Intestinal neuronal dysplasia. Myth or reality? Literature review. *Pediatr Surg Int* 1995;10:441-6.
21. Meier-Ruge WA, Ammann K, Bruder E, Holschneider AM, Schärli AF, Schmittenbecher PP, et al. Updated results on intestinal neuronal dysplasia (IND B). *Eur J Pediatr Surg* 2004;14:384-91.
22. Koletzko S, Jesch I, Faus-Keßler T, Briner J, Meier-Ruge W, Müntefering H, et al. Rectal biopsy for diagnosis of intestinal neuronal dysplasia in children: a prospective multicentre study on interobserver variation and clinical outcome. *Gut* 1999;44: 853-61.
23. Kobayashi H, Hirakawa H, Puri P. What are the diagnostic criteria for the intestinal neuronal dysplasia? *Pediatr Surg Int* 1995;10:459-64.
24. Schmittenbecher PP, Sacher P, Cholewa D, Haberlik A, Menardi G, Moczuiski J, et al. Hirschsprung's disease and intestinal neuronal dysplasia – a frequent association with implications for the postoperative course. *Pediatr Surg Int* 1999;15:553-58.

*Received 25 January 2006, accepted 9 October 2006*

*Straipsnis gautas 2006 01 25, priimtas 2006 10 09*