

KLINIKINIAI ATVEJAI

Lipoma of the greater omentum in a child

Vidmantas Barauskas, Dalius Malcius, Violeta Jazdauskienė

Department of Pediatric Surgery, Kaunas University of Medicine Hospital, Lithuania

Key words: lipoma, greater omentum.

Summary. Lipoma of the greater omentum is observed very rarely, particularly in the childhood. We report a case of large 10×11×8 cm asymptomatic lipoma of the greater omentum, which was diagnosed incidentally. Well-encapsulated mass with a homogeneous internal structure and high echogenicity – these signs of ultrasound and computed tomography allowed us to suggest a lipoma. At laparotomy lipoma of greater omentum in torsion was found. The excision of the tumor and omentectomy was performed. The histopathological diagnosis was lipoma with focal necrosis areas.

Introduction

Lipoma is a very common benign tumor, occurring throughout the whole body, while in general fat tissue tumors account for 6% of soft tissue tumors in the pediatric population (1). However, its incidence differs largely according to the organ, and lipoma of the greater omentum is very rare (2), almost exclusively described in case reports (1, 3–7).

Incidence of primary tumors of the greater omentum is also rare, nevertheless presenting with a wide range of pathology. The greater omentum mostly consists of the fat tissue with blood and lymphatic vessels involved. Therefore, in clinical practice there is a great variety of primary tumors of the greater omentum such as leiomyosarcoma, fibrosarcoma, heman-giopericytoma, liposarcoma, leiomyoma, lipoma, fibroma and mesothelioma (2, 8, 9). Among the above-mentioned tumors lipoma is probably the rarest one and only a few case reports were described in the literature (2). Even more seldom it is discovered in children (4). Usually lipoma of the greater omentum is an incidental finding with no clinical symptoms, sometimes discovered only at the autopsy (2). Rarely lipoma could cause the gastrointestinal complaints such as abdominal pain, nausea or vomiting. Those symptoms of acute abdomen usually occur due to the complication – torsion of the omentum (10, 11).

Lipoma of the greater omentum, as the other solid abdominal tumors, is easily discovered by the ultrasound (US), but for more precise localization and the internal structure of the tumor the computed tomog-

raphy (CT) scan should be always performed.

This is a case report of a greater omentum lipoma in a child.

Case report

Eight-year-old girl was consulted by a general practitioner (GP) due to fever of 38.5°C. Symptoms of viral infection were found; however, surprisingly the abdominal palpation revealed quite a big migratory mass. The US was performed, presence of the well-encapsulated tumor was confirmed and the patient was directed to the Center of Pediatric Surgery. At the examination the abdomen was soft, undistended, with no acute symptoms; however, there was a large palpable migratory tumor of 10×10 cm in diameter. The CT scan revealed a mass of 10×11×8 cm in size lying in the lower part of the abdomen and in the pelvis. The mass of a fatty consistence and sparse membranes inside had the defined borders. It dislocated the bowel upwards while the urinary bladder and the other pelvic organs were compressed. There was no inflammatory reaction from the surrounding tissue observed (Fig. 1). At laparotomy a 10×11×8 cm large tumor mass originating from the omentum was found. The lipoma was turned over its axis in 720 degrees. There were no clear symptoms of ischemia or tumor necrosis (Fig. 2). The mass was successfully removed together with the greater omentum. The postoperative course was uneventful. Histological examination showed that lipoma was composed of big mature adipose cells with the laterally displaced nuclei. The macro-

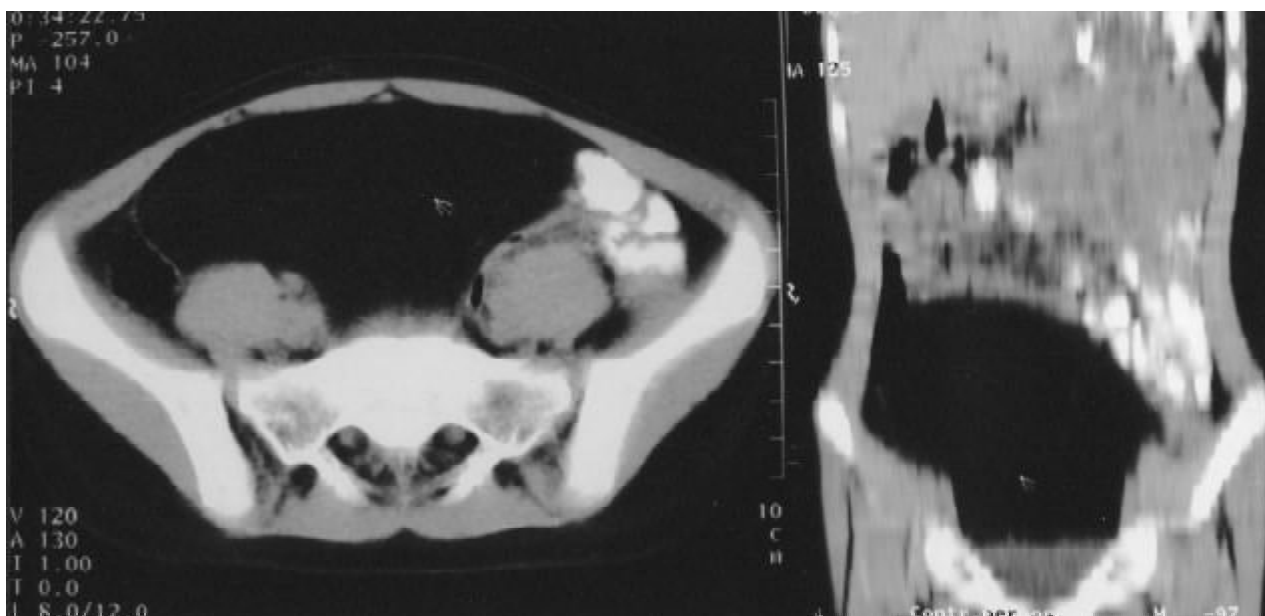


Fig. 1. CT showing intraperitoneal encapsulated mass

phages and giant cells with several nuclei were located near necrotic lipocytes. There were signs of inflammation (Fig. 3).

Discussion

Lipomas are composed of mature fat and are common mesenchymal tumors, however very little is known about their pathogenesis (12). They may occur in any part of the body but lipoma of the greater omentum is a rare finding, mostly described in case reports while the precise incidence is unknown (12). Most of the described intraperitoneal lipomas had an asymptomatic course and were discovered by accident (1–4, 13) and only a few cases presented with acute abdomen (7, 10, 11).

Abdominal pain or symptoms of intestinal obstruction could occur, if there is torsion of the mesenteric or the greater omentum lipoma (10, 11). We report a case of asymptomatic lipoma of the greater omentum diagnosed incidentally. Preoperatively the patient admitted only one short-lasting episode of abdominal pain, while the GP was consulted for symptoms of viral infection and fever. We would still call the course asymptomatic even though at the operation a torsion of the omentum by 720° was found. The torsion probably could have been intermittent so it did not provoke the clinical symptoms of acute abdomen since the blood supply was not severely disturbed. If the diagnosis of the abdominal mass is made on a random

basis, all patients routinely undergo the US examination, but actually it could mostly serve as a screening method helping to differentiate the solid tumor from the cystic lesion (2, 3, 5, 6). The authors suggest performing a CT scan in order to obtain a better localization and evaluation of the tumor. Well-demarcated mass with a homogeneous internal structure and high echogenicity were the useful US and CT signs allowing us to suggest a lipoma. Some authors also propose the color Doppler US and the angiography. Those methods could supply with valuable information about avascular origin of the mass (1). Almost nobody performs the magnetic resonance imaging (MRI) scan although from the theoretical point of view it could be very useful in diagnosis of adipose tumors. We think that the preoperative diagnosis is sufficient with US and CT scans since MRI, color Doppler US and angiography would not change the tactics of surgical treatment.

As regards the treatment of intraperitoneal lipomas all authors share the same opinion – it should be surgical. Technically intraperitoneal lipomas, particularly lipomas of the greater omentum are easily removed, tumor malignization is not common, therefore the operation itself is rather easy – excision of the tumor or / and omentectomy (4, 7, 10, 11, 13). We decided to perform excision of the tumor and omentectomy due to torsion of omentum.

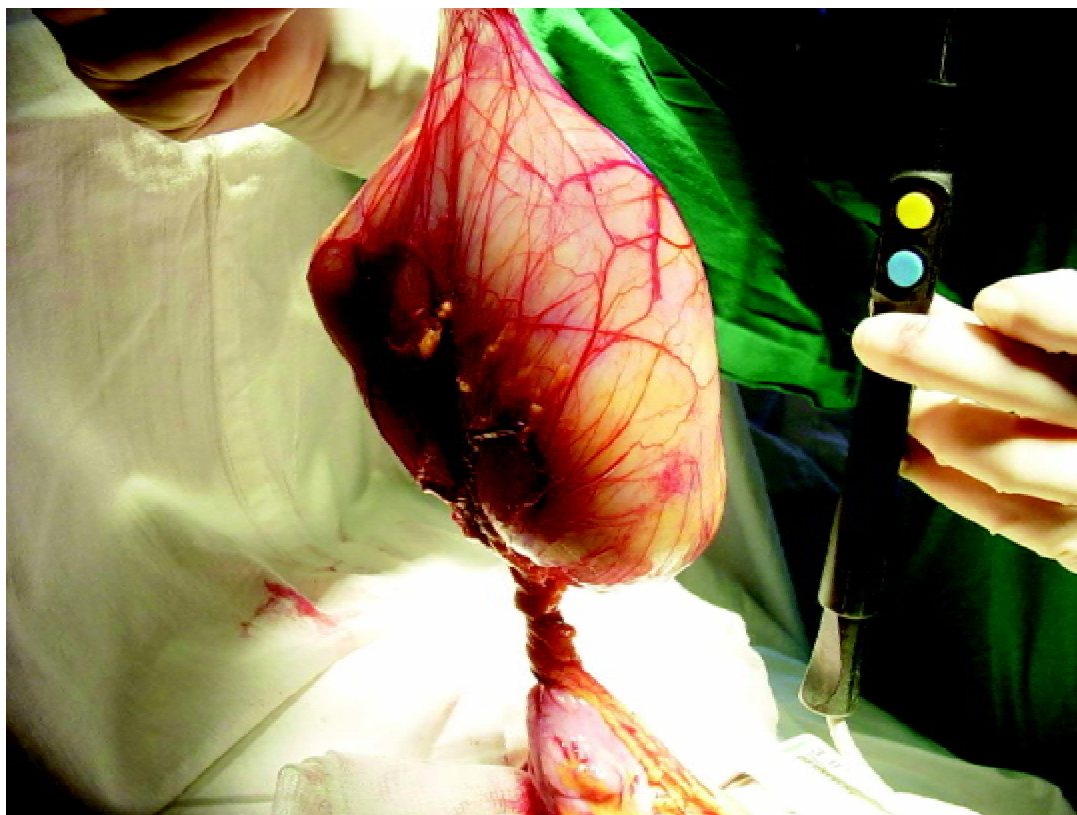


Fig. 2. Intraoperative findings showing greater omentum mass in torsion

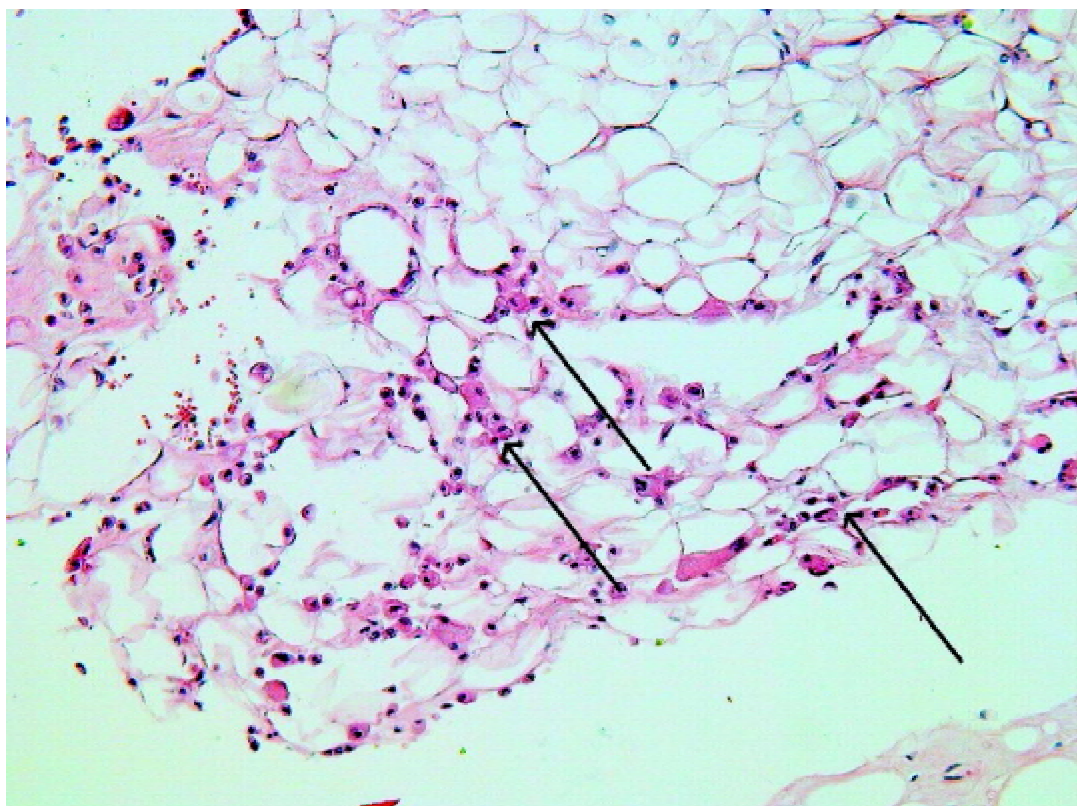


Fig. 3. The soft tissue composed of big mature adipose cells with the laterally displaced nuclei. The macrophages and giant cells with several nuclei (arrows) are located near necrotic lipocytes (H & E $\times 100$)

Didžiosios taukinės lipoma diagnozuota vaikui

Vidmantas Barauskas, Dalius Malcius, Violeta Jazdauskienė
Kauno medicinos universiteto klinikų Vaikų chirurgijos klinika

Raktažodžiai: lipoma, didžioji taukinė.

Santrauka. Didžiosios taukinės lipoma – tai reta liga, ypač vaikams. Straipsnyje aprašoma 10×11×8 cm dydžio besimptomė lipoma, atsitiktinai diagnozuota vaikui. Ultragarsinio ir kompiuterinės tomografijos tyrimo metu pilvo ertmėje rastas ribotas, vientisas, aukšto echogeniškumo darinys. Įtarta lipoma. Laparotomijos metu rasta apsisukusi didžiosios taukinės lipoma. Ji pašalinta kartu su didžiąja taukine. Tiriant histologiškai, rasta lipoma su židininės nekrozės plotais.

Adresas susirašinėjimui: V. Barauskas, KMUK Vaikų chirurgijos klinika, Eivenių 2, Kaunas 50010
El. paštas: pedsurg@kmu.lt

References

1. Sato M, Ishida H, Konno K, et al. Mesenteric lipoma: report of a case with emphasis on US findings. *Eur Radiol* 2002; 12:793-5.
2. Ishida H, Ishida J. Primary tumours of the great omentum. *Eur Radiol* 1998;8:1598-1601.
3. Gonzalez-Crussi F, Sotelo-Avila C, de Mello DE. Primary peritoneal, omental, and mesenteric tumours in childhood. *Semin Diagn Pathol* 1986;3(2):122-37.
4. Giubilei D, Cicia S, Nardis P, Patane E, Villani RM. Lipoma of the omentum in a child. *Radiology* 1980;137(2):357-8.
5. Haller JO, Schneider M, Kassner EG, Slovis TL, Perl LJ. Sonographic evaluation of mesenteric and omental masses in children. *Am J Roentgenol* 1978;130(2):269-74.
6. Hernandez R, Poznanski AK, Holt JF, Weintraub W. Abnormal fat collections in the omentum and mesocolon of children. *Radiology* 1977;122(1):193-6.
7. Yalcin B, Ozturk H, Kismet E, et al. Giant retroperitoneal lipoma in a child. *Pediatr Radiol* 2001;31:304.
8. Sompayrac AW, Mindelzun RE, Silverman PM, et al. The greater omentum. *AJR* 1997;163:683-7.
9. O'Donnell KA, Caty MG, Allen JE, Fisher JE. Lipoblastoma: better termed infantile lipoma? *Pediatr Surg Int* 2000;16:458-61.
10. Wolko JD, Rosenfeld DL, Lazar MJ, Underberg-Davis SJ. Torsion of a giant mesenteric lipoma. *Pediatr Radiol* 2003; 33:34-6.
11. Grankin VE. Torsion of lipoma of the greater omentum (article in Russian) *Vestn Khir Im I I Grek* 1970;104:132.
12. Ashley DJB. Tumours of adipose tissue. In: Ashley DJB, editor. *Evans' histological appearances of tumours*. London: Churchill Livingstone; 1978. p. 54-65.
13. Ilhan H, Tokar B, Isiksoy S, et al. Giant mesenteric lipoma. *J Pediatr Surg* 1999;34:639-40.

Received 26 April 2004, accepted 2 June 2004

Straipsnis gautas 2004 04 26, priimtas 2004 06 02