

Available online at www.sciencedirect.com

journal homepage: <http://www.elsevier.com/locate/medici>

Original Research Article

Anti-inflammatory and anti-oxidative effects of herbal preparation EM 1201 in adjuvant arthritic rats

Laimis Akramas^{a,*}, Laima Leonavičienė^b, Audrius Vasiliauskas^b, Rūta Bradūnaitė^b, Dalia Vaitkienė^c, Danguolė Zabulytė^b, Teresa Normantienė^b, Audronis Lukošius^d, Irena Jonauskienė^b

^a Pharmaceutical Research Company “Aksada” UAB, Kaunas, Lithuania

^b State Research Institute Center for Innovative Medicine, Vilnius, Lithuania

^c Department of Pathology, Faculty of Medicine, Vilnius University, Vilnius, Lithuania

^d Department of Pharmacognosy, Faculty of Pharmacy, Medical Academy, Lithuanian University of Health Sciences, Kaunas, Lithuania

ARTICLE INFO

Article history:

Received 18 July 2013

Accepted 8 November 2015

Available online 17 November 2015

Keywords:

Herbal preparation EM 1201

Adjuvant arthritis

Diclofenac

ABSTRACT

Background and objective: The purpose of the present study was to examine the anti-arthritic and antioxidant effects of herbal and active organic ingredient complex (EM 1201) in rats with experimental adjuvant arthritis (AA).

Materials and methods: AA was induced in 30 male Wistar rats by intradermal injection of complete Freund's adjuvant into the left hind paw. The course of disease in 30 rats in response to the treatment with EM 1201 and diclofenac, the parameters including body weight, joint swelling, blood indices pro-/antioxidant status of blood serum, and histology of joints and the liver, were investigated.

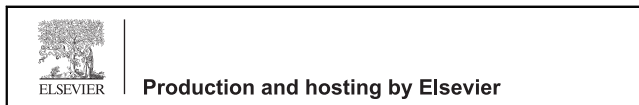Results: Preparation EM 1201 showed anti-inflammatory effect analogous to diclofenac, improved blood indices, significantly decreased joint swelling and histological changes in them. Joint swelling was suppressed by 29%–42.8% and 9.3%–34.4% in response to administration of EM 1201 and diclofenac during the entire experiment. Both preparations significantly suppressed pannus formation, general inflammatory reaction and edema in soft periarticular tissues and synovium, diminished MDA level and elevated AOA in the blood serum. Significantly lower absolute and relative weight of the liver and lower dystrophic processes in it, and general inflammatory infiltration of hepatic stroma proved the positive effect of treatment with EM 1201.

Conclusions: The present study suggests that EM 1201 has protective activity against arthritis and demonstrated its potential beneficiary effect analogous to diclofenac. Anti-inflammatory and anti-oxidative effect of EM 1201 in rats with AA support the need of further

* Corresponding author at: “Aksada” UAB, Studentų 35, 51364 Kaunas, Lithuania.

E-mail address: laimis@aksada.eu (L. Akramas).

Peer review under the responsibility of the Lithuanian University of Health Sciences.



<http://dx.doi.org/10.1016/j.medici.2015.11.002>

1010-660X/© 2015 Lithuanian University of Health Sciences. Production and hosting by Elsevier Sp. z o.o. This is an open access article under the CC BY-NC-ND license (<http://creativecommons.org/licenses/by-nc-nd/4.0/>).

investigations by using it as supplementary agent alone or together with other anti-arthritic drugs in the treatment of rheumatoid arthritis.

© 2015 Lithuanian University of Health Sciences. Production and hosting by Elsevier Sp. z o.o. This is an open access article under the CC BY-NC-ND license (<http://creativecommons.org/licenses/by-nc-nd/4.0/>).

1. Introduction

Due to the complex etiology of rheumatoid arthritis (RA) which is characterized by excessive synovial hyperplasia, vasculogenesis, cartilage and bone destruction and joint malformation [1,2], identification of effective therapies has proven difficult. Although many of drugs used for the treatment of RA transiently suppress inflammation and ameliorate symptoms, they do not help significantly to treat the disease in the long term and may result in serious side effects. Treatments targeting cytokines, including anti-tumor necrosis factor (TNF) α antibodies, soluble TNF receptor, anti-interleukin (IL)-6 receptor antibody and IL-1 receptor antagonist, are widely used for treating RA in addition to anti-inflammatory agents and disease-modifying anti-rheumatic drugs (DMARDs), such as methotrexate, but these treatments have some problems, especially in terms of cost and the increased susceptibility of patients to infection in addition to the existence of low-responders to these treatments [1–3]. Therefore, newer drugs with low or no toxicity for the treatment of RA are actively being sought. Many patients tend to use more effective and safer therapeutic strategy to treat RA and alleviate the adverse effects of chemotherapeutic drugs [4]. Consequently, there is dramatically growing interest in herbal medicines among persons with RA and the use of complementary and alternative medicines (CAMs) for chronic conditions has increased in recent years [5–7].

CAMs are based on herbal formulas, the extracts or ingredients of herbs, and active organic ingredient which show anti-inflammatory action and used for treating arthritic diseases [5–10]. The laboratory studies have identified a number of different molecules involved in inflammation that are inhibited by curcumin including phospholipase, lipoxygenase, cyclooxygenase 2, leukotrienes, thromboxane, prostaglandins, nitric oxide, collagenase, elastase, hyaluronidase, monocyte chemoattractant protein-1 (MCP-1), interferon-inducible protein, tumor necrosis factor (TNF), and interleukin-12 (IL-12) [11]. The studies show that the isolated pure compound of *Boswellia serrata* extract is capable of carrying out a natural anti-inflammatory activity at sites where chronic inflammation is present by switching off the pro-inflammatory cytokines and mediators, which initiate the process [12]. In vitro studies and animal models show that boswellic acids inhibit the synthesis of proinflammatory enzyme, 5-lipoxygenase including 5-hydroxyicosatetraenoic acid and leukotriene B₄, which cause bronchoconstriction, chemotaxis, and increased vascular permeability [13]. The results indicate that MSM inhibits lipopolysaccharide (LPS)-induced release of pro-inflammatory mediators in murine macrophages through downregulation of nuclear factor (NF)- κ B signaling [14]. Study shows that bromelain may be effective in ameliorating physical symptoms and improving general well-being in otherwise healthy adults suffering from mild knee pain in a

dose-dependent manner [15]. Improvements in total symptom score and the stiffness, and physical function dimensions were significantly greater in the high-dose (400 mg per day) compared with the low-dose group (200 mg per day) [15]. The results indicate that the extracts and preparations of the in vitro systems had strong anti-inflammatory properties, comparable to or even higher than that of pure harpagoside (a major anti-inflammatory constituent of intact Devil's claw tubers) [16,17]. Silymarin during evaluation exhibited significant anti-inflammatory and anti-arthritic activities in the papaya latex induced model of inflammation and mycobacterial adjuvant induced arthritis in rats [18]. Results of the study indicate its action through inhibition of 5-lipoxygenase for anti-inflammatory and anti-arthritic activities [18].

The doses of active ingredients were chosen according to scientific research and publications [11–18]. Herbal anti-inflammatory medicines provide a broad-spectrum mechanism of action such as interaction with the inflammatory cascade, cytokine production, inhibition of elastase or hyaluronidase, increased anti-oxidative effectiveness and other still unidentified effects that may contribute to joint protective effects [6].

It is also known that oxygen metabolism and an increase in reactive oxygen species (ROS) have important roles in the pathogenesis of RA [19,20]. Oxygen-free radicals are implicated as mediators of joint tissue damage in RA [21] and in experimentally induced arthritis [22,23]. In addition, anti-oxidants can scavenger free radicals and limit damage. It has been suggested that the pro-oxidant/anti-oxidant imbalance in RA and arthritis models may be due to acceleration of some cellular reactions or insufficiency of the antioxidant defense system [24].

It should be noted that the most of the information about the mechanisms of action of herbal products in the experimental model of RA is relevant to arthritis patients as well. Although animal models may not reproduce all features of human RA, they are essential to facilitate understanding of the mechanisms of this disease and development of new therapies. In the present study we investigated the effects of oral administration of herbal preparation with code name EM 1201 on inflammation and antioxidant status in a rat adjuvant arthritis (AA) model, which is a T-cell dependent and immune-mediated condition characterized by hyperplasia of the synovial lining and inflammation in affected joints with pathogenesis similar to RA and serves as a vehicle to test novel therapeutic agents [25,26].

2. Materials and methods

2.1. Chemicals and drugs

Complete Freund's adjuvant (CFA), 10% formalin, spirit-formol, hematoxylin, eosin, picrofuxin, toluidine blue,

methyl-green-pyronin-Y, acetic acid, trichloroacetic acid, orthophosphoric acid, thiobarbituric acid, nitric acid, ferrous sulfate, ascorbic acid, ammonium molybdate, hydrogen peroxide were obtained from Sigma-Aldrich Chemie and Fluka Chemie GmbH (Germany); ketamine and xylazine, from Biowet (Poland); and diclofenac sodium, from Ciba-Geigy Ltd. (Switzerland). Tetrachloroauric acid ($\text{HAuCl}_4 \cdot 3\text{H}_2\text{O}$) and tannic acid were obtained from Carl Roth GmbH&Co (Germany); sodium citrate, from Penta (Czech Republic).

2.2. Herbal preparation EM 1201

Herbal preparation with code name EM 1201, used in experiment was prepared in the pharmaceutical company "Aconitum". Each dose from this composition consists of Turmeric (*Curcuma longa*) dry extract (curcuminoids 98%), 12.0 mg; Boswellia (*Boswellia serata*) dry extract (boswellic acid 30%), 35.0 mg; methylsulfonmethane, 30.0 mg; pineapple (*Ananas comosus*) dry extract (Bromelain 2000 GDU/g), 15.0 mg; Devil's Claw (*Harpagophytum procumbens*) dry extract (harpagosides 8%), 18.0 mg; Milk Thistle (*Silybum marianum*) dry extract (silymarin 60%), 2.8 mg. Herbal extracts contained in the EM 1201 are standardized by HPLC method and the quality is based on Certificates of Analysis, which corresponds to the European Pharmacopeia requirements.

2.3. Animals

A total of 30 adult male Wistar albino rats (age, 8–10 weeks; weight, 175–200 g) were used for the study. The animals were housed in the clean plastic cages (10 animals per cage) and maintained under standard laboratory conditions (temperature, 20 °C–22 °C; relative humidity, 50%–70%, and 12-h light/dark cycle) in the vivarium of the Department of Biomodels, State Research Institute Centre for Innovative Medicine. They were fed a standard pellet diet and received water ad libitum. The animals were acclimatized to the laboratory conditions for one week prior to the experiments. Throughout the study, the animals were cared for in accordance with the European Convention, Guide for the Care and Use of Laboratory Animals, and Lithuanian Laws. All animal experiments were performed with prior approval of the Lithuanian Laboratory Animal Use Ethics Committee under the State Food and Veterinary Service (protocol No. 0207-2010).

2.4. Adjuvant-induced arthritis, its evaluation and treatment

Adjuvant arthritis (AA) was induced by the subplantar injection of 0.1 mL complete Freund's adjuvant (CFA). The rats were randomly divided into 3 groups: control group without treatment (Group 1 AA); AA treated with 110 mg/kg/d of preparation EM 1201 (Group 2), and –AA treated with 1 mg/kg/d diclofenac (Group 3). The used doses of both preparations in animals corresponded to the doses used for humans. The treatment was performed from AA inducing day and preparations were injected orally by gastric intubation 5 times a week. Experiment lasted 17 days. The changes in body weight and joint swelling were recorded 3 times a week. The anti-arthritic effect of EM 1201 or diclofenac sodium was evaluated by

measuring the paw volume plethysmometrically by using plethysmometer (PVP1001; Kent Scientific Corporation). On the 17th day, the rats were euthanized by decapitation. Blood, liver and articular joint tissues were collected for the further investigation.

2.5. Blood and tissue collection

At the end of experiments animals were humanely killed by decapitation under ketamine–xylazine anesthesia. Their internal organs were examined macroscopically and weighed, and the liver and injected joints were taken for histological analysis. The erythrocyte and leukocyte counts (made using a Picoscale, Hungary) and the erythrocyte sedimentation rate (ESR) were determined in the blood. Blood samples were centrifuged at $800 \times g$ for 10 min to obtain serum samples which were stored frozen at $-20\text{ }^\circ\text{C}$ until testing.

2.6. Lipid peroxidation, catalase, and total antioxidant activity level detection in blood serum

2.6.1. Determination of MDA levels

Malondialdehyde (MDA) is the final product of peroxidation of fatty acids reacted with thiobarbituric acid to form a colored complex, characterized by absorption maximum at a wavelength of 532 nm. Levels of MDA were determined in the blood serum by a method described by Gavrilov et al. [27], which is a modified method of Ohkawa et al. [28]. The procedure was as follows: 0.2 mL of serum (control sample with redistilled water) was added to a reaction mixture containing 0.2 mL of 8.1% sodium dodecyl sulfate, 1.5 mL of 20% acetic acid (pH 3.5, adjusted with sodium hydroxide), 1.5 mL of 0.8% thiobarbituric acid, and 0.6 mL of redistilled water. Entire mixture (up to 4.0 mL) was incubated 60 min at 95 °C. Then 1.5 mL of 10% of trichloroacetic acid was added into 1.5 mL of substrate, and the sample was centrifuged at $8000 \times g$ for 20 min. The optic density of MDA level was determined with spectrophotometer (Marcell Pro 300; Poland) at a wavelength of 532 nm. MDA concentration is calculated using formula $(E_{\text{control}} - E_{\text{sample}}) / 1.56 \times 10$ and expressed as (nmol/mL).

2.6.2. Determination of catalase activity

Antioxidant status of the system was evaluated by catalase (CAT) activity in serum. CAT activity assessment method is based on the hydrogen content decrease dependent on time. Hydrogen peroxide forms a stable complex with the color of ammonium molybdate at a wavelength of 410 nm. CAT activity was determined by a method, described by Koroliuk et al. [29]. Briefly, 0.03% hydrogen peroxide (H_2O_2), and 4% ammonium molybdate solution were used in this reaction. 0.1 mL of test serum and 2.0 mL of 0.03% H_2O_2 after 10 min was diluted with 1.0 mL of 4% ammonium molybdate. Optical density of obtained sample was determined with spectrophotometer at the wavelength of 410 nm and compared with reagents control (redistilled water was used instead 2 mL of 0.03% H_2O_2). CAT activity was calculated according to the formula:

$$\frac{(E_{\text{reagents}} - [E_{\text{samples}} - E_{\text{H}_2\text{O}}]) \times 3000}{22.2},$$

where E_{reagents} is optical density of reagents (control of reaction); E_{samples} is the optic density of the investigated material; $E_{\text{H}_2\text{O}}$, optical density of investigated material, where 0.03% H_2O_2 exchange by water (control of sample). CAT activity was expressed as nmol/L/min.

2.6.3. Determination of total AOA level

Total AOA was determined in the reaction with thiobarbituric acid, described by Galaktionova et al. [30]. Reagents used for reaction are: 1% Tween[®] 80, 1 mM aqueous iron (II) sulfate, 10 mM aqueous ascorbic acid, 40% trichloroacetic acid and 0.25% aqueous tiobarbituric acid. Briefly: reaction mixture consisted of 2 mL of 1% Tween[®] 80 solution, 0.2 mL of 1 mM aqueous iron (II) sulfate, 0.2 mL of a 10 mM aqueous ascorbic acid and 0.2 mL of test substance and the sample was incubated 48 h at 40 °C. Subsequently 2 mL of the obtained mixture is diluted with 1 mL of 40% trichloroacetic acid. After 1 h samples are centrifuged at $8000 \times g$ for 15 min. Then, 1.0 mL of the supernatant was diluted with 2 mL of 0.25% aqueous solution of tiobarbituric acid and boiled for 15 min. Biological material was exchanged with water for the reaction control. Optical density of cold mixture was measured using the same spectrophotometer at a wavelength of 532 nm. The percentage of total AOA was calculated according to the formula $(E_{\text{control}} - E_{\text{sample}})/E_{\text{control}} \times 100$.

2.6.4. Histology

The liver and injected paws from AA rats were excised, followed by routine fixation, decalcification, and paraffin embedding. Deparaffinized 4- μm histological sections of joints and liver were stained with hematoxylin–eosin (for visualization of cells), Van Gieson's picrofuchsin (for visualization of collagen fibers), toluidine blue (for visualization of proteoglycan loss in cartilage), methyl green–pyronin-Y (for detection of plasma cells), and safranin O (for evaluation of proteoglycan depletion in cartilage).

Histological assessment of inflammatory infiltration with lymphocytes, plasma cells, macrophages, and granulocytes, scoring of other symptoms of inflammation in the liver, synovial membrane and soft periarticular tissues as well as scoring of cartilage damage were performed in a blind method by two independent researchers. A 4-point scale (0–3) was used where 0 indicates the absence of changes and 3 means the most severe expression of a particular sign. Such estimation during the course of arthritic processes is widely used in the scientific literature. All histological sections prepared from obtained tissue samples were tested.

2.7. Statistical analysis

Statistical evaluation of the results was conducted by one-way analysis of variance ANOVA using PRISM Software (GraphPad Software, San Diego, CA, USA) and Student t test. The nonparametric Mann–Whitney *U* test was used to evaluate the histological changes. All data were expressed as mean \pm SEM and were considered to be statistically significant at $P < 0.05$.

3. Results

3.1. Effect of preparations on body and organ weight

The total body weight of all the investigated groups increased during the experiment and from the beginning to the end of investigation it was higher by 12.2% (from 186.16 ± 2.90 to 208.92 ± 2.57 g) in the control group, and 19.7% (from 186.84 ± 4.60 to 223.67 ± 6.12 g) and 14.9% (from 186.06 ± 3.51 to 23.79 ± 5.26 g) in both tested groups respectively treated with EM 1201 and diclofenac, although no significant differences between the groups were observed (data not shown). At the end of the experiment the body weight was higher by 7.06% ($P < 0.05$) in the group treated with EM 1201 and by 2.3% in the group treated with diclofenac than in the control group.

A postmortem examination of the internal organs (Table 1) revealed a significantly lower absolute and relative weight of the liver ($P < 0.05$; $P < 0.001$) and kidneys ($P < 0.05$; $P < 0.01$) and lower relative weight of the spleen ($P < 0.02$) in the group of animals treated with EM 1201 in comparison with the control group. This observation showed a positive effect of this preparation on internal organs, because an increased weight of the liver and spleen in rats with adjuvant arthritis during the course of disease was described in many sources of literature.

3.2. Effect of preparations on the hematological parameters and pro-/antioxidant activity of blood serum

Changes in the blood indices at the end of experiment are shown in Fig. 1(A). The ESR for both groups of rats after the treatment with EM 1201 and diclofenac was markedly lower than in the control group and decreased by 50.7% ($P < 0.001$) and 52.7% ($P < 0.001$) in the groups respectively treated with EM 1201 and diclofenac.

In comparison with the control group the count of leukocytes in both treated groups was lower by 19.4% ($P < 0.01$) and 19.2% ($P < 0.01$).

A higher erythrocyte count by 20.5% and 12.5% as compared with the control group was observed in rats that received respectively the preparation EM 1201 ($P < 0.01$) and diclofenac ($P < 0.01$).

The indices of pro-/antioxidant activity of blood serum are shown in Fig. 1(B). There were no significant differences in serum antioxidant enzyme CAT activity of the control and treated groups: it was found only insignificantly higher by 1.2% and 12.7% in animals that respectively received EM 1201 and diclofenac (Fig. 1B).

The level of serum MDA as oxidative stress marker in blood serum of rats treated with EM 1201 was found to be lower by 27.3% than in the control group ($P < 0.001$). Treatment with diclofenac decreased MDA level by 20.4% ($P < 0.02$) and no significant differences between both treated groups were observed.

In comparison with the control group AOA in the blood serum was twofold higher in rats treated with EM 1201 ($P < 0.0001$) and also markedly increased by 71.8% ($P < 0.001$) in animals that received diclofenac.

Table 1 – Body and organs' weight of male rats with adjuvant arthritis treated with preparation EM 1201 and diclofenac.

Groups	Body weight (g)		Liver		Kidney		Spleen		Thymus	
	Absolute (g)	Relative (g/100 g body weight)	Absolute (g)	Relative (g/100 g body weight)	Absolute (g)	Relative (g/100 g body weight)	Absolute (g)	Relative (g/100 g body weight)	Absolute (g)	Relative (g/100 g body weight)
1 AA (control)	208.92 ± 2.57	3.94 ± 0.16	1.93 ± 0.06	0.92 ± 0.03	1.27 ± 0.12	0.61 ± 0.06	0.38 ± 0.02	0.18 ± 0.01	0.38 ± 0.02	0.18 ± 0.01
2 AA + EM1201 (110 mg/kg)	223.66 ± 6.12*	3.19 ± 0.05*	1.72 ± 0.06*	0.77 ± 0.02*	1.00 ± 0.05	0.44 ± 0.02*	0.41 ± 0.02	0.18 ± 0.009	0.41 ± 0.02	0.18 ± 0.009
3 AA + diclofenac (1 mg/kg)	213.79 ± 5.26	3.48 ± 0.15*	1.82 ± 0.06	0.86 ± 0.04	1.02 ± 0.08	0.48 ± 0.04	0.34 ± 0.02	0.16 ± 0.01	0.34 ± 0.02	0.16 ± 0.01

Values are expressed as means ± SEM. Adjuvant arthritis (AA) was induced by a single injection of 0.1-mL complete Freund's adjuvant (CFA) into the left hind paw. Groups 2 and 3 were treated (from AA-inducing day) with 110 mg/kg of EM 1201 and 1 mg/kg of diclofenac which were injected orally 5 times a week. Duration of experiment is 17 days.

* P < 0.05 vs. control group.

3.3. Histological changes in the liver

No toxic effect on the liver of rats with AA was detected after the treatment with EM 1201 and diclofenac (Table 2). Both treatments decreased alteration of hepatic parenchyma and general inflammatory infiltration of hepatic stroma in comparison with the control group. Slight observed dystrophy in the liver of the treated groups means the alterations some of which maybe are reversible while a hard dystrophy can be irreversible, that means progressing to necrosis. Dystrophic changes were significantly lower by 28.6% ($P < 0.001$) and 20% ($P < 0.05$), and general infiltration by 34.5% ($P < 0.02$) and 35.6% ($P < 0.01$) in the groups of rats respectively treated with EM 1201 and diclofenac. Preparation EM 1201 significantly diminished inflammatory infiltration of hepatic stroma with granulocytes ($P < 0.05$) and diclofenac necrotic processes ($P < 0.02$) in parenchyma (Table 2).

Preparation EM 1201, being insignificantly more potent than diclofenac, decreased hypervolemia of *V. centralis* by 33.3% and inhibited inflammatory infiltration with macrophages by 28.7%. Penetration of inflammatory cells into the hepatic lobule was lower by 58.2% after the treatment with preparation EM 1201 and by 53.7% after diclofenac use, and the changes in comparison with the control group were near to significant ($t = 2.03$ for EM 1201; $t = 2.04$ for diclofenac).

The fibrotic processes insignificantly increased by 30.2% in the group treated with EM 1201 and decreased by 41.9% in diclofenac group.

So, both preparations did not show toxic effects and similarly improved the histological changes induced by AA in hepatic tissue.

3.4. Joint swelling and incidence of polyarthritis development

As is seen from Fig. 2, the injection of CFA into the subplantar region induced arthritis and increased the paw volume. The EM 1201 treated animals showed significant reduction in joint swelling from the 3rd day ($P < 0.001$) till the end of experiment and it was lower than in the control group by 29%–42.8% ($P < 0.001$; $P < 0.0001$) during experiment.

Diclofenac also significantly decreased joint swelling throughout the 17 days study (P from <0.001 to <0.02), but the reduction induced by diclofenac was somewhat lower than after therapy with EM 1201 and at the end of experiment reached 34.4%. Comparison of the inhibition observed for the EM 1201 and diclofenac did not reveal any significant difference.

Polyarthritis did not develop in the animals of the treated groups, whereas polyarthritis damaging one non-injected limb and characterizing the generalization of the disease and exacerbation of the autoimmune process was observed in 30% of animals of the control group.

3.5. Histological features of arthritis

The histological examination of the joints of the injected paw on day 17 after arthritis induction showed the most expressed soft tissue pathology in rats of the control group (Table 3). Both preparations significantly suppressed inflammatory

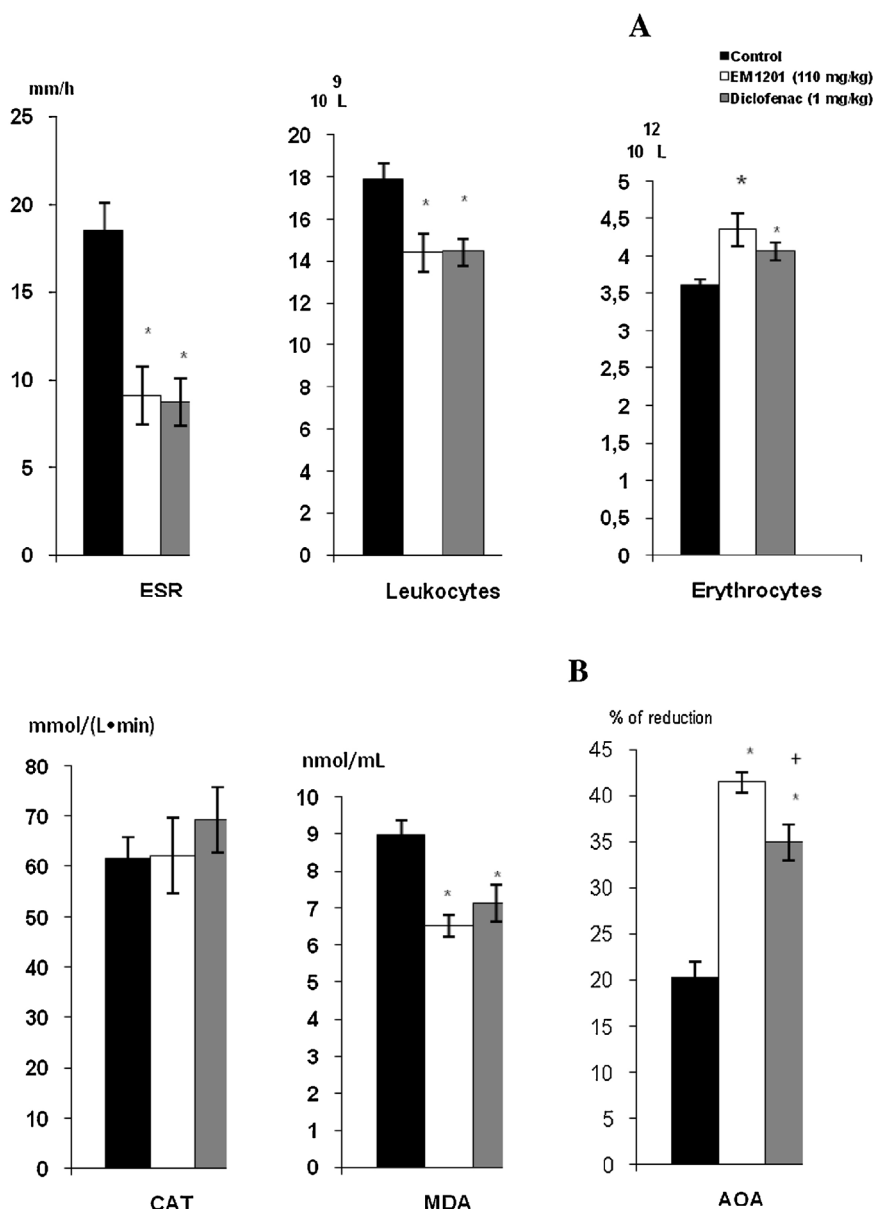


Fig. 1 – Blood indices (A) and pro-antioxidant activity (B) in rats with adjuvant arthritis treated with preparation EM1201 and diclofenac. Adjuvant arthritis (AA) was induced by a single injection of 0.1 mL complete Freund's adjuvant (CFA) into the left hind paw. The tested groups were treated (since AA inducing day) with 110 mg/kg of EM 1201 and 1 mg/kg of diclofenac which were injected orally 5 times a week. The duration of experiment was 17 days. CAT, catalase; MDA, malondialdehyde; AOA, total antioxidant activity. *P < 0.05 vs. control group. +P < 0.05 between EM 1201 and diclofenac treated groups.

infiltration with leukocytes ($P < 0.02$; $P < 0.01$), general inflammatory reaction ($P < 0.002$), edema ($P < 0.01$; $P < 0.002$), angiomas ($P < 0.02$; $P < 0.002$) and intensified fibrotic processes ($P < 0.001$) in comparison with the control group. A significantly lower infiltration with macrophages by 26.4% was observed under the treatment with diclofenac ($P < 0.02$).

EM 1201 and diclofenac suppressed synovial villi proliferation ($P < 0.02$; $P < 0.01$), edema ($P < 0.01$; $P < 0.001$), diminished inflammatory infiltration with granulocytes ($P < 0.001$), general inflammatory reaction ($P < 0.01$) and intensified fibrotic processes ($P < 0.001$).

The formation of erosion was lower by 35.9% and 27.6% than in the control group after the treatment with EM 1201 and

diclofenac. The latter preparation also markedly diminished usurae ($P < 0.002$) and thinning of cartilage ($P < 0.05$). There were no animals with cartilage thinning in this group, while in the group treated with preparation EM 1201 only one animal had a thinned cartilage. Both preparations significantly suppressed pannus formation ($P < 0.01$).

4. Discussion

Concerns about the safety and efficacy of many drugs used for the treatment of autoimmune diseases have persisted for many years and researchers put high efforts to find the new

Table 2 – Pathomorphological changes in the liver of male Wistar rats with adjuvant arthritis treated with EM 1201 and diclofenac.

Index		Groups		
		1 (AA control)	2 (AA + EM 1201)	3 (AA + DF)
Alteration of parenchyma	Dystrophy	1.40 ± 0.09	1.00 ± 0.00*	1.12 ± 0.08 [†]
	Necrosis	0.83 ± 0.08	0.50 ± 0.15	0.44 ± 0.11 [†]
Hypervolemia of <i>V. centralis</i>		0.57 ± 0.12	0.38 ± 0.08	0.62 ± 0.18
Inflammatory infiltration of hepatic stroma	Lymphocytes	0.57 ± 0.07	0.36 ± 0.14	0.37 ± 0.08
	Granulocytes	0.20 ± 0.06	0.07 ± 0.07 [†]	0.13 ± 0.08
	Macrophages	0.80 ± 0.09	0.57 ± 0.07	0.56 ± 0.11
	General	0.87 ± 0.08	0.57 ± 0.07 [†]	0.56 ± 0.06 [†]
	Penetration into the lobule	0.67 ± 0.12	0.28 ± 0.15	0.31 ± 0.13
Fibrosis		0.43 ± 0.12	0.56 ± 0.14	0.25 ± 0.09

Values are expressed as means ± SEM. Adjuvant arthritis (AA) was induced by a single injection of 0.1 mL complete Freund's adjuvant (CFA) into the left hind paw. II and III tested groups were treated (since AA inducing day) with 110 mg/kg of EM 1201 and 1 mg/kg of diclofenac (DF) which were injected orally 5 times a week. Duration of experiment is 17 days. Hepatic tissue was fixed in spirit-formol (1:9), embedded in paraffin, and 5 µm-thick histological sections of liver were stained with hematoxylin-eosin (for visualization of inflammation and inflammatory cell infiltration and hepatocytes necrosis) and picrofuchin (for determination of fibrotic processes). The histological assessment of changes in the liver was performed in a blinded manner by two pathologists. Each parameter was scored on a 0-to-3-point scale, where 0 means the absence of changes; 0.5, traces of changes; 1, minimal changes; 2, moderate changes; and 3, heavy changes.

* P < 0.05 vs. control group.

drugs with fewer side effects. During the past years many research groups throughout the world have concentrated on finding biologically active substances from various plants and efficacy of various natural products against inflammation, and arthritis has been explored [11–18].

Our previous investigations also have shown that administration of herbal preparation tinctures, such as *Filipendula ulmaria* Maxim (L) and *Aesculus hippocastanum* (L), exerts a therapeutic effect on AA and osteoarthritis in rats [31,32].

In this study we investigate the herbal preparation with code name EM 1201 which is a complex consisting of: turmeric (*Curcuma longa*) dry extract (curcuminoids 98%), *Boswellia* (*Boswellia serata*) dry extract (boswellic acid 30%), methylsulfonylmethane, pineapple (*Ananas comosus*) dry extract (Bromelain

2000 GDU/g), Devil's Claw (*Harpagophytum procumbens*) dry extract (harpagosides 8%) and Milk Thistle (*Silybum Marianum*) dry extract (silymarin 60%) and prepared in the pharmaceutical company "Aconitum". The effect of this preparation was compared with anti-inflammatory and anti-oxidative effect of diclofenac, which is one of the classical drugs for the treatment of RA and most commonly used as the reference drug for laboratory research and preclinical development of novel anti-arthritic agents. Both preparations in animals were used in the doses that corresponded to the doses used for humans.

The present study evaluated the anti-arthritic potentiality of preparation EM 1201 on adjuvant arthritis in male Wistar rats. The efficacy of EM 1201 at the dose 110 mg/kg body was comparable to the drug diclofenac. Anti-inflammatory and anti-oxidative effect, improved blood indices, markedly decreased joint swelling and lower histopathological changes in them were observed after the treatment with these preparations. It is shown that herbal medicinal products prepared from *Curcuma longa* [33,34], *Boswellia serata* [35,36], *Harpagophytum procumbens* (Devil's Claw) [37,38] are proposed for the treatment of arthritic processes. The results we obtained prove effectiveness of mixture prepared from such products. Such preparations as bromelain derived from pineapple stem [15,39], methylsulfonylmethane, which is one of the popular ingredients of so-called health foods in Japan [14,40,41], silymarin, a polyphenolic flavonoid derived from Milk Thistle (*Silybum marianum*) [18,42], also showed anti-inflammatory and anti-arthritic activities.

It is known, that the primary immune reaction in paw joint is the mononuclear cell infiltration of the synovial tissue, which, if uncontrolled, can lead to damage of cartilage. Our investigation showed that herbal preparation EM 1201 like diclofenac significantly suppressed general inflammatory reaction and edema in soft periarticular tissues and synovium, inflammatory infiltration with leukocytes and angiomas, inflammatory infiltration with leukocytes and angiomas in soft periarticular tissues and infiltration with granulocytes in synovium and suppressed synovial villi proliferation and pannus formation.

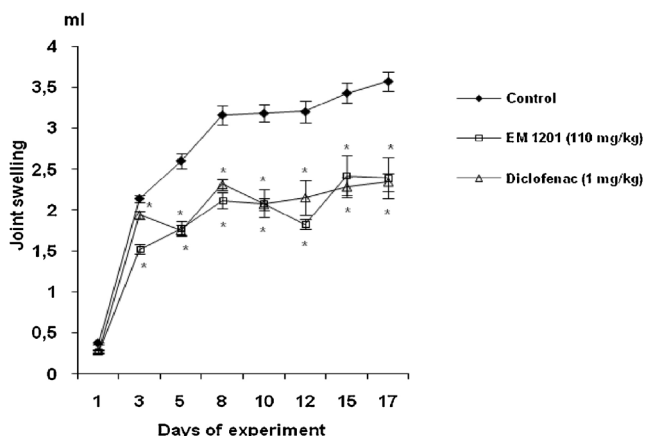


Fig. 2 – Joint swelling of rats with adjuvant arthritis treated with EM 1201 and diclofenac. Adjuvant arthritis (AA) was induced by a single injection of 0.1 mL complete Freund's adjuvant (CFA) into the left hind paw. The tested groups were treated (since AA inducing day) with 110 mg/kg of EM 1201 and 1 mg/kg of diclofenac which were injected orally 5 times a week. Duration of experiment is 17 days. *P < 0.05 vs. control group.

Table 3 – Histological changes in joints of male arthritic rats treated with EM 1201 and diclofenac.

Tissue	Index		Groups		
			1 Control	2 EM 1201 (110 mg/kg)	3 Diclofenac (1 mg/kg)
Soft periarticular tissues	Inflammatory infiltration	Lymphocytes	1.31 ± 0.13	1.06 ± 0.06	1.13 ± 0.12
		Plasma cells	–	–	–
		Leukocytes	2.19 ± 0.17	1.50 ± 0.19*	1.00 ± 0.31*
		Macrophages	1.44 ± 0.13	1.31 ± 0.13	1.06 ± 0.06*
		General	2.34 ± 0.13	1.75 ± 0.09*	1.56 ± 0.15*
	Edema	1.97 ± 0.17	1.00 ± 0.21*	0.81 ± 0.25*	
	Angiomatosis	1.53 ± 0.15	0.81 ± 0.21*	0.69 ± 0.16*	
Synovium	Fibrosis		–	0.75 ± 0.16*	1.25 ± 0.23*
		γ-Metachromasia	0.34 ± 0.15	0.19 ± 0.09	0.25 ± 0.13
	Villi proliferation		1.44 ± 0.15	0.94 ± 0.11*	0.81 ± 0.09*
		Edema	0.88 ± 0.17	0.19 ± 0.13*	0.13 ± 0.08*
		γ-Metachromasia	0.06 ± 0.06	–	–
	Inflammatory infiltration	Lymphocytes	0.47 ± 0.13	0.56 ± 0.06	0.44 ± 0.11
		Granulocytes	1.03 ± 0.15	0.13 ± 0.08*	0.13 ± 0.08*
Macrophages		0.13 ± 0.07	0.06 ± 0.06	0.25 ± 0.13	
General		1.09 ± 0.14	0.56 ± 0.06*	0.50 ± 0.09*	
Fibrosis		–	0.94 ± 0.17*	1.25 ± 0.16*	
	Angiomatosis	0.66 ± 0.14	0.31 ± 0.13	0.38 ± 0.13	
Cartilage	Alteration	Erosion	1.56 ± 0.16	1.00 ± 0.27	1.13 ± 0.20
		Usura	0.75 ± 0.14	0.50 ± 0.19	0.13 ± 0.08*
		Fissure	0.09 ± 0.07	–	–
	Pannus	0.91 ± 0.18	0.25 ± 0.13*	0.25 ± 0.09*	
	Thinning of cartilage	0.19 ± 0.08	0.06 ± 0.06	–	

Values are expressed as means ± SEM. Adjuvant arthritis (AA) was induced in 30 rats by the foot paw method by injecting 0.1 mL of complete Freund's adjuvant (CFA) into the left hind paw under light anesthesia. Group 1 (control), animals with induced AA; Groups 2 and 3, rats with AA treated 5 times a week with EM 1201 and diclofenac. Duration of experiment is 17 days. For investigation are used only the joints of injected with CFA paws (30), where more severe lesions are commonly found in this model. Joint tissues are fixed in spirit-formol (1:9) and embedded in paraffin. Histological 5-µm thick tissue sections were stained with hematoxylin-eosin, picrofuchin, toluidine blue, methyl-green-pyronin-9 and safranin O. Assessment of changes in synovium, soft periarticular tissues and cartilage was performed in a blinded manner by two pathologists using a 0-3-point scale, where 0 indicates the absence of changes and 3 means the most severe expression of a particular sign. * P < 0.05 vs. control group.

Preparation EM 1201 also improved blood indices. Elevated leukocyte count in arthritic conditions [43] was decreased by EM 1201 and diclofenac treatments. Erythrocyte sedimentation rate (ESR) is influenced by an increase in the plasma concentration of acute-phase reactant proteins in response to inflammation [44], and both EM 1201 and diclofenac treatments are decreasing the ESR.

It is known that oxidative damage induced by ROS is an important mechanism that underlies destructive and proliferative synovitis and articular degradation [22,23], and a remarkable increase in ROS and H₂O₂ in arthritic rats is observed [15]. High lipid peroxidation levels were an indicator of reduced antioxidant capacity and increased oxidative stress in RA [45].

One of the most frequently used biomarker providing an indication of the overall lipid peroxidation level is MDA [46]. On the other hand, the low antioxidant level is also a risk factor of RA, and it worsens the severity of the condition [47]. Antioxidant effectiveness of EM 1201 was confirmed by assessing blood serum lipid peroxidation value MDA, CAT activity and AOA. Indeed, we could show that the improvement in arthritic parameters after EM 1201 consumption was accompanied by a significant improvement in indices of serum oxidative stress measured as MDA level. Treatment with EM 1201 and diclofenac significantly decreased MDA levels in

serum by 27.3% and 20.4% in comparison with the control group suggesting the protective effect of preparations that might be attributed to their antioxidant and free radical scavenging activity.

Although in this experiment the antioxidant enzyme CAT activity was not influenced by the treatment with EM 1201 and there were no significant differences between the control and treated groups.

In spite of CAT activity, the AOA in blood serum was significantly twofold higher in rats treated with EM 1201 and also markedly increased in animals that received diclofenac.

It is known that naturally antioxidants present in many plants offer health benefits in preventing various diseases by fighting cellular damage caused by free radical-induced oxidative stress [29]. This antioxidant effect is mainly due to radical scavenging activity of phenolic compounds such as flavonoids, polyphenols, tannins, and phenolic terpenes [48].

Numerous studies have shown that in the course of AA not only joints with obvious signs of inflammation, but also visceral organs may be affected by the pathological process and the weight of internal organs, such as liver and spleen increase [23,49].

A significantly lower weight of the liver, ameliorated dystrophic processes in hepatic tissue and diminished

inflammatory infiltration of hepatic stroma with inflammatory cells showed the positive effect of EM 1201.

The significant reduction in relative spleen weight after the treatment with EM 1201 and increase in thymus weight are related to stimulatory effect on the immune system [50]. Maybe large doses of EM 1201 are needed to be used for receive the better anti-inflammatory effect in male rats with AA, although it is not accurate to assume that large doses of preparation will always return large benefits.

In summary, results of the present study showed beneficial therapeutic effect of EM 1201 similar to diclofenac, which reduced systemic and local indices of inflammation in affected joints and showed a moderate antioxidant activity by inhibiting MDA and increasing AOA in rat model of RA. The results of this study show that preparation EM 1201 can be used as an accessible source of antioxidant. A further study is needed to determine the mechanism behind the antioxidant activity of this herbal preparation. It should be noted that the herbal products influence the number and/or activity of specific immune mediators (e.g., T cells, antibodies, cytokines and chemokines) which in turn drive the 3 major immune pathways leading to pathological damage observed in arthritis [51] which include cellular and humoral immune responses, cytokine response/balance, and cell migration. The net effect of these immunological changes induced by herbal treatment is the suppression of inflammatory and related arthritic processes [51].

In this study, we demonstrated clinically beneficial effects of EM 1201 for Wistar male rats with AA, supported by an improvement in serum parameters of oxidative stress. The combination of EM 1201 anti-oxidative properties with its anti-inflammatory and anti-arthritogenic profile makes it an attractive over-the-counter supplementation to treat patients with joint inflammation. Our results suggest the possibility of therapeutic co-administration of EM 1201 with conventional drugs for the treatment of RA.

On the basis of the results obtained from animal model of RA we consider the herbal preparation EM 1201 to be a promising candidate for the future preclinical and clinical trials in RA.

5. Conclusions

Treatment with EM 1201 not only reduces the inflammation, joint swelling and development of polyarthritis, but also decreases histological changes in articular tissues by suppressing progression of joint destruction and inflammation in soft tissue periarticular tissues and synovium without toxic effects on the liver. EM 1201 not only reduced multiple indices of arthritis but also demonstrated the potential beneficiary effect as anti-oxidative agent. The obtained results support the need of further investigation by using this preparation as supplementary agent together with conventional drugs for the treatment of rheumatoid arthritis.

Conflict of interest

All the authors hereby disclose that there is not conflict of interest among the authors.

Acknowledgments

We thank Prof. Z. Mackiewicz very much for his consultations and recommendations in evaluation of histological changes in internal organs and joints, and Dr. G. Bižanov for statistical evaluation of the results by using one-way ANOVA method for analysis of variance.

REFERENCES

- [1] Scott DL, Wolfe F, Huizinga TWJ. Rheumatoid arthritis. *Lancet* 2010;376:1094–108.
- [2] Goldring MB, Marcu KB. Cartilage homeostasis in health and rheumatoid diseases. *Arthritis Res Ther* 2009;11:224.
- [3] Smolen JS, Landewé R, Breedveld FC, Dougados M, Emery P, Gaujoux-Viala C, et al. EULAR recommendations for the management of rheumatoid arthritis with synthetic and biological disease-modifying antirheumatic drugs. *Ann Rheum Dis* 2010;69:964–75.
- [4] Yin J, Zhang H, Ye I. Traditional Chinese medicine in treatment of metabolic syndrome. *Endocr Metab Immune Disord Drug Targets* 2008;8:99–111.
- [5] Zhang P, Li J, Han Y, Yu XW, Qin L. Traditional Chinese medicine in the treatment of rheumatoid arthritis: a general review. *Rheumatol Int* 2010;30:713–8.
- [6] Venkatesha SH, Berman BM, Moudgil KD. Herbal medicinal products target defined biochemical and molecular mediators of inflammatory autoimmune arthritis. *Bioorg Med Chem* 2011;19:21–9.
- [7] Imada K, Bian B, Li X, Sato T, Ito A. Action mechanisms of complementary and alternative medicine therapies for rheumatoid arthritis. *Chin J Integr Med* 2011;17:723–30.
- [8] Otari KV, Shete RV, Upasani CD, Adak VS, Bagade MY, Harpalani AN. Evaluation of anti-inflammatory and anti-arthritic activities of ethanolic extract of *Vernonia anthelmintica* seeds. *J Cell Tissue Res* 2010;10:2269–80.
- [9] Jiang JB, Qiu JD, Yang LH, He JP, Smith GW, Li HQ. Therapeutic effects of astragalus polysaccharides on inflammation and synovial apoptosis in rats with adjuvant-induced arthritis. *Int J Rheum Dis* 2010;13:396–405.
- [10] Callahan LF, Wiley-Exley EK, Mielenz TJ, Xiao C, Currey SS, Sleath BL, et al. Use of complementary and alternative medicine among patients with arthritis. *Prevent Chronic Dis* 2009;6:A44.
- [11] Chainani-Wu N. Safety and anti-inflammatory activity of curcumin: a component of tumeric (*Curcuma longa*). *J Altern Complement Med* 2003;9:161–8.
- [12] Gayathri B, Manjula N, Vinaykumar KS, Lakshmi BS, Balakrishnan A. Pure compound from *Boswellia serrata* extract exhibits anti-inflammatory property in human PBMCs and mouse macrophages through inhibition of TNF α , IL-1 β , NO and MAP kinases. *Int Immunopharmacol* 2007;7:473–82.
- [13] Siddiqui MZ. *Boswellia serrata*, a potential anti-inflammatory agent: an overview. *Indian J Pharm Sci* 2011;73:255–61.
- [14] Kim YH, Kim DH, Lim H, Baek DY, Shin HK, Kim JK. The anti-inflammatory effects of methylsulfonylmethane on lipopolysaccharide-induced inflammatory responses in murine macrophages. *Biol Pharm Bull* 2009;32:651–6.
- [15] Walker AF, Bundy R, Hicks SM, Middleton RW. Bromelain reduces mild acute knee pain and improves well-being in a dose-dependent fashion in an open study of otherwise healthy adults. *Phytomedicine* 2002;9:681–6.

- [16] McGregor G, Fiebich B, Wartenberg A, Brien S, Lewith G, Wegener T. Devil's claw (*Harpagophytum procumbens*): an anti-inflammatory herb with therapeutic potential. *Phytochem Rev* 2005;4:47–53.
- [17] Gyurkovska V, Alipieva K, Maciuk A, Dimitrova P, Ivanovska N, Haas C, et al. Anti-inflammatory activity of Devil's claw in vitro systems and their active constituents. *Food Chem* 2011;125:171–8.
- [18] Gupta OP, Sing S, Bani S, Sharma N, Malhotra S, Gupta BD, et al. Anti-inflammatory and anti-arthritis activities of silymarin acting through inhibition of 5-lipoxygenase. *Phytomedicine* 2000;7:21–4.
- [19] Flora SJ. Role of free radicals and antioxidants in health and disease. *Cell Mol Biol (noisy-le-grand)* 2007;53:1–2.
- [20] Mirshafiey A, Mohsenzadegan M. The role of reactive oxygen species in immunopathogenesis of rheumatoid arthritis. *Iran J Allergy Asthma Immunol* 2008;7:195–202.
- [21] Hitchon CA, El-Gabalawy HS. Oxidation in rheumatoid arthritis. *Arthritis Res Ther* 2004;6:265–78.
- [22] Leonavičienė L, Bradūnaitė R, Vaitkienė D, Vasiliauskas A, Keturkienė A. Collagen-induced arthritis and pro-/antioxidant status in Wistar and Lewis rats. *Biologija* 2008;54:290–3000.
- [23] Hemshekhar M, Sebastin Santhosh M, Sunitha K, Thushara RM, Kemparaju K, Rangappa KS, et al. A dietary colorant crocin mitigates arthritis and associated secondary complications by modulating cartilage deteriorating enzymes, inflammatory mediators and antioxidant status. *Biochimie* 2010;94:2723–33.
- [24] Minuz P, Fava C, Cominacini L. Oxidative stress, antioxidants, and vascular damage. *Br J Clin Pharmacol* 2006;61:774–7.
- [25] Asquith DL, Miller AM, McInnes IB, Liew FY. Animal models of rheumatoid arthritis. *Eur J Immunol* 2009;39:2040–4.
- [26] Banji D, Pinnapureddy J, Banji OJF, Saidulu A, Hayath MS. Synergistic activity of curcumin with methotrexate in ameliorating Freund's complete adjuvant induced arthritis with reduced hepatotoxicity in experimental animals. *Eur J Pharmacol* 2011;668:293–8.
- [27] Gavrilov VB, Gavrilova AR, Mazhul LM. Methods of determining lipid peroxidation products in the serum using a thiobarbituric acid test. *Vopr Med Khim* 1987;33:118–22.
- [28] Ohkawa H, Ohishi N, Yagi K. Assay for lipid peroxides in animal tissues by thiobarbituric acid reaction. *Anal Biochem* 1979;95:351–8.
- [29] Koroliuk MA, Ivanova LI, Maiorova IG, Tokarev VE. A method of determining catalase activity. *Lab Delo* 1988; 16–9.
- [30] Galaktionova LP, Molchanov AV, El'chaninova SA, Varshavskii Bla. Lipid peroxidation in patients with gastric and duodenal peptic ulcers. *Klin Lab Diagn* 1998;10–4.
- [31] Leonavičienė L, Keturkienė A, Astrauskas V, Vaitkienė D, Bradūnaitė R, Bernotienė E. An improved model of osteoarthritis in rats and its therapy with the tincture of *Filipendula Ulmaria* (L.) Maxim. *Baltic J Lab Anim Sci* 2001;11:225–37.
- [32] Vasiliauskas A, Leonavičienė L, Bradūnaitė R, Vaitkienė D, Lukšienė A. Investigation of *Aesculus hippocastanum* L. tincture on the content of trace elements and pro-/antioxidant status of organism in rats with adjuvant arthritis. *Trace Elem Electroly* 2011;28:199–207.
- [33] Ramadan G, Al-Kahtani MA, El-Sayed WM. Anti-inflammatory and anti-oxidant properties of *Cucurma longa* (Turmeric) versus *Zingiber officinale* (Ginger) Rhizomes in rat adjuvant-induced arthritis. *Inflammation* 2011;34:291–301.
- [34] Taty Anna K, Elvy Suhana MR, Das S, Faizah O, Hamzaini AH. Anti-inflammatory effect of *Cucurma longa* (turmeric) on collagen-induced arthritis: an anatomico-radiological study. *Clin Ter* 2011;162:201–7.
- [35] Sengupta K, Kolla JN, Krishnaraju AV, Yalamanchili N, Rao CV, Golakoti T, et al. Cellular and molecular mechanisms of anti-inflammatory effect of Aflapin: a novel *Boswellia serrata* extract. *Mol Cell Biochem* 2011;354:189–97.
- [36] Vishal AA, Mishra A, Raychaudhuri SP. A double blind, randomized, placebo controlled clinical study evaluates the early efficacy of aflapin in subjects with osteoarthritis of knee. *Int J Med Sci* 2011;8:615–22.
- [37] Warnock M, McBean D, Suter A, Tan J, Whittaker P. Effectiveness and safety of Devil's Claw tablets in patients with general rheumatic disorders. *Phytother Res* 2007;21:1228–33.
- [38] Wachsmuth L, Lindhorst E, Wrubel S, Hadziyski H, Hudelmaier M, Eckstein F, et al. Micro-morphometrical assessment of the effect of *Harpagophytum procumbens* extract on articular cartilage in rabbits with experimental osteoarthritis using magnetic resonance imaging. *Phytother Res* 2011;25:1133–40.
- [39] Brien S, Lewith G, Walker AF, Middleton R, Prescott P, Bundy R. Bromelain as an adjunctive treatment for moderate-to-severe osteoarthritis of the knee: a randomized placebo-controlled pilot study. *Q J Med* 2006;99:841–50.
- [40] Debbi EM, Agar G, Fichman G, Ziv YB, Kardosh R, Halperin N, et al. Efficacy of methylsulfonylmethane supplementation on osteoarthritis of the knee: a randomized controlled study. *BMC Complement Alternat Med* 2011;11:50.
- [41] Ezaki J, Hashimoto M, Hosokawa Y, Ishimi Y. Assessment of safety and efficacy of methylsulfonylmethane on bone and knee joints in osteoarthritis animal model. *J Bone Miner Metab* 2013;31:16–25.
- [42] Ashkavand Z, Malekinejad H, Amniattalab A, Rezaei-Golmisheh A, Vishwanath BS. Silymarin potentiates the anti-inflammatory effects of Celecoxib on chemically induced osteoarthritis in rats. *Phytomedicine* 2012;19: 1200–5.
- [43] Sims JE, Smith DE. The IL-1 family: regulators of immunity. *Nat Rev Immunol* 2010;10:89–102.
- [44] Cai X, Wong YF, Zhou H, Xie Y, Liu ZQ, Jiang ZH, et al. The comparative study of Sprague-Dawley and Lewis rats in adjuvant induced arthritis. *Naunyn-Schmiedeberg's Arch Pharmacol* 2006;373:140–7.
- [45] Suresh P, Kavitha ChN, Babu SM, Reddy VP, Latha AK. Effect of ethanol extract of *Trigonella foenum graecum* (Fenugreek) seeds on Freund's adjuvant-induced arthritis in albino rats. *Inflammation* 2012. <http://dx.doi.org/10.1007/s10753-012-9444-7>
- [46] Nielsen F, Mikkelsen BB, Nielsen JP, Andersen HR, Grandjean P. Plasma malondialdehyde as biomarker of oxidative stress: reference interval and effects of life-style factors. *Clin Chem* 1997;43:1209–14.
- [47] Balbir-Gurman A, Fuhrman B, Braun-Moscovici Y, Markovits D, Aviram M. Consumption of pomegranate decreases serum oxidative stress and reduces disease activity in patients with active rheumatoid arthritis: a pilot study. *IMAJ* 2011;13:474–9.
- [48] Bose A, Ray SD, Sahoo M. Evaluation of analgesic and antioxidant potential of ethanolic extract of *Nymphaea alba* rhizome. *Oxid Antioxid Med Sci* 2012;1:217–23.
- [49] Fedatto Júnior Z, Ishii-Iwamoto EL, Amado CB, Vicentini GE, Panerari AD, Bracht A, et al. Gluconeogenesis in the liver of arthritic rats. *Cell Biochem Funct* 1999;17:271–8.
- [50] Pedernera AM, Guardia T, Calderón CG, Rotelli AE, de la Rocha NE, Genaro SD, et al. Anti-ulcerogenic and anti-inflammatory activity of the methanolic extract of *Larrea divaricata* Cav. in rat. *J Ethnopharmacol* 2006;105:415–20.
- [51] Venkatesha SH, Rajaiah R, Berman BM, Moudgil KD. Immunomodulation of autoimmune arthritis by herbal CAM. *Evid Based Complement Alternat Med* 2011;2011:986797.