

Expression of Cytokeratin 7 as a Histological Marker of Cholestasis and Stages of Primary Biliary Cirrhosis

Aušrinė Barakauskienė¹, Danutė Speičienė², Valentina Liakina²,
Teresė Semuchinienė², Jonas Valantinas²

¹National Center of Pathology, Vilnius University,

²Center of Hepatology, Gastroenterology, and Dietetics, Faculty of Medicine, Vilnius University, Lithuania

Key words: primary biliary cirrhosis; ductular reaction; cytokeratin 7; hepatitic/cholestatic pattern.

Summary. The aim of this study was to estimate cytokeratin 7 (CK-7) expression in biopsy specimens of patients with different stages of primary biliary cirrhosis and clinicopathological patterns (cholestatic and hepatitic) and its correlation with some biochemical and pathological parameters and to examine a diagnostic value of CK-7 expression.

Material and Methods. A total of 82 biopsy specimens of patients with primary biliary cirrhosis were analyzed. CK-7 expression was graded by 4 grades depending on the extent into parenchymal areas and bile duct epithelium. The correlations of CK-7 expression grade with copper deposition, bile duct/portal tract ratio, bilirubin concentration, and activity of alkaline phosphatase and gamma-glutamyl transpeptidase were studied. CK-7 expression was evaluated as a marker of cholestasis (cholestatic pattern) and inflammation (hepatitic pattern).

Results. A positive correlation of CK-7 expression grade with copper-binding protein grade ($r=0.698$, $P<0.0001$; $OR=6.199$, $P<0.0001$), serum bilirubin level ($r=0.375$, $P=0.001$), and alkaline phosphatase activity ($r=0.276$, $P=0.014$) was found. CK-7 expression grades correlated positively with histological stages of primary biliary cirrhosis ($r=0.639$, $P<0.000$) and negatively with granulomas ($r=-0.432$, $P<0.0001$; $OR=0.173$, $P=0.0011$).

Conclusions. CK-7 expression is a sensitive marker of bile duct injury, which correlated well with histological stages of primary biliary cirrhosis, copper deposits, and biochemical markers of cholestasis: serum bilirubin level and alkaline phosphatase activity. Evaluation of CK-7 expression may improve the diagnosis of this serious and progressive disease. It is recommended to evaluate copper staining together with cytokeratin 7 expression in liver biopsy specimens for more precise diagnostic evaluation of asymptomatic primary biliary cirrhosis.

Introduction

The term “ductular reaction” introduced by Popper in 1957 refers to an increased number of periportal ductular structures consisting of either proliferation of preexisting ductules or activation of progenitor cells and intermediate hepatocytes (1–5). Bile ductular reactions occur in a variety of human liver diseases (6–17). “Reaction” encompasses the complex of stromal changes, inflammatory cells, and other structures of diverse systems, which participate in the reactive lesion (4, 6). In case of incomplete extrahepatic obstruction and vanishing bile duct diseases, the histological appearance is complicated by both hepatocellular and cholangiocytic damage that is well known in human disease and nonhuman primate models (18, 19).

Although florid bile duct lesions and bile duct loss are known as important diagnostic features of primary biliary cirrhosis, their diagnostic usefulness is still controversial (12). Bile duct injury re-

sembling that observed in primary biliary cirrhosis (PBC) to variable degree can be encountered in other diseases (15). For this reason, special staining techniques that highlight specific antigens and structures are very useful for better visualization of ductular reaction (11, 14, 16, 17, 20–23).

Cholestatic and inflammatory patterns of lesions are the main tissue alterations underlying the clinical features and histopathological markers of PBC and determining direction and different mechanisms of disease progression.

The progression of liver damage in PBC is caused not only by cholestasis but also by portal and periportal inflammation and fibrosis. These two types of lesions may be responsible for two types or two modes of PBC, which variably overlap even in the same biopsy (12).

The recent literature presented data on cytokeratin 7 (CK-7) mostly as a marker of bile duct damage and cholestasis, but there is a lack of studies

Correspondence to V. Liakina, Center of Hepatology, Gastroenterology and Dietetics, Santariškių 2, 08661 Vilnius, Lithuania
E-mail: valentina.liakina@santa.lt

Adresas susirašinėti: V. Liakina, VU Hepatologijos, gastroenterologijos ir dietologijos centras, Santariškių 2, 08661 Vilnius
El. paštas: valentina.liakina@santa.lt

on associations between CK-7 expression and morphological inflammatory parameters (hepatitic pattern) as well as biochemical indices of liver damage. Therefore, it is reasonable to evaluate CK-7 expression as a marker of PBC hepatitic pattern more precisely. Cholestatic changes (cholestatic pattern) comprise bilirubinostasis, cholate stasis, cholestatic liver cell rosettes, feathery degeneration, accumulation of foamy lipid-laden macrophages, ductular reaction, and periductular and septal fibrosis. With the exception of bilirubinostasis, all these alterations develop progressively. However, in chronic cholestatic diseases characterized by progressive destruction of segments of the intrahepatic bile ducts, of which PBC is a paramount example, these morphological alterations are not always seen simultaneously. Cholate stasis in PBC has been demonstrated by the deposition of copper or copper-binding protein in hepatocytes (1). The aberrant expression of bile duct-type cytokeratins (CK-7 and CK-19) in parenchymal cells has been demonstrated in various chronic cholestatic diseases, but CK-7 expression has been shown to be a more sensitive indicator than that of CK-19 (23). The discrepancy in CK-7 expression between cholestatic and inflammatory patterns suggests that cholestasis and inflammatory activity in the portal tract are independent events (16, 17).

Several scoring systems for histological staging of the disease in PBC patients have been reported (24–26). Staging is important in assessing disease progression and therapeutic efficacy, in spite of frequent discrepancy between histological staging and clinical and biochemical data (7). Evaluation of CK-7 expression extent may provide additional information for precise histological staging of primary biliary cirrhosis and could be used as a routine staining method (16, 17).

The aim of this study was to evaluate CK-7 expression in bile duct reaction and cytoplasm of hepatocytes in biopsy specimens of PBC patients and to determine whether CK-7 expression could be related to some well-known PBC morphological lesions, such as epithelioid granuloma formation, changes in portal tract/bile duct ratio and grade of copper-binding protein expression in periportal hepatocytes. To evaluate a diagnostic value of CK-7 expression grade, we also estimated the correlation of CK-7 expression with some biochemical indices and histological stages of PBC.

Material and Methods

Eighty-two patients (5 males and 77 females; mean age, 58.4 ± 10.7 years) with primary biliary cirrhosis confirmed by clinical data and standard biochemical and immunological tests and without signs of PBC-autoimmune hepatitis (AIH) overlap or/and viral or metabolic hepatitis were studied. All

the patients were tested for anti-HCV by a micro-particle enzyme immunoassay (AxSYM hepatitis C virus version 3.0; ABBOTT, 65205 Wiesbaden, Germany) for HBsAg (AxSYM hepatitis B Ag [V2], ABBOTT) and underwent ultrasound examination by LOGIQ 500 PRO series (General Electric Company, 3135 Fairfield CT, USA).

The serum activity of alkaline phosphatase (ALP), gamma-glutamyl transpeptidase (γ -GTP), and alanine and aspartate aminotransferases (ALT, AST), and bilirubin (Bi) concentration were measured as well as testing for autoantibodies was performed in all patients. Antimitochondrial (AMA) and antinuclear (ANA) autoantibodies were detected by indirect immunofluorescence on murine tissue sections and Hep-2 slides (IFA kits, The Binding Site LTD, Birmingham B29 6AT, England) with confirmation for AMA by the Western blot assay (EUROASSAY AMA Profile [M2, M4, M9], EUROIMMUN AG, D-23560 Luebeck, Germany).

Liver Histology. Ultrasound-guided liver biopsy (Hepafix needle, gauge 12–16) was performed in all the patients. Biopsy specimens were fixed in 10% buffered formalin and embedded in paraffin. Three-micron thick sections were cut, deparaffinized, and stained with hematoxylin-eosin (H&E), picosirius red for collagen (27), Gordon-Sweet and picosirius (GS/PS) for reticulin and periodic acid Schiff (PAS) for glycogen (28).

Necroinflammatory activity was evaluated according to the histological activity index (HAI) by Ishak et al. (1995) (29), and histological staging of PBC was estimated by the Ludwig's scoring system (22). CK-7 expression in proliferated bile ducts was examined by immunohistochemical staining with monoclonal mouse anti-human CK-7 (clone OV-TL12/30; DAKO, DK-2600 Glostrup Denmark) and graded semiquantitatively according to Yabushita et al. as follows (16): grade 1, CK-7 positivity in bile ducts and ductular reaction only (Fig. 1); grade 2, CK-7 expression in the cytoplasm of periportal hepatocytes in addition to bile ductular reaction (Fig. 2); grade 3, CK-7 expression in the cytoplasm of not only periportal but intralobular hepatocytes as well in addition to bile ductular reaction (Fig. 3); and grade 4; diffuse CK-7-positive staining in the cytoplasm of the majority of hepatocytes in addition to bile duct and ductular epithelium (Fig. 4).

Rhodanine staining was used for visualization of copper-associated protein in hepatocytes. Copper (Cu) deposition was graded as follows: grade 0, no deposits; grade I, Cu deposition only in the cytoplasm of some periportal hepatocytes; grade II, Cu deposition in most periportal hepatocytes; and grade III, Cu deposition in deeper intralobular hepatocytes in addition to periportal hepatocytes (30, 31).

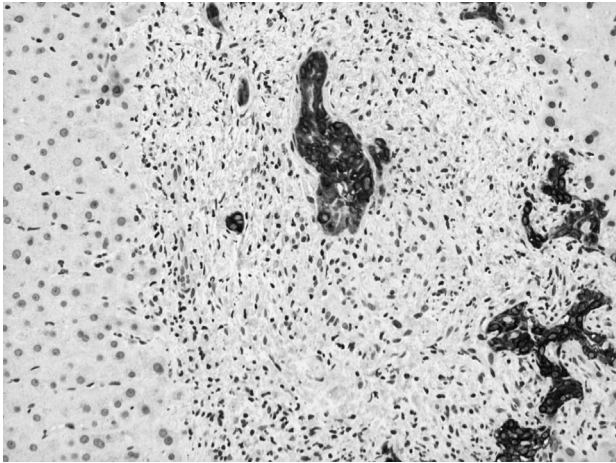


Fig. 1. Grade 1, CK-7 expresses positive bile ductular reaction (positivity only in epithelium of the bile ductules and damaged bile duct in the center. H&E; magnification, $\times 200$)

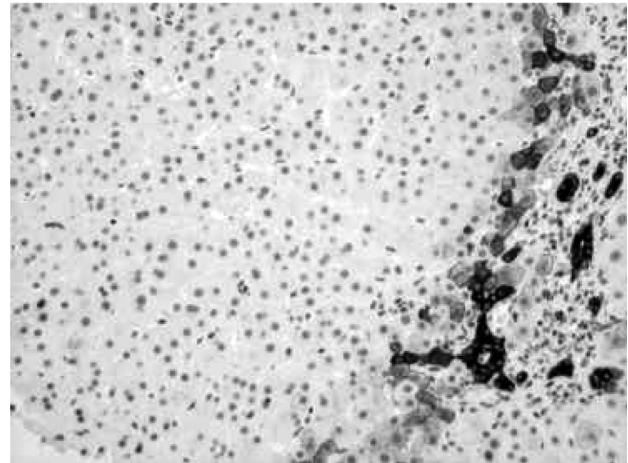


Fig. 2. Grade 2, CK-7 expression in the cytoplasm of periportal hepatocytes in addition to bile ductular reaction (H&E; magnification, $\times 200$)

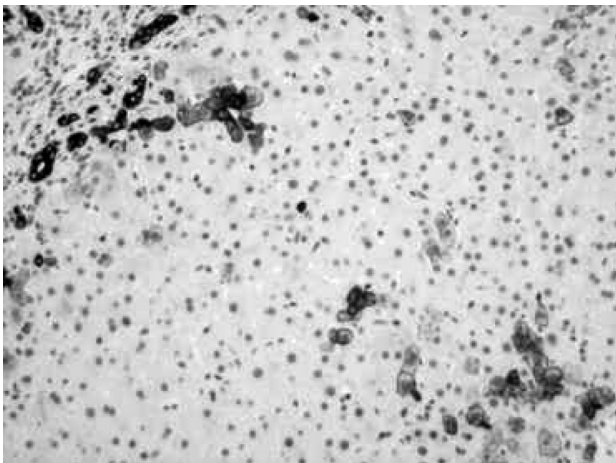


Fig. 3. Grade 3, CK-7 expression in the cytoplasm of periportal and intralobular hepatocytes in addition to bile ductular reaction (H&E; magnification, $\times 200$)

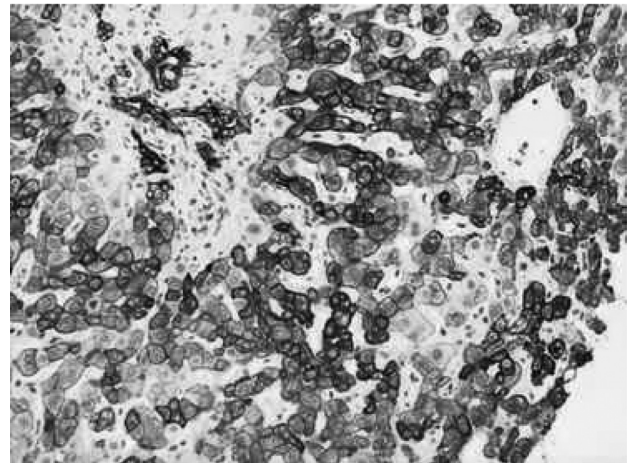


Fig. 4. Grade 4, CK-7 diffusely stained in the cytoplasm of majority of hepatocytes and in bile duct epithelium (H&E; magnification, $\times 200$)

The number of recognizable bile ducts per portal tract was expressed as bile duct/portal tract ratio. The presence of epithelioid granulomas around the damaged bile ducts was recognized as groups of epithelioid cells near damaged bile ducts characterized by epithelial atrophy, vacuolization, with increased number of intraepithelial lymphocytes inside the altered basement membrane.

Statistical Analysis. The comparison of serum bilirubin concentration and activity of ALP, γ -GTP, ALT, and AST in four groups of patients with different grades of CK-7 expression was made by the ANOVA test. Differences in the presence of epithelioid granulomas in biopsies of above-mentioned groups of patients were evaluated by the chi-square test. The Fisher exact test was employed for the evaluation of differences in copper-binding protein deposits and Ludwig's PBC stages in groups of patients with various grades of CK-7 expression.

Pearson's correlation coefficient was calculated for estimation of correlation between continuous variables; for ordinal data, Spearman's correlation coefficient was calculated. The estimation of the odds ratio with 95% confidence interval for Ludwig's PBC stages, serum bilirubin level, activity of ALP, γ -GTP, ALT, and AST, grades of copper-binding protein deposits, and presence of granulomas adjusted for CK-7 expression grades was made via multivariate logistic regression analysis. A P value of ≤ 0.05 was considered statistically significant.

Statistical analysis was carried out with SPSS (SPSS Inc., Chicago, Illinois 60606, USA) and SAS software (SAS Institute Inc., Cary, NC 27513 USA).

Results

According to the Ludwig's staging system, 82 PBC patients were classified as follows: 11 cases had stage I PBC, 25 cases stage II PBC, 34 cases stage III

Table 1. Characteristics of Patients With Primary Biliary Cirrhosis

Characteristic	Total	Ludwig's Primary Biliary Cirrhosis Stages			
		I	II	III	IV
Male-to-female ratio	5:77	0:11	0:25	2:32	3:9
Age, mean (SD), years	58.4 (10.7)	59.3 (13.8)	58.7 (10.0)	58.7 (10.1)	57.8 (13.5)
ALT, mean (SD) IU/mL	119.0 (106.5)	111.2 (91.1)	113.0 (80.7)	126.0 (117.6)	79.3 (37.8)
AST, mean (SD), IU/mL	98.6 (67.2)	105.3 (82.3)	95.6 (51.4)	104.2 (82.8)	86.1 (32.0)
ALP, mean (SD), IU/mL	526.6 (390.7)	311.9 (230.1)	552.4 (451.6)	542.5 (321.9)	594.1 (545.0)
γ -GTP, mean (SD), IU/mL	439.4 (341.7)	274.3 (226.6)	461.2 (407.3)	339.6 (320.8)	607.9 (291.6)
Bilirubin, mean (SD), μ mol/L	34.9 (34.2)	14.8 (12.5)	25.2 (19.3)	41.0 (42.9)	54.9 (32.4)
AMA-positive, n (%)	78 (95.1)	8 (72.7)	25 (100.0)	34 (100.0)	11 (91.7)
ANA-positive, n (%)	40 (48.8)	5 (45.5)	12 (56.0)	17 (50.0)	6 (50.0)

ALT, alanine aminotransferase; AST, aspartate aminotransferase; ALP, alkaline phosphatase; γ -GTP, gamma-glutamyl transpeptidase; AMA, antimitochondrial autoantibody; ANA, antinuclear autoantibody.

PBC, and 12 cases stage IV PBC (Table 1).

CK-7 was expressed in epithelial cells of interlobular bile ducts in all PBC biopsy specimens, whereas expression in cholangiocytes of ductules (in areas of ductular reaction) and cytoplasm of hepatocytes varied significantly. The grade of CK-7 staining and grades of copper-binding protein deposits showed a strong positive correlation (Spearman's correlation coefficient $r=0.698$, $P<0.0001$). This clear tendency of the presence of more numerous copper-binding protein deposits in the biopsies of patients with higher CK-7 grade (Fig. 5) was confirmed by multivariate logistic regression analysis (Table 2).

On the contrary, CK-7 expression and presence of epithelioid granulomas (Fig. 6) showed a negative correlation (Spearman's correlation coefficient, $r=-0.432$; $P<0.0001$). The higher CK-7 expression in a biopsy specimen was documented, the less frequently granulomas were observed (Fig. 7).

No correlation was found between CK-7 grading and bile duct/portal tract ratio.

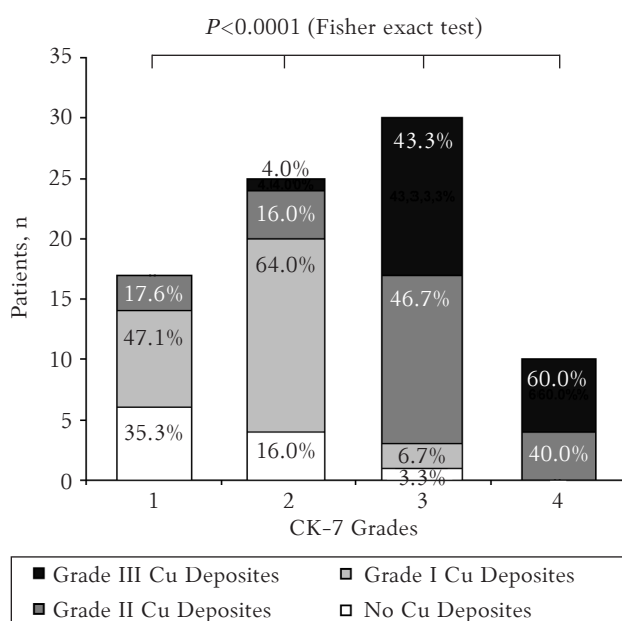


Fig. 5. Relationship between cytokeratin 7 (CK-7) expression and grades of copper-binding protein in hepatocytes

Table 2. Association of Cytokeratin 7 Expression Grade and Histological Findings (Data of Multivariate Logistic Regression Analysis)

Variable	OR	95% confidence interval	P value
Granulomas	0.173	0.101–0.306	0.0011
Copper-binding protein	6.199	3.412–12.001	<0.0001

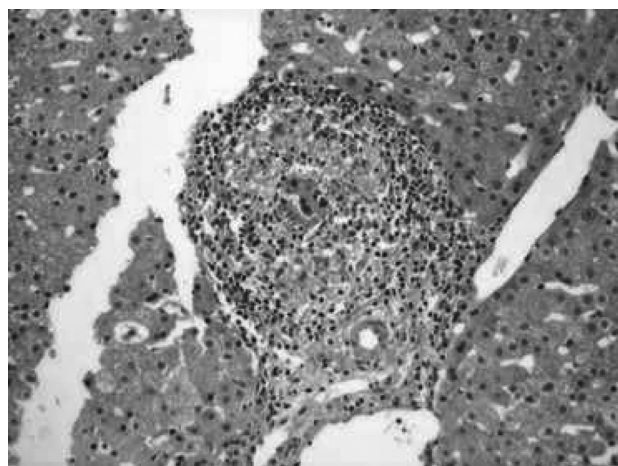


Fig. 6. Formation of epithelioid granuloma around damaged bile duct in the center of portal tract (H&E; magnification, $\times 400$)

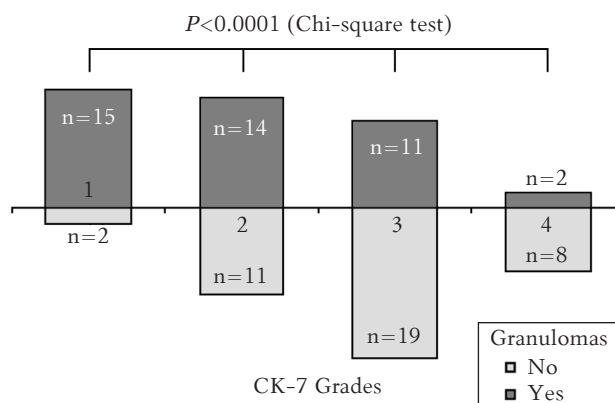


Fig. 7. Relationship between cytokeratin 7 (CK-7) expression and formation of epithelioid granulomas around damaged bile ducts

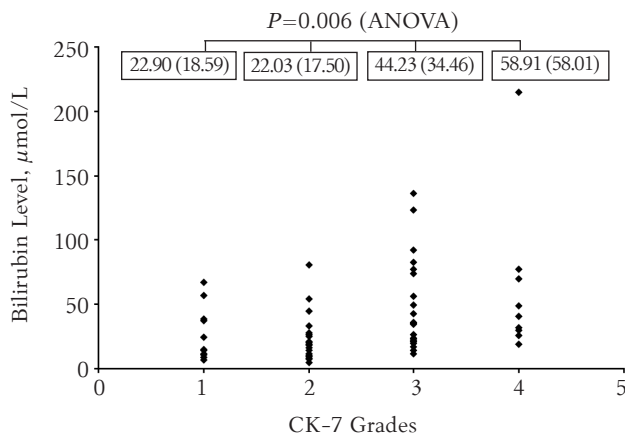


Fig. 8. Relationship between cytokeratin 7 (CK-7) expression and serum bilirubin level
Values are given as mean (SD).

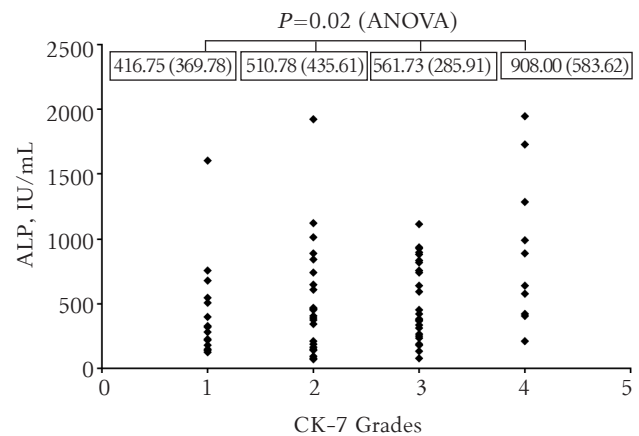


Fig. 9. Relationship between cytokeratin 7 (CK-7) expression and activity of serum alkaline phosphatase (ALP)
Values are given as mean (SD).

The serum activity of ALT, AST, and γ -GT did not differ significantly among four groups of patients with different grades of CK-7 expression. Only serum bilirubin level and ALP activity showed a weak positive correlation with CK-7 expression grades (Pearson's correlation coefficient, $r=0.375$, $P=0.001$; and $r=0.276$, $P=0.014$, respectively) (Figs. 8 and 9).

Meanwhile, the CK-7 expression grades showed a strong positive correlation with PBC histological stages (Spearman's correlation coefficient, $r=0.639$; $P<0.0001$) (Fig. 10). The certain discrepancy was observed in the specimens with grades 1 and 2 CK-7 expression where all 4 Ludwig's stages were presented (Fig. 10). Grade 3 and 4 CK-7 expression was mostly seen in the specimens of patients with stage III (70% and 60%, respectively) and stage IV (20% and 40%, respectively) PBC.

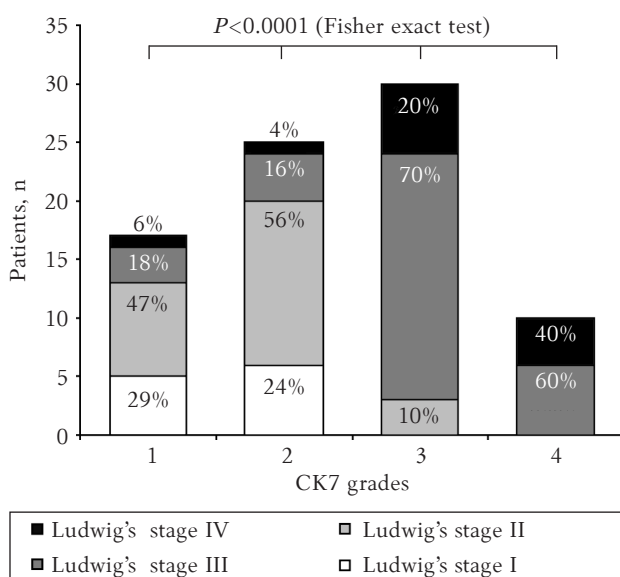


Fig. 10. Relationship between cytokeratin 7 (CK-7) expression and histological stages of primary biliary cirrhosis by Ludwig's classification

Discussion

Primary biliary cirrhosis histopathologically is characterized by chronic nonsuppurative destructive cholangitis leading to cholestasis and ductopenia of interlobular bile ducts. Nevertheless, sometimes it is difficult to prove bile duct injury and differentiate this serious progressive disease from bile duct damage because of chronic viral hepatitis, drug-induced and autoimmune hepatitis (7, 9).

Staging and classification of PBC is still controversial (13, 17). This may be due to the striking variability in clinical and histopathological features of the disease, reflecting the overlapping and discontinuous nature of the pathological processes.

We examined and compared the extent of immunohistochemically demonstrated CK-7 expression in bile duct cells and hepatocytes in PBC patients with different clinicopathological patterns (cholestatic and hepatitic) of this disease to prove the value of CK-7 immunostaining in the histopathological diagnosis and staging of PBC.

Different grade of CK-7 expression depended on histopathological pattern of liver injury, i.e., predominance of cholestatic or hepatitic patterns usually found but expressed differently in biopsy specimens of PBC patients. The relationship between CK-7 expression and copper-binding protein in hepatocytes, cholestatic biochemical data (bilirubin and ALP activity), and bile duct/portal tract ratio points to the cholestatic clinicomorphological pattern of injury (8, 11). Our results obtained show that the most valuable marker of a cholestatic pattern could be the relationship between CK-7 expression and presence of copper-binding protein in the hepatocytes.

The grade of CK-7 expression and grade of copper-binding protein deposits showed a strong positive correlation. This clear tendency toward the presence of more numerous copper-binding protein

deposits in biopsies of patients with higher CK-7 grade (Fig. 5) was confirmed by multivariate logistic regression analysis (Table 2). A higher level of Cu deposition was found in the specimens with grade 3 and 4 CK-7 expression suggesting that CK-7 expression was a more sensitive marker of chronic cholestatic condition than the deposition of copper-binding protein, because it was weakly expressed in the specimens with grade 1 and 2 CK-7 expression. A strong positive correlation between CK-7 grading and copper-binding protein suggests Cu deposition to be an independent morphological marker of cholestasis.

Nevertheless, CK-7 expression can be considered a more sensitive marker of cholestasis as emphasized by other authors (16). According to our data, serum bilirubin level and ALP but not γ -GT activity showed a weak positive correlation with the grades of CK-7 expression and proved CK-7 expression to be a marker of cholestatic pattern too, although a discrepancy between biochemical data and histological findings exists that was confirmed by other authors (7).

The precise assessment of PBC histological stage is important for the evaluation of prognosis often used in survival models as well as in the evaluation of treatment efficacy in therapeutic trials on PBC (26). Scheuer's classification includes chronic non-suppurative destructive cholangitis as a characteristic histological feature of PBC and has been widely used for staging PBC (25).

Data that a part of patients with even advanced Ludwig's (III and IV) stages present with grade 1 and 2 CK-7 expression (Fig. 10) may suggest that cholestatic and inflammatory patterns are independent events (1, 7, 19). Other reason for finding low CK-7 expression (grade 1 and grade 2) in Ludwig's stages II, III, and even IV could be due to topographic heterogeneity of the lesions causing considerable overlap between different PBC stages in the same biopsy as also noted by others (11). Nevertheless, in comparison between the CK-7 grading and histological staging, we consider that cholestasis progresses in more advanced stages of Ludwig's classification and that it is less expressed in Ludwig's stages I and II where inflammatory activity and bile duct lesions dominate over fibrosis and cholestasis. The fact that there is a positive correlation between the CK-7 grading and histological staging does not support the concept that histological staging is an independent marker of cholestasis as suggested by multivariate logistic regression analysis in the comparison with copper-binding protein expression. This could be due to the essence of the Ludwig's classification, which is based only on parameters of

inflammation and fibrosis, analogous to the grading and staging of chronic viral hepatitis, and does not include the cholestatic pattern, which nevertheless is one of the main histological criteria of PBC.

The finding that epithelioid granulomas were observed in specimens with all grades of CK-7 expression emphasizes the heterogeneity and discontinuity of the cholestatic and inflammatory patterns in PBC, even in the same liver biopsy, whereby early bile duct lesions can be seen in the livers of patients with advanced-stage disease (25). However, the finding of fewer granulomas in more advanced stages indicates that cholestatic lesions predominate in more advanced stages of PBC – similar to what was shown comparing CK-7 grading and histological Ludwig's stages – the more expressed fibrosis, the more severe cholestasis but fewer granulomas (the main pathological PBC features).

As inflammation and cholestasis are of importance in the progression of PBC (11, 15, 16), their characteristic morphological patterns deserve to be included in histological staging especially when dealing with liver biopsies for the evaluation of therapeutic efficacy.

For more precise and adequate evaluation of PBC histological stages, it is advisable to assess CK-7 expression and its grades that could be used as a diagnostic and prognostic marker in the management and follow-up of patients with PBC.

Conclusions

Our data confirm the expression of cytokeratin 7 as a sensitive marker of bile duct injury and cholestasis in patients with primary biliary cirrhosis that correlated well with the stages of primary biliary cirrhosis and biochemical parameters of cholestasis – bilirubin concentration and alkaline phosphatase activity. The results support the inclusion of 4-grade cytokeratin 7 expression staging for more accurate biopsy-based staging of primary biliary cirrhosis and improvement of diagnosis and prognosis of patients with primary biliary cirrhosis. It is recommended to evaluate copper staining together with cytokeratin 7 expression in liver biopsy specimens as these both markers have been shown to have diagnostic and prognostic value while examining patients with primary biliary cirrhosis.

Acknowledgments

We express our thanks to Valeer J. Desmet from the Laboratory of Morphology and Molecular Pathology, University Hospital Leuven, Belgium, for the critical evaluation of the manuscript and valuable suggestions for the improvement of data presentation.

Citokeratino-7 raiška – cholestazės ir pirminės bilijinės cirozės stadijų histologinis žymuo

Aušrinė Barakauskienė¹, Danutė Speičienė², Valentina Liakina²,
Teresė Semuchinienė², Jonas Valantinas²

¹Vilniaus universiteto Valstybinis patologijos centras,

²Vilniaus universiteto Hepatologijos, gastroenterologijos ir dietologijos centras

Raktažodžiai: pirminė bilijinė cirozė, duktulių reakcija, citokeratinas-7, hepatinė/cholestazinė raiška.

Santrauka. *Tyrimo tikslas.* Nustatyti citokeratino-7 (CK-7) raiškos laipsnio koreliaciją su kai kuriais pirminės bilijinės cirozės (PBC) klinikiniais rodikliais, histologiniais kepenų pažeidimo požymiais bei įvertinti diagnostinę šios imunohistocheminės reakcijos svarbą.

Tirtųjų kontingentas ir tyrimo metodai. Ištirti 82 sergančiųjų PBC kepenų biopsatai. Atlikus imunohistocheminę reakciją, CK-7 raiškos laipsnis įvertintas pagal jo išplitimą ir pasiskirstymą hepatocituose bei tulžies latakų epitelyje.

CK-7 raiškos laipsnio koreliacija su tulžies latakų/portinių laukų santykiu, baltymu surišto vario raiškos laipsniu biopsatuose bei šarminės fosfatazės ir gama glutamiltranspeptidazės aktyvumo pokyčiais kraujo serume vertinama kaip cholestazės požymis. CK-7 raiškos laipsnio koreliacija su histologinėmis PBC ligos stadijomis, esant epitelioidinėms granuliomoms, yra uždegiminiam (hepatitiniam) sindromui būdingas požymis.

Rezultatai. Nustatytas patikimas koreliacinis ryšys tarp CK-7 raiškos laipsnio ir šių rodiklių: vario, surišto su baltymu, raiškos laipsniu ($r=0,698$, $p<0,0001$; $\bar{S}S=6,199$, $p<0,0001$), serumo bilirubino koncentracijos ($r=0,375$, $p=0,001$) ir šarminės fosfatazės aktyvumu ($r=0,276$, $p=0,014$), tačiau patikimos koreliacijos su tulžies latakų/portinių laukų santykiu nerasta. Nustatyta teigiama koreliacija tarp CK-7 raiškos laipsnio ir pirminės bilijinės cirozės histologinių stadijų ($r=0,639$, $p<0,0001$; $\bar{S}S=4,923$, $p<0,0001$) bei neigiama koreliacija esant granuliomų biopsatuose ($r=-0,432$, $p<0,0001$; $\bar{S}S=0,173$, $p=0,0011$).

Išvados. CK-7 raiškos laipsnis biopsate yra jautrus tulžies latakų pažeidimo ir cholestazės žymuo, kuris tiesiogiai koreliuoja su PBC histologinėmis stadijomis. Nesant PBC simptomų, kepenų biopsatuose rekomenduojama atlikti vario depozicijos identifikavimą ir CK-7 imunohistocheminę reakciją, nes ši reakcija yra informatyvi nustatant cholestazę.

References

1. Portmann B, Popper H, Neuberger J, Williams R. Sequential and diagnostic features in primary biliary cirrhosis based on serial histologic study in 209 patients. *Gastroenterology* 1985;88:1777-90.
2. Roskams T, Desmet V. Ductular reaction and its diagnostic significance. *Semin Diagn Pathol* 1998;15:259-69.
3. Desmet V, Roskams T, De Vos R. Normal anatomy. In: La Russo N, editor. Gallbladder and bile ducts. Philadelphia: Current Medicine; 1997. p. 1-29.
4. Roskams T, Theise N, Balabaud CH, Bhagat G, Bhathal P, Bioulac-Sage P, et al. Nomenclature of the finer branches of the biliary tree: canals, ductules, and ductular reactions in human livers. *Hepatology* 2004;39:1739-45.
5. Vertemati M, Minola E, Goffredi M, Sabatella G, Gambacorta M, Vizzotto L. Computerized morphometry of the cirrhotic liver: comparative analysis in primary biliary cirrhosis, alcoholic cirrhosis, and posthepatic cirrhosis. *Microsc Res Tech* 2004;65:113-21.
6. Jung Y, McCall SJ, Li YX, Diehl AM. Bile ductules and stromal cells express hedgehog ligands and/or hedgehog target genes in primary biliary cirrhosis. *Hepatology* 2007;45(5):1091-6.
7. Williamson J, Chalmers DC, Clayden A, Dixon J, Ruddell W, Losowsky T. Primary biliary cirrhosis and chronic active hepatitis: an examination of clinical, biochemical, and histopathological features in differential diagnosis. *J Clin Pathol* 1985;38:1007-12.
8. Rubio CA. Qualitative and quantitative differences between bile ducts in chronic hepatitis and in primary biliary cirrhosis. *J Clin Pathol* 2000;53:765-9.
9. Cabibi D, Licata A, Barresi E, Craxi A, Aragona F. Expression of cytokeratin 7 and 20 in pathological conditions of the bile tract. *Pathol Res Pract* 2003;199:65-70.
10. Zen Y, Harada K, Sasaki M, Tsuneyama K, Matsui K, Hara-take J, et al. Are bile duct lesions of primary biliary cirrhosis distinguishable from those of autoimmune hepatitis and chronic viral hepatitis? Interobserver histological agreement on trimmed bile ducts. *J Gastroenterol* 2005;40:164-70.
11. Nacamura Y, Saito K, Unoura M. Semiquantitative assessment of cholestasis and lymphocytic piecemeal necrosis in primary biliary cirrhosis: a histological and immunohistochemical study. *J Clin Gastroenterol* 1990;12:357-62.
12. Nakanuma Y, Miyamura H, Ohta G, Kobayashi K, Kato Y, Hattori N. Correlation between disappearance of the intrahepatic bile ducts and histologic changes in the liver in primary biliary cirrhosis. *Am J Gastroenterol* 1981;76:506-10.
13. Goldstein NS, Soman A, Gordon SC. Portal tract eosinophils and hepatocyte cytokeratin 7 immunoreactivity helps distinguish early-stage, mildly active primary biliary cirrhosis and autoimmune hepatitis. *Am J Clin Pathol* 2001;116:846-53.
14. Isse K, Harada K, Sato Y, Nakanuma Y. Characterization of biliary intra-epithelial lymphocytes at different anatomical levels of intrahepatic bile ducts under normal and pathological conditions: numbers of CD4+CD28- intra-epithelial lymphocytes are increased in primary biliary cirrhosis. *Pathol Int* 2006;56:17-24.

15. Nakanuma Y, Ohta G, Takeshita H, Yamazaki Y, Doishita K, Shimizu M. Florid duct lesions and extensive bile duct loss of the intrahepatic biliary tree in chronic liver diseases other than primary biliary cirrhosis. *Acta Pathol Jpn* 1983;33:1095-104.
16. Yabushita K, Yamamoto K, Ibuki N, Okano N, Matsumura S, Okamoto R, et al. Aberrant expression of cytokeratin 7 as a histological marker of progression in primary biliary cirrhosis. *Liver* 2001;21:50-5.
17. Chatzipantelis P, Lazaris AC, Kafiri G, Papadimitriou K, Papathomas TG, Nonni A, et al. Cytokeratin-7, cytokeratin-19, and c-Kit: immunoreaction during the evolution stages of primary biliary cirrhosis. *Hepatol Res* 2006;36:82-7.
18. Gaglio PJ, Liu H, Dash S, Cheng S, Dunne B, Ratterree M et al. Liver regeneration investigated in a non-human primate model (*Macaca mulatta*). *J Hepatol* 2002;37:625-32.
19. Saxena R, Theise ND, Crawford JM. Microanatomy of the human liver exploring the hidden interfaces. *Hepatology* 1999;30:1339-46.
20. Moritoki Y, Ueno Y, Kanno N, Yamagiwa Y, Fukushima K, Gershwin ME, et al. Amniotic epithelial cell-derived cholangiocytes in experimental cholestatic ductal hyperplasia. *Hepatol Res* 2007;37:286-94.
21. Saxena R, Theise ND. Canals of Hering: recent insights and current knowledge. *Semin Liver Dis* 2004;24:43-8.
22. Crosby H, Hubscher S, Fabris L, Joplin R, Sell S, Kelly D, et al. Immunolocalization of putative human liver progenitor cells in livers from patients with end-stage primary biliary cirrhosis and sclerosing cholangitis using the monoclonal antibody OV-6. *Am J Pathol* 1998;152:771-9.
23. Van Eyken P, Sciote R, Desmet VJ. A cytokeratin immunohistochemical study of cholestatic liver disease: evidence that hepatocytes can express 'bile duct-type' cytokeratins. *Histopathology* 1989;15:125-35.
24. Portmann BC, MacSween RNM. Diseases of the intrahepatic bile ducts. Pathology of the liver. Edinburgh: Churchill Livingstone; 1994. p. 477-512.
25. Scheuer PJ. Primary biliary cirrhosis. In: Liver biopsy interpretation. 5th ed. London: Saunders; 1994. p. 38-61.
26. Ludwig JD, Dickson ER, McDonald GS. Staging of chronic nonsuppurative destructive cholangitis (syndrome of primary biliary cirrhosis). *Virchow Arch A Pathol Anat Histopathol* 1978;379:103-12.
27. Junqueira LCU, Cossermelli W, Brentani L. Differential staining of collagens type I, II and III by Sirius Red and polarization microscopy. *Arch Histol Jap* 1978;41:267-74.
28. Bancroft JD, Stevens A. Theory and practice of histological techniques. New York: Churchill Livingstone; 1982.
29. Ishak K, Baptista A, Bianchi L, Callea F, De Groote J, Gudat F, et al. Histological grading and staging of chronic hepatitis. *J Hepatol* 1995;22:296-9.
30. Shikata T, Uzawa T, Yoshiwara N, Akatsuka T, Yamazaki S. Staining methods of Australia antigen in paraffin sections: detection of cytoplasmic inclusion bodies. *Jpn J Exp Med* 1974;44:25-36.
31. Linquist R. Studies of the pathogenesis of hepatolenticular degeneration. II. Cytochemical methods for the localization of copper. *Arch Pathol* 1969;87:370-9.

Received 28 November 2009, accepted 6 January 2011
Straipsnis gautas 2009 11 28, priimtas 2011 01 06